

# The Importance of Determining a Proper Imaging Modality in Medial Orbital Wall and Blowout Fracture

Yunia Irawati<sup>1</sup>, Carennia Paramita<sup>2</sup>, Dian Farikha<sup>3</sup>

<sup>1</sup>Plastic and Reconstructive Surgery Division, Dr. Cipto Mangunkusumo Hospital, Jakarta, Indonesia.

<sup>2,3</sup>Department of Ophthalmology, Dr. Cipto Mangunkusumo Hospital, Jakarta, Indonesia

## ABSTRACT

A 27-year-old man was first seen 4 weeks after his right eye being accidentally hit by branches of tree. He complained of diplopia which was significant on the right gaze. There were partial thickness superior and inferior eyelid rupture and full thickness superior eyelid margin laceration (which got repaired), hematoma, and swelling of the right eye. Orbital x-ray demonstrated no abnormality. However, orbital CT Scan was eventually obtained and it showed medial wall and orbital floor fracture of the right eye, hence, we planned to do the reconstruction of orbital fracture. We concluded that patient with severe soft tissue swelling, unclear ocular movement restriction and diplopia with normal orbital X-ray should undergo orbital CT scan, as it is the best radiologic imaging in establishing an orbital wall fracture. This author communication will discuss the importance on determining a proper imaging modality in blowout fracture.

**Key Words:** Blowout fracture, X-ray orbit, orbital CT scan, Diplopia.

**How to Cite this Article:** Irawati Y, Paramita C, Farikha D. The Importance of Determining a Proper Imaging Modality in Medial Orbital Wall and Blowout Fracture. Pak J Ophthalmol. 2020;**36** (1): 87-91

**DOI:** <https://doi.org/10.36351/pjo.v36i1.983>.

---

## INTRODUCTION

Orbital trauma can damage facial bones and adjacent soft tissue<sup>1</sup>. The most common site for blowout fracture is the postero-medial aspect of the orbital floor medial to the infraorbital neurovascular bundle where the maxillary bone is very thin<sup>2</sup>.

Blowout fracture occurs when a major blow occurs across the anterior orbital entrance, the fracture results from hydraulic collapse of the orbital floor. Fracture results from transmission of energy from a transient deformation of the inferior orbital rim.

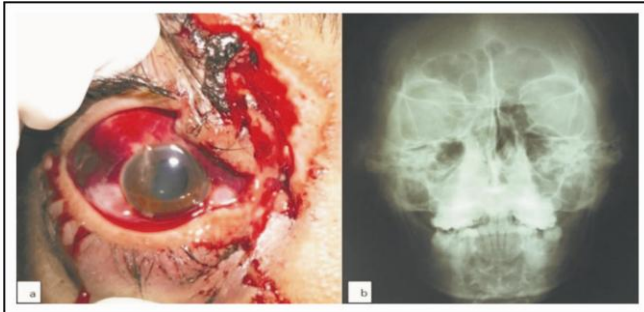
From Chi study about surgically treated orbital fractures, 74.9% of the patients were male. The incidence reached its peak in the 20 to 29 years age<sup>3</sup>. Medial wall fractures were the most common (38.6%), followed by inferior wall (35.7%), medial and inferior walls (21%) and other walls (4.6%).

## CASE PRESENTATION

A 27-year-old man came with complaint of double vision which was significant on right gaze after a 4-month history of accidentally hit by a branch of tree. Ophthalmic examination revealed that his visual acuity of the right eye was 6/7.5 and his right eyelid rupture had been repaired, whereas visual acuity of the left eye was 6/6. There were no abnormalities found on anterior and posterior segment in either eye. Orbital x-ray showed no fracture nor intraocular foreign body (**Fig. 1.**)

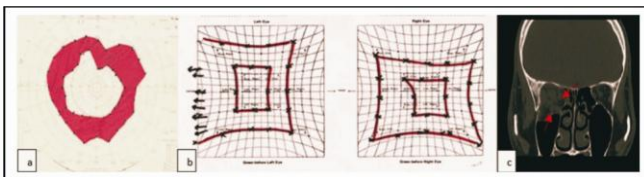
---

Correspondence to: Yunia Irawati  
Head of Plastic and Reconstructive Surgery Division,  
Department of Ophthalmology, Faculty of Medicine  
Universitas, Indonesia, Dr. Cipto Mangunkusumo Hospital,  
JEC Eye Hospitals, Jakarta, Indonesia



**Fig. 1:** Preoperative condition a. Partial thickness superior and inferior eyelid rupture and full thickness superior eyelid margin laceration b. Orbital X-ray.

The diplopia chart showed double vision on right gaze and lower right gaze. There were restriction of right eye movement on upper gaze, upper right gaze and right gaze and down gaze. The Goldmann diplopia perimetry and Hess screen test were performed. Hertel exophthalmometry test with base 108 showed 15 mm in right eye and 18 mm in left eye. Orbital CT scan showed right medial orbital wall fracture, edema of the right medial rectus muscle and edema of orbital fat (**Fig. 2**). He was diagnosed with medial wall and orbital floor fracture of the right eye. Reconstruction of the orbital wall fracture was then scheduled. Unfortunately, the surgery was postponed until 3 months after trauma due to financial problem.




**Fig. 2:** Preoperative examination a. Goldmann diplopia perimetry b. Hess screen c. Orbital CT Scan.

The surgery was performed through medial incision and subciliary trans-cutaneous approach. After incision at medial canthus, the wound was further dissected until the medial orbital wall was seen. The adjacent tissue was freed, silicon block was placed over the medial defect. Then, subciliary incision was made and the wound was further dissected until the inferior orbital rim was seen. The adjacent tissue was freed, periorbital fat and inferior oblique muscle of the right eye were visualized within the orbital floor fracture. Silicon block was placed over the floor defect. Forced duction test was performed and there was no restricted vertical movement. The periosteum

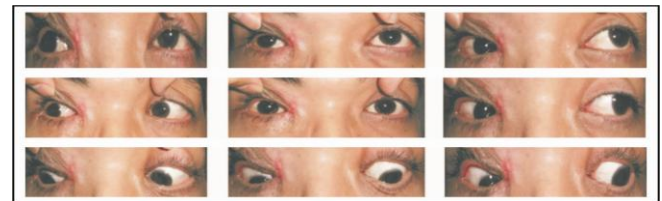
was stitched and the skin was closed. Antibiotics and NSAID were given postoperatively.

At first follow-up after surgery, the eyelid was edematous with stitches in lateral and medial canthus. Movement of the right eye was hard to evaluate due to edema. The other part was normal. The patient was told to train the movement of extraocular muscle and allowed to go home.

Three weeks following surgery, diplopia was reduced. From diplopia chart, there was no diplopia at 11 weeks after surgery. There were restricted movement on upgaze and upper right gaze of the right eye. Goldmann diplopia perimetry was performed. Visual acuity of both eyes were 6/6 (**Fig. 3 & 4**.)



**Fig. 3:** Postoperative examination with Goldmann diplopia perimetry a. Three weeks after surgery. b. Eleven weeks after surgery.



**Fig. 4:** Eleven weeks post-operative. No restriction on ocular movement.

## DISCUSSION

The diagnosis of blowout fracture is made by patient history of being struck by an object, physical examination and radiology. Common signs and symptoms in blowout fracture are periorbital ecchymosis and swelling, restriction of extraocular movements, diplopia and enophthalmos<sup>3,4</sup>. Patient with orbital fractures can present with traumatic iritis, corneal abrasion, hyphema, acute glaucoma, lens trauma, vitreous hemorrhage, commotio retinae, retinal tears or detachment and traumatic optic neuropathy. X-ray, as an ancillary examination in orbital trauma, has some disadvantages; such as

difficulty to show clearly all bone complex structures of the facial skeleton and inability to assess detailed soft tissue elements of the face. Orbital computed tomography scan (CT scan) is the chosen radiologic imaging in establishing orbital wall fractures.

Pure orbital blowout fracture is used to describe fracture of the orbital floor, the medial orbital wall, or both with an intact bony orbital margin<sup>2</sup>. Impure orbital blowout fracture is used when fractures occur in conjunction with fracture of the orbital rim<sup>2,5</sup>.

Treatment of systemic and cranial injury precede the repair of orbital fractures. In view of the sight threatening nature of acute orbital cellulitis, a short course of systemic antibiotics should be considered. Oral anti-inflammatory medications can be given to accelerate resolution of edema and orbital inflammation. When surgical intervention is indicated, it involves release of the entrapped tissue and repair of the bony defect.

In an early severe facial trauma, clinical decision making to diagnose an orbital wall fracture is difficult if there is laceration and soft tissue swelling. The diagnosis of blowout fractures is suggested by anamnesis of trauma mechanism, clinical presentation and imaging. Patient with history of blunt periorbital trauma forceful enough to cause ecchymosis may be suggestive of blowout fracture<sup>1</sup>. Some symptoms suggestive of blowout fracture include vertical diplopia with restriction of up or down gaze, pain on extremes of eye movement, hypoaesthesia in the infraorbital nerve territory, periocular emphysema, enophthalmos, and hypoglobus. In cases with medial rectus muscle or associated soft tissue entrapment, patients may complain of diplopia in horizontal gaze, pain on eye movement, or epistaxis due to avulsion of anterior ethmoidal artery if there is concomitant nasal fracture respectively<sup>6</sup>.

Diplopia and ocular movement disturbances in orbital trauma may be caused by entrapment of connective tissue septa or an extraocular muscle within the fracture, hematoma and or edema in the orbital fat adjacent to the fracture, hematoma or contusion of an extraocular muscle and palsy of an extraocular muscle due to neuronal damage<sup>2,7</sup>.

Traumatic enophthalmos may occur due to atrophy and prolapse of orbital fat, displacement of the orbital walls with significant increase in orbital volume and cicatricial contraction of orbital tissues. Enophthalmos may be masked by orbital hematoma,

swelling or air, which may even cause proptosis in the first few days following trauma. Enophthalmos is always significant in the presence of combined fractures of the orbital floor and medial orbital floor<sup>2</sup>. In the absence of surgical intervention, enophthalmos may increase until 6 months as posttraumatic orbital degeneration and fibrosis.

In this patient, the orbital floor and medial wall fractures were not diagnosed at the first time when he came to the emergency room. Orbital CT scan was not suggested earlier because of the absence of discontinuity on orbital rim palpation and normal orbital X-ray. Although the orbital X-ray showed no fractures, the CT scan should have been performed earlier, because the patient had severe blunt facial injury and possibility of orbital wall fracture could not be excluded by an orbital X-ray alone<sup>8</sup>.

The basic imaging method to detect facial bone fractures is X-ray. Antero-posterior (AP) and lateral projection show the floor and posterolateral orbital wall. Caldwell's view gives the superior and inferior rims, medial walls, ethmoid and frontal sinuses a better image. Waters' view also isolates the orbital roof and floor from surrounding structures<sup>8</sup>. X-ray is the key in establishing fractures and presence of foreign bodies, especially metal. Overlapping of spatial bone structures of the facial skeleton and inability to assess a detailed image of soft tissue elements make it difficult to detect orbital fractures.

Early blunt orbital fracture is sometimes challenging to be established, due to soft tissue swelling. Orbital CT scan should be done in patient with severe soft tissue swelling, unclear ocular movement restriction and diplopia with normal orbital X-ray. Late diagnosis of orbital wall fracture may cause soft tissue entrapment and periocular fibrosis resulting in difficulty in releasing the entrapped tissue when surgery is performed and yield a non-optimal postoperative condition.

CT scan is capable of determining the size and morphology of the fracture, which aids in both clinical assessment and surgical planning. CT scan can determine whether the fracture involves the optic canal, acute proptosis secondary to orbital hemorrhage or orbital emphysema. It can also detect entrapment of rectus muscles, recognized by displacement of the muscle into the fracture site, with or without bone displacement.

In this patient, surgery was indicated because there

were diplopia, restricted eye movements, enophthalmos (> 2 mm) and orbital CT scan showed orbital floor and medial wall fractures. Surgical intervention is indicated in a large fracture involving at least half of the orbital floor, particularly when associated with large medial wall fractures. Orbital fractures of this size have a high incidence of subsequent significant enophthalmos<sup>1</sup>.

The proper timing of surgical treatment in pure orbital fractures should be customized for each patient. Surgical timing of orbital fractures was strongly related to combination of anatomical location of fracture, eventual exposition of fracture, cerebro spinal fluid (CSF) leakage or penetrating wounds, patient's age, eventual functional impairments or muscle entrapment and serious conditions of compression or ischemia<sup>9</sup>.

Orbital soft tissue entrapment may generate the oculocardiac reflex (bradycardia, heart block, nausea, vomiting and syncope)<sup>10</sup>. Absolute and immediate indication of surgery are potentiation of the oculocardiac reflex and retrobulbar hematoma with compression of the globe or the optical nerve in combination with impaired vision<sup>10</sup>.

Surgery is generally recommended within two weeks of the injury. If the surgery is delayed, fibrosis between orbital tissues, sinus mucosa and bone fragments will make surgery more difficult. Although most surgeons prefer early surgery for better postoperative result, Dal Canto and Linberg showed delayed orbital floor and or medial wall fracture repair (15-29 days after trauma) as effective as early (1-14 days after trauma) repair in regard to postoperative motility, diplopia and time to resolution.

Surgical approach to the orbital fracture varies. An orbital floor blowout fracture is usually approached via lower eyelid incision. A medial wall fracture can be repaired via medial canthal incision. Alternatively, a transcaruncular approach can be used. If the patient already has a significant eyelid laceration in association with the fracture, this can be utilized for access to the fracture<sup>2</sup>. The lower eyelid incision can be made through the skin or through the conjunctival (fornix inferior)<sup>1,2</sup>. This provides an excellent access to the whole of the orbital floor and to the medial orbital wall. For the management of small "trapdoor" orbital floor fractures, the transconjunctival approach without lateral canthotomy and inferior cantholysis is adequate<sup>2</sup>. In this patient, we did transcutaneous incision for medial and orbital floor fracture.

There is a wide array of implants such as silicone, titanium, porous polyethylene, hydroxyapatite, methylmethacrylate, autologous bone or cartilage, which were used to bridge the fracture gap in orbital reconstruction<sup>2</sup>. Autogenous bone can be harvested from iliac crest or outer table of the skull. This entails a lengthier operation, a longer stay and a higher risk of morbidities and complications for donor<sup>2</sup>. We chose silicone among other implants because it was easily available, affordable and inert. To ensure proper placement of the implant, it is suggested to do the CT Scan postoperatively.

Postoperative complications (eg. persistent diplopia, intraorbital hemorrhage, orbital cellulitis, loss of vision, dacryocystitis, ptosis, lower lid retraction, lower lid entropion, lower lid lymphedema, implant extrusion, infraorbital sensory loss, undercorrection of enophthalmos, proptosis, hyperglobus, and cyst formation) may occur after orbital fractures reconstruction<sup>2,3</sup>. In this patient, enophthalmos still persisted after the surgery. This sub-optimal result might be due to fibrosis and bone fragments between orbital tissues that occurred in delayed management.

In summary, early blunt orbital trauma is difficult to be established as an orbital wall fracture. Hence, patient with severe soft tissue swelling, unclear enophthalmos and ocular movement restriction, diplopia with normal orbital X-ray should undergo an orbital CT scan. In a late diagnosed orbital wall fracture, the entrapped soft tissue may become fibrotic and make it difficult for the surgeon to release the entrapped tissue. Consequently, a sub-optimal post-operative condition may occur. Therefore, it is important to choose the proper imaging modality in medial orbital wall and blowout fracture.

## Conflict of Interest

Authors declared no conflict of interest

## Authors' Designation and Contribution

Yunia Irawati; Head of Plastic and Reconstructive Surgery Division: *Data collection, Manuscript writing and final review.*

Carennia Paramita; Research Assistant: *Data collection, Manuscript writing and final review.*

Dian Farikha; Resident Department of Ophthalmology: *Data collection, Manuscript writing and final review.*

## REFERENCES

1. **Foster J, Carter K, Durairaj V, Kavanagh MC, Korn BS, Nelson CC, et al.** Section 7. Orbit, Eyelids, and Lacrimal System. In: American Academy of Ophthalmology. Singapore: LEO, 2015: 129-134.
2. **Leatherbarrow B.** Oculoplastic surgery. In: 2nd Ed. London: Informa Healthcare; 2011: 547-562.
3. **Chi MJ, Ku M, Shin KH, Sehyun B.** An analysis of 733 surgically treated blow out fractures. *Ophthalmologica*. 2010; **224**: 167-175.
4. **Kamath SJ, Kamath M, Kamath M, Pai SG, Chhablani J, Chowdary S.** Short Report A Study Of Orbital Fractures In A Tertiary Health Care Center. *Online J Heal Allied Scs*. 2007; **6 (1)**: 1-4.
5. **Kanski J, Bowling B.** Orbital trauma. In: *Clinical Ophthalmology: A Systemic Approach*. 6th Ed. Philadelphia: Elsevier Ltd. 2007: 848-851.
6. **Fan M, Burkat CN, Wladis E.** Orbital medial wall fractures. Available at [http://eyewiki.aao.org/Orbital\\_Medial\\_Wall\\_Fractures#Symptoms](http://eyewiki.aao.org/Orbital_Medial_Wall_Fractures#Symptoms). Accessed September 6, 2012.
7. **Myga-Porosilo J, Skrzewski S, Sraga W, Borowiak H, Jackowska Z, Kluczevska E.** CT imaging of facial trauma. Role of different types of reconstruction. Part I - bones. *Polish J Radiol*. 2011; **76 (1)**: 41-51.
8. **Thaller S, McDonald W.** Facial trauma. In: New York: Marcell Dekker, 2004: 241-250.
9. **Matteini C, Renzi G, Becelli R, Belli E, Iannetti G.** Surgical timing in orbital fracture treatment: experience with 108 consecutive cases. *J Craniofac Surg*. 2004; **15 (1)**: 145-150.
10. **Ceylan O, Mutlu F, Altinsoy H, Uysal Y, Tuncer K.** Management of diplopia in patients with blowout fractures. *Indian J Ophthalmol*. 2011; **59 (6)**: 461.

