

Axenfeld-Rieger Syndrome in a Pakistani Family

Rebecca¹, Murtaza Sameen Junejo², Syed Jamil³, Sameen Afzal Junejo⁴
^{1,3}Isra University Hospital, ^{3,4}Liaquat University of Medical and Health Sciences, Jamshoro

ABSTRACT

A case of 46-year-old male is presented who came with complaints of painless, progressive deterioration of vision in both eyes and he was using Latanoprost and Cosopt eye drops in both eyes. His visual acuity was 6/60 in right eye and perception of light in left eye. The intraocular pressures were 28 mm Hg (OD) and 18 mm Hg (OS). There was iridocorneal adhesion and posterior embryotoxon in his right eye and leucoma in left eye. Cup-disc ratio was 0.7. He had hypodontia, midface hypoplasia, hypertelorism, and telecanthus. Family history was also positive. His sister also had iris stromal hypoplasia along with posterior embryotoxon. A diagnosis of Axenfeld Rieger Syndrome was made. The patient underwent glaucoma drainage device (AGV) surgery in his right eye. Post operative pressures were 10 mm Hg. He was later referred to maxillofacial surgeon, cardiologist and counseled for avoiding cross marriages to prevent this inherited disease.

Key Words: Anterior segment dysgenesis, Axenfeld-Rieger syndrome, Corectopia.

How to Cite this Article: Rebecca, Junejo MS, Jamil S, Junejo SA. Axenfeld-Rieger Syndrome in a Pakistani Family. Pak J Ophthalmol. 2020, **36 (2)**:172-175.

Doi: 10.36351/pjo.v36i2.974

INTRODUCTION

World-wide prevalence of Axenfeld-Reiger syndrome (ARS) is 1:200,000. It is a rare disorder characterized by systemic and ocular anterior segment dysgenesis.

Various overlapping phenotypes, including Axenfeld anomalies, Rieger anomalies and Rieger syndrome are associated with ARS.¹

The posterior embryotoxon, changes in iris stroma and anterior chamber angle anomalies are ocular manifestations of ARS. In ARS patients, characteristic systemic features like dental anomalies including, hypodontia, microdontia and oligodontia, umbilical anomalies and maxillary hypoplasia have been reported.¹

*Correspondence: Murtaza Sameen Junejo
Liaquat University of Medical and Health Sciences.
Email: drmurtazasameen@gmail.com*

Received: January 20, 2020

Accepted: March 2, 2020

Due to developmental anomalies of angle, there is glaucoma. In patients with ARS, gene mutations in *fork head box protein C1 (FOXC1)*, chromosomes increase of outflow resistance and ocular hypertension in nearly 50% of the cases, resulting in secondary 6p25) and *pituitary homeobox 2 (PITX2)*, chromosomes 4q25) encoding transcription have been noted.² Another chromosome 13q14 has been reported in ARS but its function is still unknown.³ Up till now, there have been only few cases reported in Asian population.^{4,5}

In Pakistan ARS is very rare. Our purpose to report this case is to familiarize the ophthalmologists and health care professionals to counsel the patients regarding this disease and its inheritance pattern in families and to avoid it by discouraging cross marriages.

CASE PRESENTATION

A well oriented male 46-years-old (weight: 83 kg) presented to Laser Sight on November 7, 2019, with

complaints of painless, progressive deterioration of vision in his right eye for 1 month and decreased vision in left eye for 10 years. He was using Latanoprost eye drops (1 drop once a day) and Cosopt eye drops (1 drop twice a day) in both eyes for 1 year. An informed consent was obtained from the patient.

On Ocular examination his best-corrected visual acuity (BCVA) was 6/60 (OD) and perception of light (OS), while the intraocular pressure (IOP) was 28 mm Hg (OD) and 18 mm Hg (OS) measured with Goldmann applanation tonometer. The slit-lamp examination of right anterior segment showed paracentral corneal opacity of 1.5 cm and bullae at 6 and 7 o'clock (Fig. 1). The diameters of cornea were 10 mm OU (Fig. 1). The iris changes included stromal hypoplasia with corectopia (Fig. 1). Gonioscopy showed an iridocorneal adhesion of the anterior angle on his right eye at all 4 quadrants along with posterior embryotoxon. The retinal photography of the right eye showed Cup-disc ratio of 0.7 with notching of vessel and neuroretinal rim thinning along with peripapillary atrophy. The ultrasound B scan of Left eye was unremarkable while the anterior segment examination of left eye showed leucoma from limbus to limbus.

On general physical examination and systemic examination, hypodontia of the maxillary anterior teeth was observed in both the primary and permanent dentition, for which he was referred to a dentist. Craniofacial anomalies, including mid face hypoplasia, hypertelorism, and telecanthus were observed. ARS was diagnosed on the basis of clinical features discussed above. The patient underwent glaucoma drainage device (AGV) surgery in his right eye. One week later IOP was 10 mm Hg in his right eye. Family history was also positive due to consanguineous marriage. He had six brothers and five sisters, out of whom two brothers and one sister had positive history of decreased vision due to glaucoma. His sister also had maxillary, anterior teeth and iris stromal hypoplasia along with posterior embryotoxon. They were referred to maxillofacial surgeon, cardiologist and counseled for cross marriages to prevent this inherited disease.

DISCUSSION

In 1920, Theodor Axenfeld first described ARS characterized by posterior embryotoxon and prominent iris strands extending from the peripheral iris to this line. A case with hypoplasia,

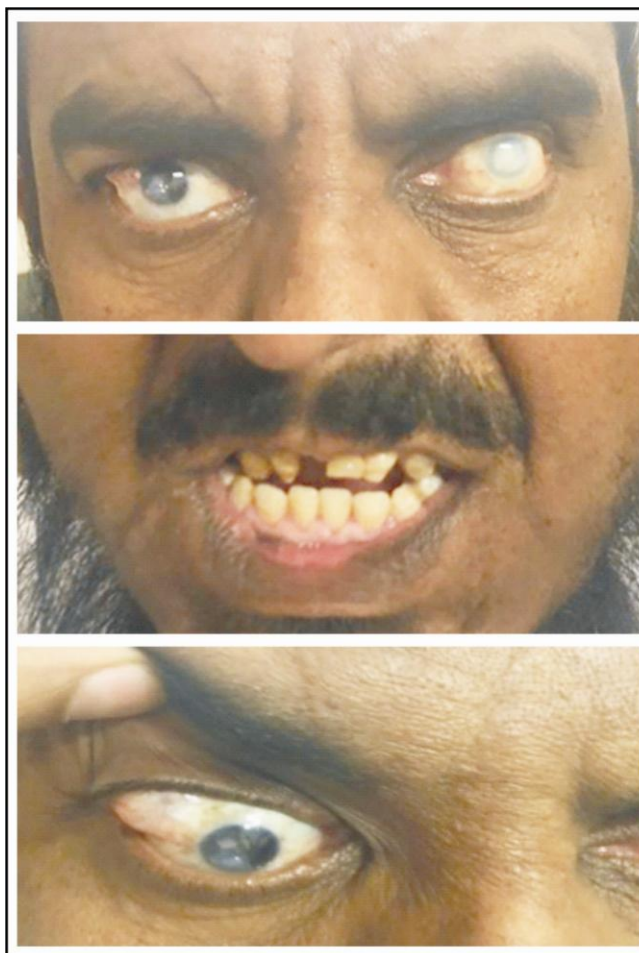


Fig. 1: Top: Hypertelorism with left leucocoria. Middle: Dental Abnormalities. Ahmed: Glaucoma Valve

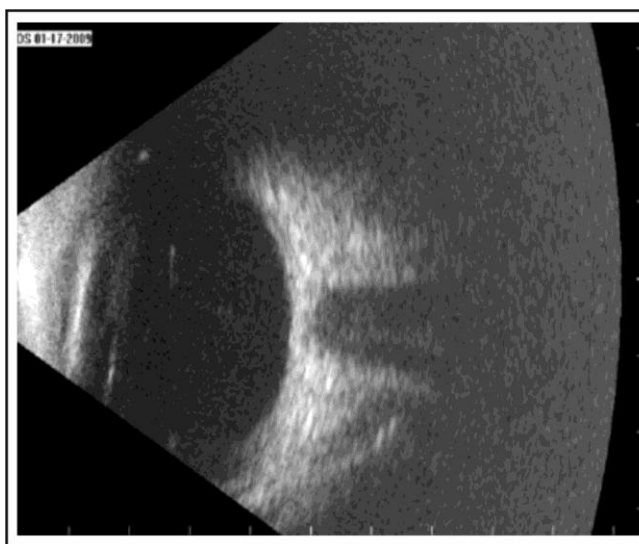


Fig. 2: B-scan of Left Eye.

iris like stromal hypoplasia and corectopia was described in 1934.⁶ ARS includes a group of disorders and is divided into three subgroups; Axenfeld anomaly is characterized by a prominent, anteriorly displaced Schwalbe line called posterior embryotoxon and prominent iris strands extending from the peripheral iris to this line. Rieger anomaly includes the condition with central iris changes like stromal hypoplasia and irregular-shaped pupils along with features mentioned in Axenfeld anomaly. Rieger syndrome includes Rieger anomaly associated with systemic features.⁷ The diagnosis of Axenfeld-Rieger syndrome was made as he presented with ocular anomalies of Rieger anomaly together with systemic anomalies. Thus, since 1985 the term ARS has been used clinically and Ozeki et al⁸ reported that Rieger anomaly accounted for 10%, Axenfeld anomaly accounted for 71%, while Rieger syndrome covered 19% cases of ARS. However, we have seen that most of the ARS cases are sharing an overlap of features within this spectrum so that the delineation of each of these is not clear.

Apart from such considerations, other unusual ocular anomalies have also been reported. Two cases were reported by Espana et al⁹ and Parikh et al¹⁰ with different presentation of detached Schwalbe line suspended in anterior chambers. Schwalbe line originates from neural crest cells, due to which impaired development is related to the pathogenesis of ARS.⁹ Hypoplasia of extraocular muscles derived from mesodermal complex also appeared in ARS. Retinal detachment have also been reported in few cases of ARS. Glaucoma Drainage devices are very useful adjunct for the treatment of refractory glaucoma. However, these devices come with an array of potential serious complications.¹⁰ The most common delayed complication is exposure of the tube overlying eroded conjunctiva.¹⁰ In our study, we also used Glaucoma Drainage device in the right eye which improved the vision of patient and reduced intraocular pressure.

About 50% of ARS patients develop glaucoma. With a 20-year follow-up, Mandal and Pehera showed the safety and effectiveness of trabeculotomy and trabeculectomy for ARS children with early-onset of glaucoma. In the present case report, the patient was referred to maxillofacial surgeon.

In summary, ARS is a rare disorder, the ocular manifestations may be vision threatening, therefore a regular and long term follow up by an ophthalmologist is necessary.

A convincing conclusion is still awaited about prognosis of this disease in Pakistani population. Limitation of this case report is that we had not yet obtained the ocular and physical examinations from his father and sister, and gene analysis could not be performed.

Conflict of Interest

There is no conflict of interest between authors and on funding.

REFERENCES

1. **Titheradge H, Togneri F, McMullan D, Brueton L, Lim D, Williams D.** Axenfeld-Rieger syndrome: further clinical and array delineation of four unrelated patients with a 4q25 microdeletion. *Am J Med Genet.* 2014; **164A**: 1695–1701.
2. **Ito YA, Walter MA.** Genomics and anterior segment dysgenesis: a review. *Clin Exp Ophthalmol.* 2014; **42** (1): 13–24.
3. **Tumer Z, Bach-Holm D.** Axenfeld-Rieger syndrome and spectrum of PITX2 and FOXC1 mutations. *Eur J Hum Genet.* 2009; **17** (12): 1527–1539.
4. **Seifi M, Footz T, Taylor SA, Elhady GM, Abdalla EM, Walter MA.** Novel PITX2 gene mutations in patients with Axenfeld-Rieger syndrome. *Acta Ophthalmol.* 2016; **94** (7): e571–e579.
5. **Yin HF, Fang XY, Jin CF, Yin JF, Li JY, Zhao SJ, et al.** Identification of a novel frame shift mutation in PITX2 gene in a Chinese family with Axenfeld-Rieger syndrome. *J Zhejiang Univ Sci. B.* 2014; **15** (1): 43–50.
6. **Idrees F, Vaideanu D, Fraser SG, Sowden JC, Khaw PT.** A review of anterior segment dysgeneses. *Surv Ophthalmol.* 2006; **51**: 213–231.
7. **Rao A, Padhy D, Sarangi S, Das G.** Unclassified Axenfeld-Rieger Syndrome: a case series and review of literature. *Semin Ophthalmol.* 2016; 1–8.
8. **Ozeki H, Shirai S, Ikeda K, Ogura Y.** Anomalies associated with Axenfeld-Rieger syndrome. *Graefes Arch Clin Exp Ophthalmol.* 1999; **237**: 730–734.
9. **Espana EM, Mora R, Liebmann J, Ritch R.** Bilateral prominent schwalbe ring in the anterior chamber in a patient with axenfeld-rieger syndrome and megalocornea. *Cornea,* 2007; **26**: 379–381.
10. **Parikh RS, Parikh SR, Debashish B, Harsha BL, Thomas R.** Unusual presentation in Axenfeld-Rieger syndrome. *Indian J Ophthalmol/.* 2011; **59**: 312–314.

Author Designation and Contribution

Rebecca; Postgraduate Resident: *Data collection, literature review, final review.*

Murtaza Sameen Junejo; Senior Registrar: *Data collection, Manuscript writing, literature review.*

Syed Jamil; Assistant Professor: *Literature review and final review.*

Sameen Afzal Junejo; Professor: *Literature review and final review.*

