

Avascular Retinal Pigment Epithelial Detachment Treated With Intravitreal Ranibizumab: 3-Year Follow-up

Imran Akram, Amjad Akram

Pak J Ophthalmol 2019, Vol. 35, No. 4

See end of article for authors affiliations

Correspondence to:
Mr. Imran Akram
Consultant Ophthalmic &
Vitreoretinal Surgeon
St Helens & Knowsley Teaching
Hospitals NHS Trust
Email:
imranakram2020@gmail.com

Purpose: To evaluate the long-term effect of intravitreal Ranibizumab on visual acuity and the morphology of retinal pigment epithelial detachments, not associated with choroidal neovascularization.

Place and Duration of Study: Ophthalmology Department at St Helens & Knowsley Teaching Hospital, United Kingdom, between 2011 and 2013.

Study Design: Retrospective case series.

Patients and Methods: This was a retrospective case series looking at case notes and retinal imaging of 12 patients with avascular pigment epithelial detachment. At pre-treatment baseline all patients had demographic characteristics recorded such as date of birth, sex, race and a general health questionnaire. These patients were treated with three injections of Ranibizumab at monthly interval. Corrected visual acuity and PED height were compared at 3, 6, 12, 24 and 36 months post injection.

Results: At 6 months post-injection PED height decreased by up to 50% as compared to baseline height and this was largely maintained over 36 months post-injection. Two eyes showed subsequent increase in PED height to baseline level although further treatment was not performed. Visual acuity did not improve in any case although was maintained at baseline in 8 cases for 36 months and reduced in 4 cases due to central macular atrophic changes observed over 36 months. No case of RPE rip was seen in this series.

Conclusion: Avascular PED treated with intravitreal Ranibizumab shows some reduction of the height of the PED, which in turn reduced the risk of a spontaneous RPE rip.

Key Words: Avascular Pigment Epithelial Detachment, Ranibizumab, Choroidal neovascularisation.

Retinal pigment epithelial detachment (PED) is a common manifestation in several retinal conditions including age-related macular degeneration¹. Based on retinal imaging as well as clinical examination, PEDs can be classified as drusenoid, serous or vascular^{2,3,4}. Vascularised PEDs, as the name suggest, are associated with choroidal neovascularization (CNV). Drusenoid and serous PEDs may or may not have an associated CNV. Anti-VEGF therapy has a well proven role in the treatment of vascularized PED^{5,6}. Less well

established is the beneficial effect of anti-VEGF therapy in those PEDs where a CNV is not clearly present. Large serous PEDs were excluded from phase 3 clinical trials such as TAP, ANCHOR and MARINA^{7,8,9} trials. As such these trials cannot be relied upon to provide management strategies for these lesions.

Development of a rip in a PED can result in permanent damage to central vision^{10,11}. Such a rip is

often spontaneous although intravitreal therapy can also precipitate an RPE rip^{12,13}. It is therefore desirable to reduce the height of a PED in order to minimize the risk of a rip. Furthermore, a longstanding PED presumably interferes with the nutrition to the RPE and photoreceptors and thus early flattening of the PED or reducing its height was an important treatment rationale in this study. No universally agreed guidelines exist on the treatment of PEDs not associated with a CNV. One study¹⁴ looked specifically at the role of the anti-VEGF agent, Ranibizumab (Lucentis) in non-vascularised PEDs but the follow-up period in that study was 12 months. The purpose of this study was to look at the long term effects of 3 Ranibizumab injections given in eyes with non-vascularised PEDs. The effects were monitored for up to 36 months and to date this is the longest follow-up published for this sub-set of treated patients.

METHODS

In this study, we looked at eyes with fovea involving avascular PED of at least 100 microns height, which were treated with 3 injections of intravitreal Ranibizumab between 2011 and 2013. All patients had a baseline visual acuity of at least 50 ETDRS letters. Absence of associated choroidal neovascularization (CNV) was established by structural OCT and fluorescein angiography (Heidelberg Spectralis). Patients with co-existing macular pathology such as diabetic macular edema, CSCR, retinal angiomatous proliferation (RAP) and epiretinal membrane were not treated with anti-VEGF.

At pre-treatment baseline, all patients had demographic characteristics recorded such as date of birth, sex, race and a general health questionnaire. Best corrected visual acuity was recorded using ETDRS letter score. Volume OCT scanning of the macula was performed. Fluorescein angiography was performed in all patients to rule out presence of CNV. OCT Angiography was not available at the time. The patients were then evaluated by a retina specialist to consider suitability for Ranibizumab treatment. PED

height was measured using the inbuilt calipers in the OCT software (see Fig). Maximum vertical distance between Bruchs membrane and the RPE was used as a measure of baseline PED height. The PED was classified as drusenoid or serous based on the reflectivity of the sub-RPE space on OCT examination. Informed consent was obtained for the full course of treatment. All patients received three Ranibizumab injections at four weekly intervals according to departmental protocol. No supplementary injections were performed in these patients as we did not consider the Royal College of Ophthalmologists wet AMD guidelines to be applicable to these cases. The aim of treatment was to reduce height of the PED in order to prevent the possibility of a future rip as well as to stabilize and improve visual acuity.

The primary outcome measures were effect on reduction in PED height and effect on visual acuity over the course of 3 years following the initial loading dose of 3 Ranibizumab injections. Following 3 initial injections all patients were monitored for up to 36 months. At each visit visual acuity was measured using ETDRS letters. PED height was measured on structural OCT scan.

RESULTS

Twelve eyes of 12 patients met the inclusion criteria for this study. There were 7 females and 5 males. Median age was 77 (age range 58-90). At baseline, 9 PEDs were considered serous based on hyporeflectivity on OCT scanning. 3 PEDs were considered drusenoid. Mean baseline visual acuity was 59.66 ETDRS letters (range 50-69). Mean PED height was 281 microns (range 90-410).

Table 1. Baseline characteristics.

Median age in years (range)	77 (58-90)
Gender (male: female)	5:7
PED morphology (serous: drusenoid)	9:3
Visual acuity Mean in ETDRS letters (range)	59.66 (50-69)
PED height Mean in microns (range)	281 (90-410)

Table 2: Measurements of PED mean height in microns (SD) and mean best corrected visual acuity BCVA in ETDRS letters (SD).

	Baseline	Month 3	Month 6	Month 12	Month 24	Month 36
BCVA	59.66 (14.66)	58.55 (15.12)	54.78 (14.99)	54.34 (14.81)	53.85 (14.96)	53.12 (15.32)
PED Height	281 (148.92)	216.22 (135.66)	142.34 (119.32)	111.02 (120.73)	98.34 (129.45)	96.66 (131.22)

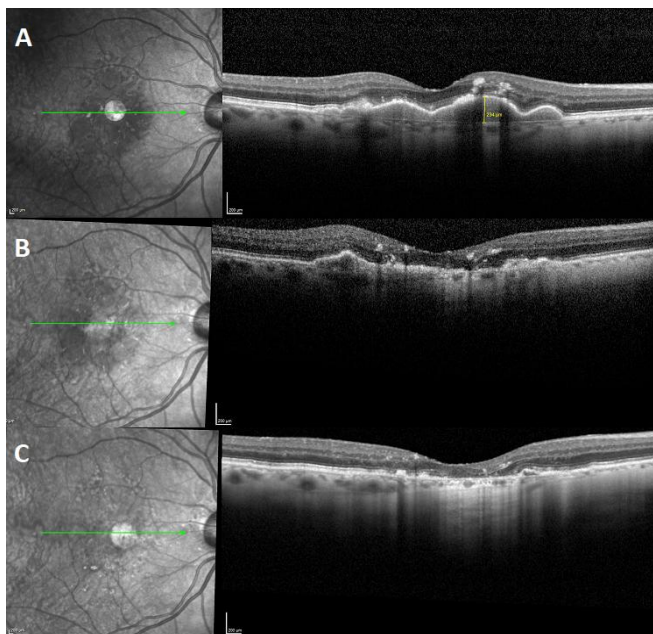


Fig. 1: OCT scan of same eye (A) before any treatment, showing “dry” PED. (B) 6 months after 3rd injection showing almost complete resolution of PED. (C) 36 months after injections showing complete PED flattening and RPE atrophy.

PED height reduced by 64.78 microns at month 3 following the third Ranibizumab injection. From there onwards, the reduction in height was gradual and a further mean reduction of 96.56 microns was noted between month 3 and month 36 post-injection. Least reduction in height was noted in the drusenoid PEDs although these eyes showed the most stable VA. Five eyes with serous PED showed complete resolution of the PED with no recurrence during the follow-up period. Two eyes with serous PED showed a recurrent increase in PED height to baseline levels between months 12 and 24. BCVA showed a gradual mean decrease of 6.54 ETDRS letters over the 36 months of follow-up. No eye showed development of CNV throughout the study period.

DISCUSSION

The pathogenesis of pigment epithelial detachment (PED) is not completely understood. Anatomical apposition of the RPE to the underlying Bruch’s membrane is crucial for the nutritional support of the outer retina. The forces maintaining this adhesion are not fully clear. A decrease in overall conductivity across Bruch’s membrane resulting in reduced fluid

exchange between the choroid and RPE is considered to be a widely accepted underlying mechanism of PED formation¹⁵, although it may be likely that drusenoid and serous PEDs could have different pathogenesis¹⁶. Inflammatory mediators¹⁷ as well as VEGF¹⁸ have been implicated in the increased permeability across Bruch’s membrane.

For ease of description, we would like to introduce the terms “dry PED” to denote avascular PEDs, as distinguished from “wet PED” which are clearly associated with choroidal neovascularization as shown by structural OCT and Fluorescein/Indocyanine Green angiography. Dry PEDs include drusenoid PEDs and serous PEDs which show no features of CNV. There is no universally accepted treatment strategy for dry PEDs. This study represents the longest published follow-up (3 years) of eyes with avascular PED treated with Ranibizumab in a real world setting. In 12 eyes of 12 patients, 3 intravitreal injections of Ranibizumab were performed to treat Dry age-related PED. Maximum reduction in PED height was seen in the first 6 months followed by a more gradual mean reduction. This effect was sustained in 10 eyes over 3 years whereas 2 eyes showed recurrence of the PED. In 5 eyes complete flattening of the PED was observed. Beneficial effect on visual acuity was less encouraging as compared to treating fibrovascular PEDs with Ranibizumab^{19,20}. However, 8 eyes maintained their baseline visual acuity. Interestingly these included the 2 eyes which developed recurrent PED. Four eyes showed a gradual decline in visual acuity over 36 months. All of these were eyes in which the PED had completely flattened and outer retinal degenerative changes gradually developed.

Our study findings compare favorably with a similar study from Vienna¹⁴ although Ritter et al’s follow-up period was 12 months compared to our 36 month follow-up. They also recruited 12 patients but half of these were treated with up to 6 Ranibizumab injections over 6 months. They also concluded that Ranibizumab treatment can reduce PED height and volume but the effect was not maintained over the 12 months period of their study. Other studies have found limited benefit of anti-VEGF in bringing about complete resolution of the PED element of wet AMD²¹ whereas one large series²² has correlated the anatomic response of treatment to baseline PED height, associated vascularization and also the type of anti-VEGF used.

The findings of this retrospective case series

suggest structural benefit and visual stability in some patients with age-related “dry” PEDs treated with intravitreal Ranibizumab. This further suggests that VEGF may indeed have a role in the pathogenesis of age-related pigment epithelial detachments even when no structural or angiographic features of choroidal neovascularization are present.

COMPLIANCE WITH ETHICAL STANDARDS

We have no financial disclosure and no conflict of interest in this case.

Informed consent was obtained from the patient in order to use his images in this publication.

REFERENCES

1. **Zayit-Soudry S, Moroz I, Loewenstein A.** Retinal pigment epithelial detachment. *Surv Ophthalmol.* 2007; 52: 227-243.
2. **Hartnett ME, Weiter JJ, Garsd A, Jalkh AE.** Classification of retinal pigment epithelial detachments associated with drusen. *Graefes Arch Clin Exp Ophthalmol.* 1992; 230: 11-19.
3. **Poliner LS, Olk RJ, Burgess D, Gordon ME.** Natural history of retinal pigment epithelial detachments in age-related macular degeneration. *Ophthalmology.* 1986; 93: 543-551.
4. **Gass JD.** Serous retinal pigment epithelial detachment with a notch: a sign of occult choroidal neovascularization. *Retina.* 1984; 4: 205-220.
5. **Arias L.** Treatment of retinal pigment epithelial detachment with antiangiogenic therapy. *Clinical Ophthalmol.* 2010; 4: 369-374.
6. **Chevreaud O, Oubraham H, Cohen SY.** Ranibizumab for vascularized pigment epithelial detachment: 1-year anatomic and functional results. *Graefes Arch Clin Exp Ophthalmol.* 2017; 255 (4): 743-51.
7. **Photodynamic therapy of subfoveal choroidal neovascularisation in age-related macular degeneration with verteporfin: one-year results of 2 randomized clinical trials-TAP report. Treatment of age-related macular degeneration with photodynamic therapy (TAP) Study Group.** *Arch Ophthalmol.* 1999; 117: 1329-1345.
8. **Rosenfeld PJ, Brown DM, Heier JS, Boyer DS, Kaiser PK, Chung CY et al.** Ranibizumab for neovascular age related macular degeneration. *N Engl J Med.* 2006; 355: 1419-1431.
9. **Brown DM, Kaiser PK, Michels M, Soubrane G, Heier JS, Kim RY, Sy JP, Schneider S, ANCHOR Study Group.** Ranibizumab versus verteporfin for neovascular age-related macular degeneration. *N Engl J Med.* 2006; 355: 1432-1444.
10. **Decker WL, Sanborn GE, Ridley M.** Retinal pigment epithelial tears. *Ophthalmology.* 1983; 207: 27-35.
11. **Bakri SJ, Kitzmann AS.** Retinal pigment epithelial tear after intravitreal ranibizumab. *Am J Ophthalmol.* 2007; 143: 505-507.
12. **Chang LK, Sarraf D.** Tears of the retinal pigment epithelium: an old problem in a new era. *Retina.* 2007; 27: 523-534.
13. **Ronan SM, Yoganathan P, Chien FY, Corcostegui IA, Blumenkranz MS, Deramo VA, Elner SG, et al.** Retinal pigment epithelium tears after intravitreal injection of bevacizumab (Avastin) for Neovascular age-related macular degeneration. *Retina.* 2007; 27: 535-540.
14. **Ritter M, Bolz M, Sacu S, Deak GG, Kiss C, Prunte C, Schmidt-Erfurth UM.** Effect of intravitreal Ranibizumab in avascular pigment epithelial detachment. *Eye.* 2010; 24: 962-968.
15. **Moore DJ, Hussain AA, Marshall J.** Age-related variation in the hydraulic conductivity of Bruch's membrane. *Invest Ophthalmol Vis Sci.* 1995; 36: 1290-1297.
16. **Sheraidah G, Stein metz R, Maguire J, Pauleikhoff D, Marshall J, Bird AC.** Correlation between lipids extracted from Bruch's membrane and age. *Ophthalmology.* 1993; 100: 47-51.
17. **Hollyfield JG, Bonilha VL, Rayborn ME, Yang X, Shadrach KG, Lu L, Ufret RL, Salomon RG, Perez VL.** Oxidative damage-induced inflammation initiates age-related macular degeneration. *Nat Med.* 2008; 14: 194-198.
18. **Oh H, Takagi H, Takagi C, Suzuma K, Otani A, Ishida K, Matsumura M, Ogura Y, Honda Y.** The potential angiogenic role of macrophages in the formation of choroidal neovascular membranes. *Invest Ophthalmol Vis Sci.* 1999; 40: 1891-1898.
19. **Arora S, McKibbin M.** One-year outcome after intravitreal ranibizumab for large, serous pigment epithelial detachment secondary to age-related macular degeneration. *Eye.* 2011; 25: 1034-1038.
20. **Panos GD, Gatziofufas Z, Petropoulos IK, Dardabounis D, Thumann G, Hafezi F.** Effect of ranibizumab on serous and vascular pigment epithelial detachments associated with exudative age-related macular degeneration. *Drug Des Devel Ther.* 2013; 7: 565-9.
21. **Cho HJ, Kim KM, Kim HS, Lee DW, Kim CG, Kim JW.** Response of Pigment Epithelial Detachment to Anti-Vascular Endothelial Growth Factor Treatment in Age-Related Macular Degeneration. *Am J Ophthalmol.* 2016 Jun; 166: 112-119.
22. **Dirani A, Ambresin A, Marchionno L, Decugis D, Mantel I.** Factors Influencing the Treatment Response of Pigment Epithelium Detachment in Age-Related Macular Degeneration. *Am J Ophthalmol.* 2015 Oct; 160 (4): 732-8

Author's Affiliation

Mr Imran Akram
FRCS FRCOphth DO
Consultant Ophthalmic & Vitreoretinal Surgeon
St Helens & Knowsley Teaching Hospitals NHS Trust
Marshalls Cross Road, St Helens WA9 3DA, United Kingdom

Brigadier Amjad Akram
FCPS, FRCS(Glas), FRCS(Ed)
Consultant Ophthalmic Surgeon
Combined Military Hospital, Kharian Cantt, District Gujrat

Author's Contribution

Mr Imran Akram
Data collection, Manuscript writing.
Brigadier Amjad Akram
Manuscript writing, literature review, critical analysis.