

# Diagnostic Applications of "B-Scan"

Ejaz Ahmed Javed, Aamir Ali Ch., Iftikhar Ahmad, Mehmood Hussain

*Pak J Ophthalmol 2007, Vol. 23 No.2*

See end of article for authors affiliations

Correspondence to:  
Ejaz Ahmed Javed  
DPS Colony  
Race Course Road Near  
New Civil Lines  
Faisalabad

Received for publication  
May' 2006

**Purpose:** To evaluate the diagnostic importance of "B-Scan" in opaque media where other routine instrumental producers were unreliable

**Materials And Methods:** The "B-Scan" was done on 463 eyes of 463 patients at Madina Medical Centre, University of Faisalabad, during the period March 2005 to March 2006. There were 339(73.2%) male and 124(26.8%) female patients. The age ranged between 6 months to 80 years. A specialized proforma was developed to record the data. Most of the patients were referred from different clinics and hospitals of the Punjab.

**Results:** The maximum number of the participants had age between 21 years to 30 years. Out of 463 patients 20 had only corneal pathology, 90 had only mature cataract, 60 had only vitreous hemorrhage, 68 had only retinal detachment, 51 tractional retinal detachment, 4 had retinoblastoma, 2 optic nerve anomaly, 2 choroidal pathology, 2 persistent hyperplastic primary vitreous (PHPV). 163 patients has multiple signs e.g. corneal pathology, cataract, vitreous hemorrhage and retinal detachment. Asteroid hyalosis was seen in 1 patient.

**Conclusions:** B-scan proved to be a valuable diagnostic modality in opaque media and had remarkable prognostic importance.

Ultrasound technology, also known as sonar, echography or acoustic imaging, was developed during world war I as a method of detecting under water objects, including submarines<sup>1</sup>. The ultrasound is based on physical principles of tissue acoustic impedance mismatch and pulse echo technology. Echoes are produced at adjoining tissues interfaces that have differential acoustic impedance. The greater the difference in acoustic impedance, the stronger the echo. The ultrasound waves have a frequency greater than 20 KHz<sup>2</sup>. In standard ophthalmic ultrasound, frequencies are in the range of 8 to 10MHz. This high frequency produces short wave lengths, which allow visualization of smaller ocular structures, while abdominal ultrasound has lower frequency (1 to 5MHz) which produces longer wave length and penetrates deeper tissues<sup>3</sup>.

The reflected echoes are received, amplified, produced electronically and displayed in visual format as an "A-scan" or a "B-scan"<sup>4</sup>.

The A-scan is a one-dimensional, time amplitude display. The height of the spike indicates the amplitude and strength of echo. The B-scan presents echoes as dots rather than spikes, intensity of dots relates to the intensity of reflection. It produces a two dimensional, cross sectional display of the globe and orbit. The weaker echoes are noted from vitreous cells and stronger echoes from retinal tissues, sclera and calcifications<sup>5</sup>. So the B-scan can be used for the following ocular problems<sup>6</sup>.

- Evaluation of anterior or posterior segment in eyes with opaque media.
- To assess dimensions of ocular tumors.
- To differentiate PVD and RD from vitreous hemorrhage etc.

- To evaluate orbital disorders
- To detect and locate intra-ocular foreign bodies.

## MATERIALS AND METHODS

This was a retrospective and observational study on 463 cases having opaque media due to trauma, diabetes mellitus, hypertension, congenital or acquired mature cataract, corneal dystrophy, leukocoria and Eale's disease.

The study was conducted at Madina Medical Centre, The University of Faisalabad from March 2005 to March 2006. The patients were collected from out patient department (OPD) of Madina Medical Centre and from referral from other clinics and hospitals. A proforma was made to record the data.

History of decreased vision was the commonest presentation. It was evaluated further as history of trauma, working environment or tools, bleeding disorders, past medical or surgical history, decreased vision, diabetes, hypertension, vitrectomy or any other surgical procedures.

A general evaluation included general examination, visual acuity, intraocular pressure, slit lamp examination (SLE), slit lamp bio-microscopy (in case of mild media opacity), indirect ophthalmoscopy (in case of mild media opacity) and then B-scan (Occuscan, Alcon, USA) was performed and routine systemic investigations were done where indicated e.g. blood pressure, blood sugar, lipid profile, bleeding time, clotting time, blood complete examination, RA-factor, ANA factor, X-ray chest P/A view, X-ray orbit (in case of intraocular foreign body).

## RESULTS

The patients that required "B-scan" examination had an age range between 6 months to 80 years.

The maximum number of patients 101 (21.8%) had age range between 11 years to 20 years. The minimum number of patients was 5 (1.1%) with age range between 71 years to 80 years.

History of trauma was more common in age range between 11 to 30 years. There were 339 (73.2%) male while 124 (26.8%) were female patients.

Twenty (4.3%) patients had corneal pathology, e.g. traumatic scarring, dystrophy, post viral or bacterial corneal opacity, abscess, or descemetocoele.

Ninety (19.4%) patients had mature cataract while 60 (13%) patients had vitreous hemorrhage; the

patients of retinal detachment were 68 (14.7%), and 51 (11%) had tractional retinal detachment. Four patients (0.9%) had retinoblastoma and 2 (0.4%) had optic nerve anomaly. While 2 patients (0.4%) had choroidal thickening, 2 patients (0.4%) had PHPV.

Asteroid Hyalosis was seen in 1 patient (0.2%). 163 patients (31.2%) had multiple pathologies, in the anterior as well as posterior segment.

## DISCUSSION

Trauma either blunt or penetrating causing corneal, lens, iris, vitreous or retinal damage is common in male patients between age 11–30 years. Because patients in this age range are more active and do outdoor games or activities. This incidence is also common in other published studies<sup>7,8</sup>. The B-scan examination of eyes having mature cataract also aids in cataract surgery<sup>9</sup>. Vitreous hemorrhage is commonly seen in patients with diabetes, hypertension, Eale's disease, traumatic accidents, retinal tear or breaks or idiopathic. If vitreous hemorrhage is in non-resolving stage then vitreo-retinal surgeon is very much concerned to go for vitrectomy and further management that is impossible without prior B-scan ultrasonography. Similarly intraocular foreign bodies also demand immediate B-scan examination especially if the foreign body is of iron, zinc, copper or aluminum because these foreign bodies are very reactive and toxic to photoreceptor cells of retina<sup>10</sup>. But you can delay on B-scan for inert foreign bodies e.g. stone, sand, glass, porcelain, plastic, cilia<sup>10</sup>.

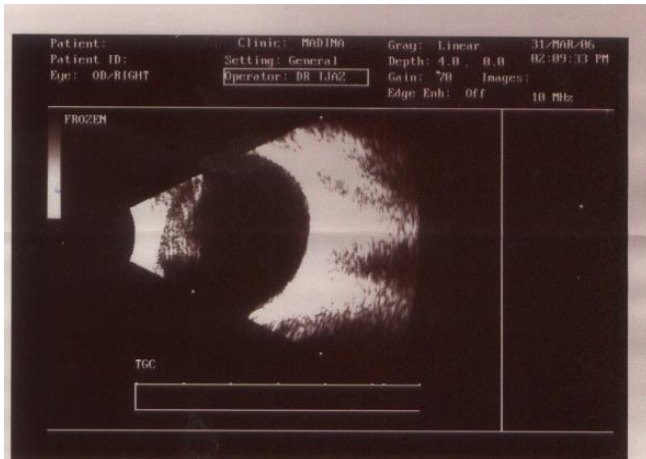
Post traumatic endophthalmitis is commonly seen in penetrating injuries, associated with intra ocular foreign bodies, also in rural setting or in non hospital based eye camps<sup>11</sup>.

## CONCLUSIONS

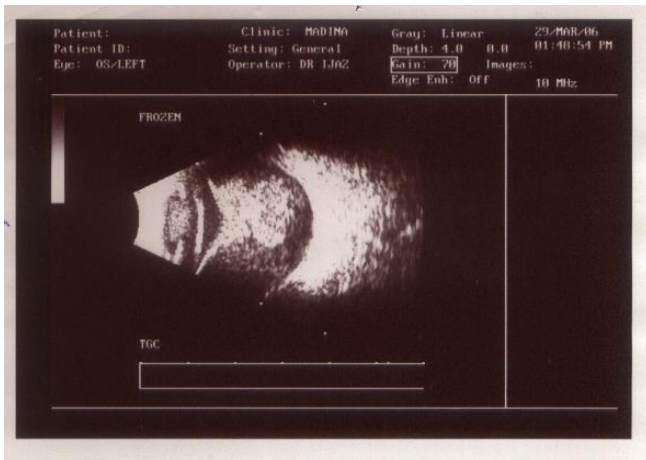
Ultrasonography has developed since 1956 as an essential diagnostic aid<sup>12</sup>. B-scan is an important device for the identification of vitreo-retinal disorders, foreign bodies, intraocular tumors, congested orbital structures. Its results are accurate (90%) in experienced hands. This is comparable to international standards. Recent advances in ultrasound technology permit gray-scale and Doppler scans to be combined.

The therapeutic application of B-scan is being used experimentally to produce filtration operations, to disperse vitreous hemorrhage, and to coagulate

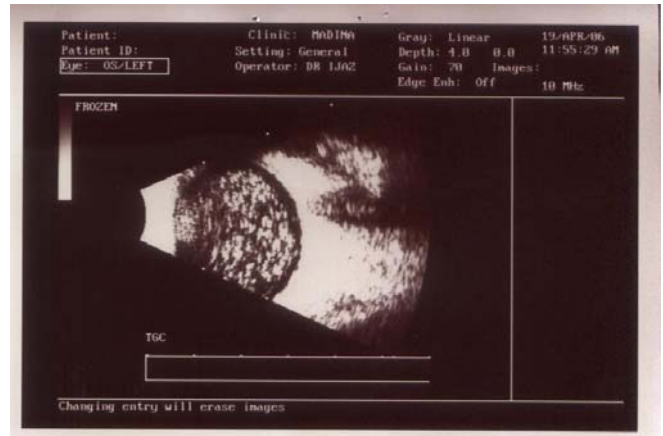tumors in the eye. The fruits of these research efforts should be continually emerging.



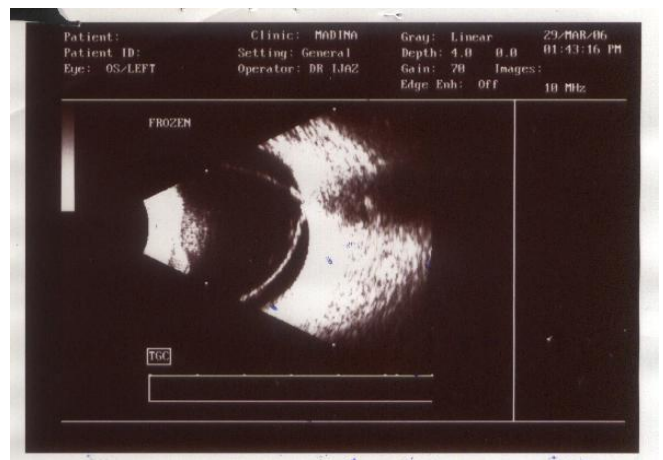
**Fig.** Normal scan of a patient with mature cataract. Scan shows clear vitreous and flat retina, optic nerve shadow is clearly defined.



**Fig.** Retinoblastoma



**Fig.** Asteroid hyalosis



**Fig.** Total retinal detachment.

**Author's affiliation**

Dr. Ejaz Ahmed Javed  
 Consultant Ophthalmologist  
 Madina Medical Centre  
 University Faisalabad, Sargodha Road  
 Faisalabad

Dr. Aamir Ali Ch.  
 Madina Medical Centre  
 University Faisalabad, Sargodha Road  
 Faisalabad

Dr. Iftikhar Ahmad  
 Madina Medical Centre  
 University Faisalabad, Sargodha Road  
 Faisalabad

Dr. Mehmood Hussain  
 Madina Medical Centre  
 University Faisalabad, Sargodha Road  
 Faisalabad

## REFERENCE

1. **Richard L, Hart LJ.** Ultrasound Diagnosis of the eye and orbit; principle and practice of ophthalmology. 1997; 5: 98.
2. **Byrne SF, Green RL.** Ultrasound of the eye and orbit, Louis, Mosby, 1992.
3. **Caroline R, Baum UL;** ophthalmic ultrasonography, ophthalmic secrets, 1998; 38.
4. **Fisher YL.** Diagnostic ophthalmic ultrasonography In Tasmanw. Jaeger EA: Duane's Clinical Ophthalmology.; vol. 2, Philadelphia. JB. Lippin Cott. 1990.
5. **Ossoinig KC.** Quantitative echography. The basis of tissue differentiation. Jclin ultrasound. 1974; 2: 33.
6. **Pavlin CJ, Sherar H. et al.** Clinical use of ultrasound biomicroscopy. Ophthalmology. 1991; 98: 287.
7. **Butt NH, Hye A et al.** Management of fire cracker injuries. Pak J Ophthalmol. 2005; 21: 152.
8. **Avery JG, Jackson RH.** Accidents with fire works. Children and their accidents, London, Edward Arnold. 1993; 81-4.
9. **Bronson NR, Fisher YL, Pickering NC.** Ophthalmic Contact B-scan ultrasonography for the clinician Baltimore Williams & Wilkins. 1980.
10. **Danial J.** American academy of ophthalmology section 12, retina & vitreous; intraocular foreign bodies. 2003; 272.
11. **Danial J.** American academy of ophthalmology section 12 (retina & vitreous) Post operative endophthalmitis. 2003; 274.
12. **Richard L, Dallow and Lois.** Ultrasound Diagnosis of the eye and orbit; principles and practice in ophthalmology. 1997; 3553.

In chronic simple glaucoma with the availability of increasingly effective medical treatment combinations, tendency is towards medical treatment. If it is not effective enough to stop glaucoma damage or cannot be carried out for various other reasons (cost-intolerance, nonavailability etc.) surgery has to be carried out.

**Prof. M Lateef Chaudhry**