

Retinal Artery Macroaneurysm with Hard Exudate

Syed Irshad Haider, Sharif Hashmani, Sadaf shah

Pak J Ophthalmol 2008, Vol. 24 No. 3

.....
See end of article for
authors affiliations

We report a case of retinal artery macroaneurysm with hard exudates diagnosed at Hashmani Hospital, Karachi. Patient was a 60 year old woman with a history of hypertension. She reported to us for visual problems. On dilated fundus examination of right eye, fusiform arteriolar dilatation, central macular exudation, retinal hemorrhage along the superior temporal arcade was found. Retinal macroaneurysm was suspected by history, fundus finding and confirmed by fundus fluorescein angiography findings.

.....
Correspondence to:
Syed Irshad Haider
Hashmanis Hospital
JM-75, Off M.A.Jinnah Road
Jacob line Karachi

Received for publication
February' 2008
.....

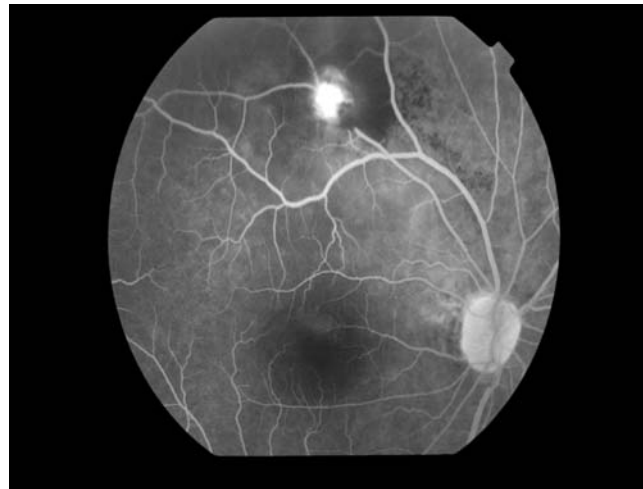
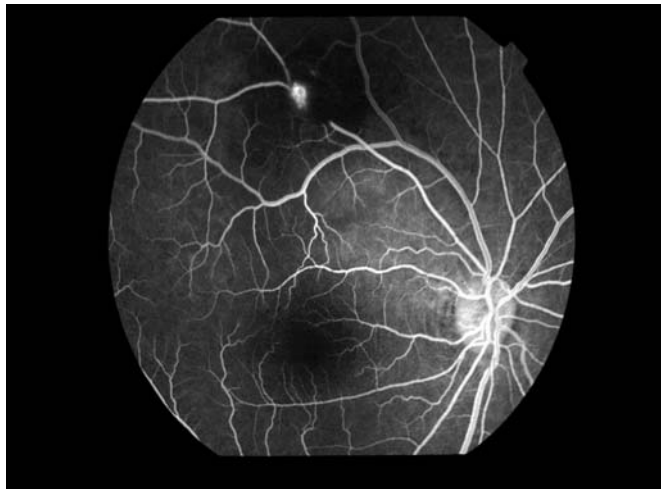
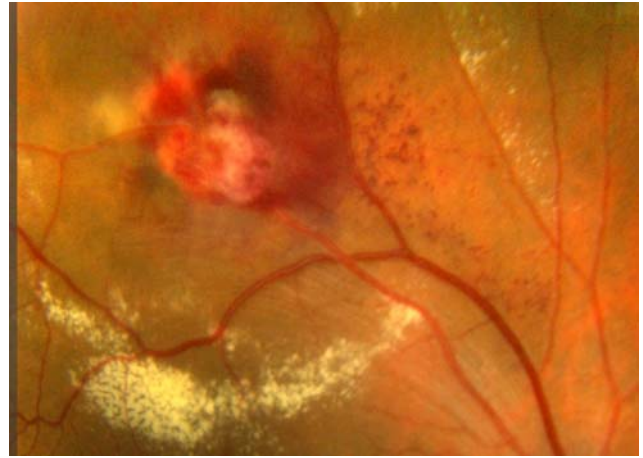
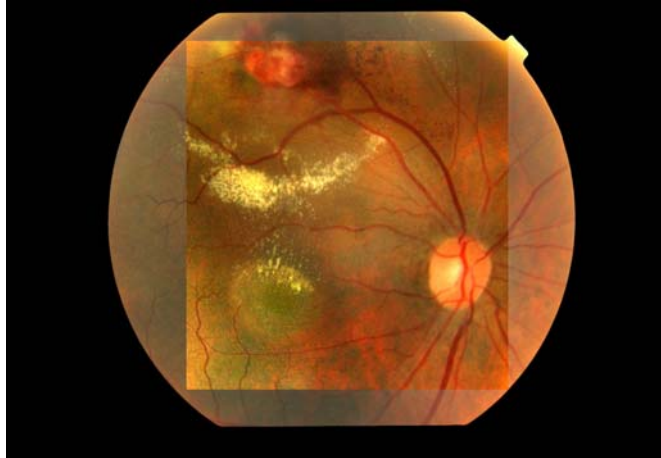
Retinal macroaneurysm is a localized dilatation of a retinal arteriole which usually occurs in the first three orders of the arterial tree. It has a predilection for elderly hypertensive women and involves one eye in 90% of case. Histological findings include macrovascular abnormalities (e.g. widening of the periarteriolar capillary free zone, capillary dilation, nonperfusion, intra-arterial collaterals have been identified. Histological studies of the macroaneurysm show a break in the arterial wall, surrounded by a laminated layer of fibrin-platelet clot and blood. Lipid-laden macrophages, hemosiderin, and fibroglial reaction are also observed. The pathophysiology

formation of retinal macroaneurysm is associated with systemic hypertension in approximately 75% of patients and atherosclerotic disease, but serum lipid abnormalities also have been reported. About 10% of patient has focal arterial wall atheroma occurring at defect in the wall, which may be sites at risk of aneurysm formation. The aneurysm is sites of leakage of exudates and hemorrhage in the macula. Over time or after acute hemorrhage, spontaneous thrombosis and closure of the aneurysm may occur, in some cases, the artery may return to normal.

CASE REPORT

A 60 years old women presented with decreased vision in right eye. There was history of hypertension. On ocular examination the visual acuity (VA) in her right eye was 6/60 while in left eye was 6/12. The right eye was which could not be improved with glasses but left eye VA improved with glasses to 6/9. On silt lamp biomicroscopy examination the anterior segment of both eyes were normal. Intraocular pressure (IOP) was 16mmHg right eye and was 18 mm

Hg left eye. On dilated fundus examination with +90D lens revealed right eye a saccular or fusiform arteriolar dilatation and associated retinal hemorrhage with hard exudation at the macula. The left eye fundus was normal. In fluorescein angiography findings during the venous phase demonstrating delayed filling of the retinal macroaneurysm with fluorescien dye. The aneurysm is obscured partially by the presence of



hemorrhage, but filling by the dye enhance visualization. During late phase showing complete filling of retinal macroaneurysm with late leakage.

DISCUSSION

A retinal macroaneurysm are acquired, dilatation of the large arterioles of the retina. This condition occurs most commonly in the sixth to seventh decade of life. The most common risk factor is hypertension generalized arterial sclerosis, serum lipid abnormal-

ities, vulsalva maneuver. The clinical features of macroaneurysm are impairment of central vision due to macular edema and hard exutadates formation. Sudden visual loss resulting from vitreous hemorrhage is uncommon. On fundus examination a saccular or fusiform arteriolar dilatation, associated with retinal hemorrhage is present in 50% of cases. Chronic leakage resulting in retinal edema with accumulation of hard exudates at the fovea is common and may result in permanent loss of central vision. The

management of retinal macroaneurysms are control hypertension, serum lipids and laser photocoagulation, laser hyaloidotomy.

DIFFERENTIAL DIAGNOSIS:

Hard exudates at the posterior pole

- Background diabetic retinopathy.
- Exudative age-related macular degeneration.
- Exudative telangiectasia.
- Old retinal branch vein occlusion.
- Small retinal capillary haemangioma.
- Radiation retinopathy.

Deep Retinal or Subretinal Hemorrhages at the Posterior Pole.

- Choroidal neovascularization.
- Vulsulva retinopathy.
- Idiopathic polypoidal choroidal vasculopathy.
- Blunt ocular trauma.
- Choroidal melanoma.
- Terson syndrome associated with subarachnoid hemorrhage.

CONCLUSION

The visual prognosis is excellent for many patient. The natural history of macroaneurysm suggests that most close spontaneously with restoration of near normal vision. Chronic macular exudation and hemorrhage can lead to vision loss, which is an indication to consider laser photocoagulation. A study suggest that patient with pre-retinal hemorrhage or vitreous hemorrhage due to retinal macroaneurysms have a good visual prognosis, however, patients with submacular hemorrhage have a poor visual prognosis.

Author's affiliation

Dr. Syed Irshad Haider
Hashmanis Hospital, JM-75, Off M.A.
Jinnah Road, Jacob line Karachi

Dr. Sharif Hashmani
Hashmanis Hospital, JM-75, Off M.A.
Jinnah Road, Jacob line Karachi

Dr. Sadaf Shah
Hashmanis Hospital, JM-75, Off M.A.
Jinnah Road, Jacob line Karachi