

Role of Temporary Tarsorrhaphy Using Super Glue in the Management of Corneal Disorders

Muhammad Moin, Irfan Qayyum, Anwar UI-Haq Ahmad, Mumtaz Hussain

Pak J Ophthalmol 2009, Vol. 25 No. 3

.....
See end of article for
authors affiliations

.....
Correspondence to:
Mohammad Moin
Department of Ophthalmology
Mayo Hospital
Lahore

Purpose: To evaluate the safety and efficacy of temporary tarsorrhaphy using super glue in the management of corneal disorders.

Material and Methods: A retrospective chart review of 46 consecutive patients who underwent superglue tarsorrhaphy from June 1997 to June 1998 was performed. All patients were managed at the Institute of Ophthalmology, Mayo hospital, Lahore. This study included patients with painful non healing corneal ulcers, exposure keratopathy (secondary to moderate proptosis), dry eyes (to reduce surface area of evaporation) and post-operative patients with conjunctival flaps ± scleral grafts (to help take up of the graft). Patients with corneal perforations, endophthalmitis or panophthalmitis were excluded from the study. Temporary tarsorrhaphy was done using super glue technique in which the upper eyelashes were glued to the lower lid skin. The degree of lid closure was calculated according to the pre-existing corneal pathology. Patients were followed up on a weekly basis for one month to check for reduction of pain, improvement of corneal pathology and duration of tarsorrhaphy.

Results: There were 50 eyes of 46 patients included in the study who underwent super glue tarsorrhaphy for various corneal pathologies. There were 36 males and 10 female patients with an average age of 40 years (range 10-60 yrs). Thirty two eyes had keratitis (fungal, bacterial, disciform, dendritic), 5 had a persistent epithelial defect, 4 had exposure keratopathy secondary to moderate proptosis, 5 had conjunctival flap alone or combined with a scleral graft and 4 had dry eyes. In cases of keratitis the tarsorrhaphy remained intact for 2-3 weeks, in patients with proptosis it remained intact for 2 weeks and in cases of dry eyes and conjunctival graft it remained intact for 2-3 weeks. The most common complication seen in the majority of patients was loss of a few lashes after spontaneous opening of the tarsorrhaphy in 2-3 weeks time. Three patients required early opening of the tarsorrhaphy which was done by cutting the eyelashes. No patient had spillage of the glue onto the cornea.

Conclusion: Temporary tarsorrhaphy using super glue technique is a quick, painless and effective outdoor procedure in providing temporary relief in the management of different keratopathies, dry eyes and exposure keratopathy.

Received for publication
January' 2009
.....

Tarsorrhaphy is the fusion of upper and lower eyelid margins. It is one of the safest and most effective procedures for healing the corneal lesions which are usually difficult to treat¹. It can also be performed to protect the cornea from exposure caused by inadequate eyelid coverage, as may occur in Graves's disease or facial nerve dysfunction such as in Bells palsy². It can also be used to aid in healing of

indolent corneal ulceration sometimes seen with tear film deficiency, or 5th nerve dysfunction (neurotrophic lesion).

Tarsorrhaphy may be temporary or permanent. Temporary can be done with sutures³; while in permanent raw tarsal edges are created to form a lasting adhesion. It may be total or partial, depending

on whether only a portion of the palpebral fissure is occluded. Finally, they are classified as lateral, medial or central, according to the location on the eyelid. We analyzed the results of temporary tarsorrhaphy by using superglue (Cyanoacrylate).

MATERIAL AND METHODS

A retrospective chart review of 46 consecutive patients who underwent superglue tarsorrhaphy from June 1997 to June 1998 was performed. All patients were managed at the Institute of Ophthalmology, Mayo hospital, Lahore. Temporary tarsorrhaphy was done using super glue technique. This study included patients with painful non healing corneal ulcers, exposure keratopathy (secondary to moderate proptosis), dry eyes (to reduce surface area of evaporation) and post-operative patients with conjunctival flaps \pm sclera graft (to help take up of the graft). Patients with corneal perforations, endophthalmitis or panophthalmitis were excluded from the study.

A detailed history was taken to document the cause and severity of corneal pathology in each case. Pre-operative examination included best corrected visual acuity (BCVA), a detailed corneal examination for epithelial defect, ulcer or exposure keratopathy, anterior segment examination for hypopyon and measurement of proptosis in selected cases. Patients were followed up on a weekly basis for one month. Post-operative data included grading of pain, changes in corneal pathology (improvement of epithelial defect, ulcer, exposure keratopathy or dry eyes), duration of superglue tarsorrhaphy and documentation of any complications. Pain at presentation was taken as a baseline and following the procedure it was graded as worse, same or improved.

The procedure included instillation of topical proparacaine (Alcaine, Alcon Labs Tx) in the conjunctival sac. This was followed by meticulous drying of the skin and application of super glue (cyanoacrylate) on the lower lid skin beneath the eyelashes. The patient was warned about a feeling of warmth on application of the super glue. Then the patient was asked to close his eyelids tightly. This resulted in adhesion of the eyelashes to the lower lid skin producing an effective tarsorrhaphy. If there was insufficient adhesion of the lashes it could be re-enforced with more superglue. The degree of lid closure was calculated according to the corneal pathology.

RESULTS

There were 50 eyes of 46 patients included in the study who underwent super glue tarsorrhaphy for various corneal pathologies. There were 36 males and 10 female patients with an average age of 40 years (range 10-60 yrs). Forty two patients underwent unilateral tarsorrhaphy while 4 patients had bilateral tarsorrhaphy. Bilateral tarsorrhaphy was done in 2 patients with dry eye and 2 patients with bilateral proptosis. The tarsorrhaphy remained stable for at least 2-3 weeks with spontaneous opening of the lids afterwards.

Out of 50 eyes 32 had infective keratitis (Fig. 1, 2), 5 had a persistent epithelial defect, 4 had exposure keratopathy secondary to moderate proptosis, 5 had conjunctival flap alone or combined with a scleral graft and 4 had dry eyes. Out of the 32 eyes having infective keratitis 10 had fungal keratitis, 15 had bacterial keratitis, 4 had disciform keratitis and 3 had dendritic keratitis. In cases of infective keratitis the tarsorrhaphy was done only after control of active stage of the keratitis. The aim of the treatment was to help in the healing phase of the keratitis. Patients with persistent epithelial defect underwent tarsorrhaphy after having the epithelial defect for at least 5 days. Proptosis was bilateral in 2 cases (thyroid eye disease) while 2 patients had unilateral proptosis (one with orbital inflammatory disease and one post orbitotomy patient). Tarsorrhaphy done in patients with thyroid eye disease was a precursor to permanent procedure to check for its efficacy. It was done in orbital inflammatory disease (OID) and post orbitotomy patients to resolve inferior conjunctival prolapse associated with chemosis (Fig. 3, 4, 5). There were 3 cases of conjunctival flaps done for descematoceles and 2 cases of conjunctival flaps with scleral grafts for perforated corneal ulcers which were done as a last resort to save the shape of the eyeball until a donor cornea was available (Fig. 6, 7). Tarsorrhaphy was done along with the conjunctival procedure to improve its success. The 2 patients with dry eyes underwent this temporary procedure bilaterally to check if decreasing the palpebral fissure with permanent tarsorrhaphy would be of any help to these patients (Fig. 8, 9). In cases of keratitis the tarsorrhaphy remained intact for 2-3 weeks, in patients with proptosis it remained intact for 2 weeks and in cases of dry eyes and conjunctival graft it remained intact for 2-3 weeks.

Eighty four percent of the eyes had relief of pain after the tarsorrhaphy. However, 2 patients had

aggravation of pain after the tarsorrhaphy (patients with keratitis) and 5 patients did not feel any difference after the tarsorrhaphy (4 patients with keratitis and 1 patient with proptosis). There was aggravation of pain in 2 patients with keratitis because the tarsorrhaphy had been done before achieving favorable response to topical medications in order to prevent corneal perforation in very large corneal ulcers with marked central thinning. In these cases the tarsorrhaphy was opened early by cutting the matted eyelashes at the base and treatment changed accordingly.

The most common complication seen in the majority of the patients was loss of a few lashes after spontaneous opening of the tarsorrhaphy in 2-3 weeks time. Three patients required early opening of tarsorrhaphy which was done by cutting the eyelashes. No patient had spillage of the glue onto the cornea.

DISCUSSION

Tarsorrhaphy is a procedure in which the eyelids are fused together to narrow the palpebral fissure. It is one of the safest and most effective procedures for healing persistent epithelial defects or corneal ulceration. Tarsorrhaphy is a more effective therapy than pressure patching in most cases, perhaps because of better oxygen delivery to the ocular surface.

Tarsorrhaphy may be temporary or permanent. Temporary can be done with sutures³; while in permanent raw tarsal edges are created to form a lasting adhesion. They may be total or partial, depending on whether only a portion of the palpebral fissure is occluded. Finally, they are classified lateral, medial or central, according to the position in the palpebral fissure. A lateral tarsorrhaphy is occasionally used to aid in lid closure and corneal coverage in patients who have significant exposure keratitis due to lagophthalmos caused by thyroid ophthalmopathy or any orbital tumour. This is usually performed in conjunction with orbital decompression or lid retraction surgery. A temporary tarsorrhaphy may be performed after these procedures when there continues to be significant symptoms or signs of corneal exposure despite adequate decompression or repair of lid retraction. It is occasionally used as a procedure to mask mild exophthalmos, but it usually stretches because of lid retraction pulling on the adhesions, which is not cosmetically acceptable. Indications of tarsorrhaphy include facial nerve palsy,

non healing corneal ulcer, lagophthalmos, dry eye syndrome, keratitis, kerato-conjunctivitis, proptosis, chemical burn, thyroid ophthalmopathy, impending perforation secondary to trauma, persistent epithelial defect and autoimmune (Steven Johnson Syndrome, Mooren's ulcer)⁴. Botulinum toxin is also used to induce ptosis in some cases. But botulinum toxin may not be available universally because of constraints of cost and expertise. Moreover, the induced ptosis is variable in its onset and duration, and there are risks associated with the injection.

The tarsorrhaphy complications are usually failure of the lid adhesion or a stretching of the lid adhesion. Misdirection of the lashes can occur after a tarsorrhaphy. There are seldom major complications such as hemorrhage or infection. All the forms of surgical tarsorrhaphy are time consuming, and there may be a risk of permanent scarring to the eyelids from surgery. Tarsorrhaphy using superglue technique is another good alternative method for temporary tarsorrhaphy^{5,6,7}.

Advantages of tarsorrhaphy with superglue are that it is easily available, non toxic to skin, can be done in the outpatient clinic, painless, and very cheap as no surgical materials are used. Most frequent complication is temporary loss of eye lashes. Temporary tarsorrhaphy using superglue usually lasts for weeks and can easily be repeated when necessary. With regard to safety, a previous case series has suggested that there is no long-term morbidity from superglue contact with the eye. The technique is not a replacement for surgical tarsorrhaphy; however, it may be considered as an alternative in certain situations. First, the technique can be used to provide short-term corneal protection prior to recovery of facial nerve palsy. Second, it may serve as a temporary measure for exposure keratopathy while awaiting more definitive treatment. Third, it is of value in patients who refuse surgical intervention.

Cyanoacrylate was discovered by Harry Coover at Eastman Kodak during World War II when searching for a way to make plastic gun-sight lenses. It did not solve this problem, since it stuck to all the apparatus used to handle it. It was first marketed for industrial and domestic use in February 1955 as a product called "Flash Glue" which is still available today and now owned by Gary Shipko, president of Super Glue International, a United States based firm. It was patented in 1956 and developed into *Eastman 910* adhesive in 1958. Cyanoacrylates are now a family of adhesives based on similar chemistry.

Fig. 1: Fungal keratitis

Fig. 4: After superglue tarsorrhaphy

Fig. 2: After superglue tarsorrhaphy

Fig. 5: After opening of tarsorrhaphy

Fig. 3: Proptosis with chemosis (old)

Fig. 6: Conjunctival flap + scleral graft

Fig. 7: After superglue tarsorrhaphy

Table 1:

Disease	No. of Eyes
Infective Keratitis (Fungal, Bacterial Disciform, Dendritic)	32
Persistent epithelial Defect	5
Exposure keratopathy due to proptosis	4
Conjunctival Flap ± sclera graft	5
Dry Eyes (Steven Johnson syndrome)	4

Table 2:

Disease	Duration of Tarsorrhaphy	Repeat Tarsorrhaphy
Infective Keratitis	2-3 wks	2 cases
Exposure keratopathy due to proptosis	2 wks	None
Conjunctival Flap ± sclera graft	2-3 wks	None
Dry Eyes (Steven Johnson syndrome)	2-3 wks	None
Infective Keratitis	2-3 wks	2 cases

Fig. 8: Severe dry eyes post SJ syndrome

Table 3:

Disease	> Pain	<>pain	< Pain
Keratitis(Fungal, Bacterial, Disciform, Dendritic)	2	4	26
Epithelial Defect			5
Exposure keratopathy due to proptosis		1	3
Conjunctival flap ± sclera graft			5
Dry Eyes (Steven Johnson syndrome)			4
Total	2	5	43

Fig. 9: After bilateral tarsorrhaphy

The use of cyanoacrylate glues in medicine was considered fairly early on. Eastman Kodak and Ethicon began studying whether the glues could be used to hold human tissue together after surgery. In 1964, Eastman submitted an application to use cyanoacrylate glues to seal wounds to the United States Food and Drug Administration (FDA). Soon

afterwards in 1966, cyanoacrylates were tested on-site in Vietnam by a specially trained surgical team, with impressive results. The compound demonstrated an excellent capacity to stop bleeding, and during the Vietnam War, disposable cyanoacrylate sprays were developed for use in the battlefield.

The original Eastman formula was not FDA approved for medical use, however, because of a tendency to cause skin irritation and to generate heat. In 1998 the FDA approved 2-octyl cyanoacrylate for use in closing wounds and surgical incisions. Closure Medical has developed medical cyanoacrylates such as Derma bond, Soothe-N-Seal and Band-Aid Liquid Adhesive Bandage. Since we did not have an open wound there was no skin irritation seen with cyanoacrylate in our study.

In its liquid form, cyanoacrylate consists of monomers of cyanoacrylate molecules. Methyl-2-cyanoacrylate ($\text{CH}_2=\text{C}(\text{CN})\text{COOCH}_3$ or $\text{C}_5\text{H}_5\text{NO}_2$) has a molecular weight equal to 111.1, a flashpoint of 79 °C, and 1.1 times the density of water. Ethyl-2-cyanoacrylate ($\text{C}_6\text{H}_7\text{NO}_2$) has a molecular weight equal to 125 and a flashpoint of >75°C. To facilitate easy handling, adhesives made with cyanoacrylate are usually formulated so that the glue is more viscous and gel-like.

Generally, cyanoacrylate is an acrylic resin which rapidly polymerizes in the presence of water (specifically hydroxide ions), forming long, strong chains, joining the bonded surfaces together. Because the presence of moisture causes the glue to set, exposure to moisture in the air can cause a tube or bottle of glue to become unusable over time. To prevent an opened container of glue from setting before use, it must be stored in an airtight jar or bottle with a package of silica gel. 2-octyl cyanoacrylate can also be used for small skin cuts/lid tears⁸, small corneal tears, small corneal perforations, 360° fornix formation.

CONCLUSION

Temporary tarsorrhaphy using super glue technique is a quick and effective outdoor procedure. It is a very

effective and safe procedure in the management of non-healing epithelial defects and other surface problems, with a very high success rate and only minor complications.

Author's affiliation

Dr. Muhammad Moin
Associate Professor
Department of Ophthalmology
Mayo Hospital
Lahore

Dr. Irfan Qayyum
Department of Ophthalmology
King Edward Medical University
Mayo Hospital
Lahore

Dr. Anwar Ul-Haq Ahmad
Department of Ophthalmology
King Edward Medical University
Mayo Hospital
Lahore

Prof. Mumtaz Hussain
Department of Ophthalmology
Mayo Hospital
Lahore

REFERENCE

1. **Cosar CB, Cohen EJ, Rapuano CJ, et al.** Tarsorrhaphy: clinical experience from a cornea practice. *Cornea*. 2001; 20: 787-91.
2. **Bergeron CM, Moe KS.** The evaluation and treatment of upper eyelid paralysis. *Facial Plast Surg*. 2008; 24: 220-30.
3. **McInnes AW, Burroughs JR, Anderson RL.** Temporary suture tarsorrhaphy. *Am J Ophthalmol*. 2006; 142: 344-6.
4. **Tzelikis PF, Diniz CM, Tanure MA et al.** Tarsorrhaphy: applications in a Cornea Service. *Arq Bras Oftalmol*. 2005; 68: 103-7.
5. **Ehrenhaus M, D'Arienzo P.** Improved technique for temporary tarsorrhaphy with a new cyanoacrylate gel. *Arch Ophthalmol*. 2003; 121: 1336-7.
6. **Leahey AB, Gottsch JD, Stark WJ.** Clinical experience with N-butyl cyanoacrylate (Nexacryl) tissue adhesive. *Ophthalmology*. 1993; 100: 173-80.
7. **Donnenfeld ED, Perry HD, Nelson DB.** Cyanoacrylate temporary tarsorrhaphy in the management of corneal epithelial defects. *Ophthalmic Surg*. 1991; 22: 591-3.
8. **Singer AJ, Quinn JV, Hollander JE.** The cyanoacrylate topical skin adhesives. *Am J Emerg Med*. 2008; 26: 490-6.

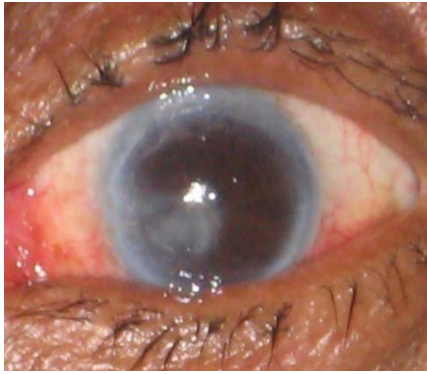


Fig 1. Fungal keratitis

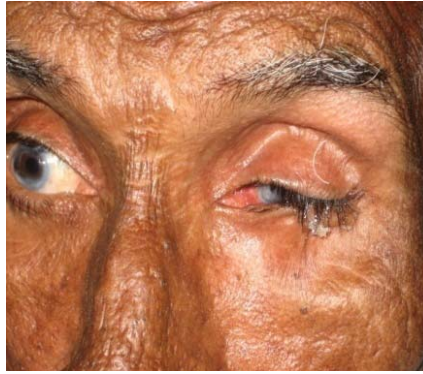

Fig 2. After superglue tarsorrhaphy

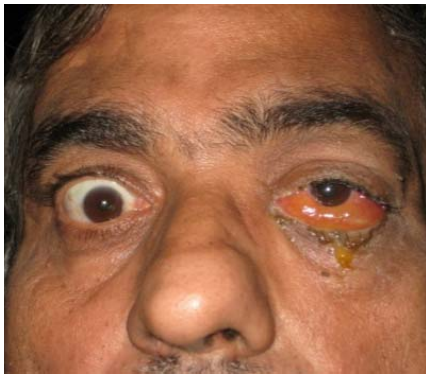

Fig 3. Proptosis with chemosis (OID)

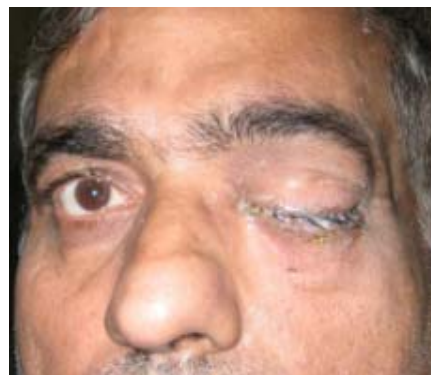

Fig 4. After superglue tarsorrhaphy

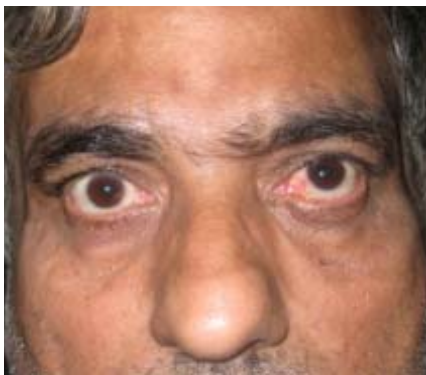

Fig 5. After opening of tarsorrhaphy

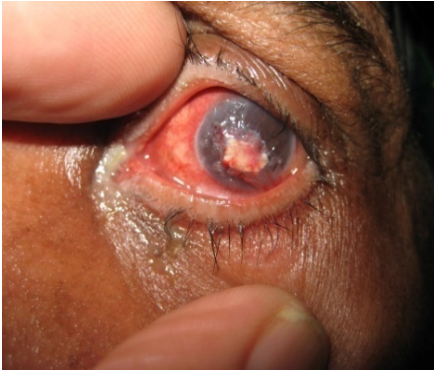

Fig 6. Conjunctival flap + scleral graft

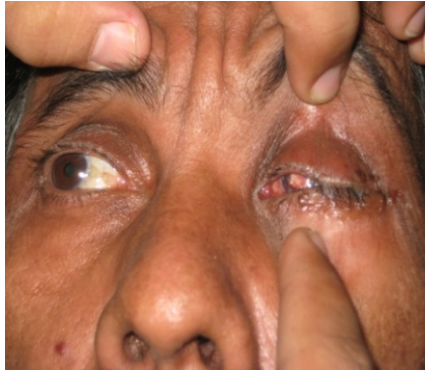

Fig 7. After superglue tarsorrhaphy

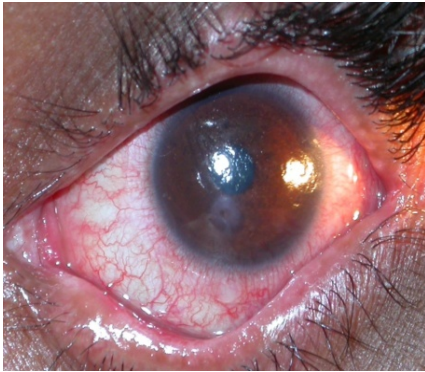

Fig 8. Severe dry eyes post SJ syndrome

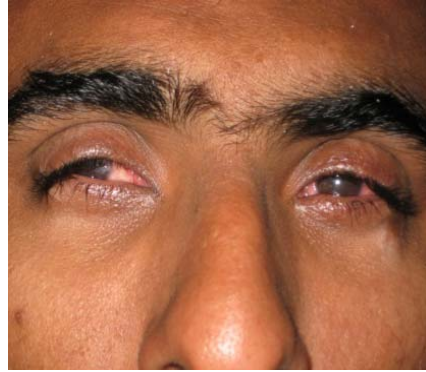

Fig 9. After bilateral tarsorrhaphy