

# Tear TNF- $\alpha$ , IL-1 $\alpha$ , and IL-6 Levels in Patients with Active Trachoma

Ahmet Satıcı, Mustafa Guzey

Pak J Ophthalmol 2009, Vol. 25 No. 3

See end of article for authors affiliations

Correspondence to:  
Ahmet Satıcı  
Department of Ophthalmology  
Harran University, School of  
Medicine, Sanliurfa  
Turkey

Received for publication  
January 2009

**Purpose:** Tear TNF- $\alpha$ , IL-1 $\alpha$ , and IL-6 levels were investigated in patients with active trachoma.

**Material and Methods:** Fifteen eyes of 15 patients with active trachoma were included in this study. Active trachoma was diagnosed using fluorescent monoclonal antibody test kit. Fifteen eyes of 15 age-matched, healthy subjects were used as controls. Tear fluid samples were obtained from the conjunctival cul-de-sac by means of blunted-tip glass capillary tubes. Reflex tears from patients with active trachoma and normal subjects were collected by stimulating the nasolacrimal reflex with by a cotton-tipped applicator. The levels of cytokine in tears were measured ELISA.

**Results:** The tear levels of TNF- $\alpha$ , IL-1 $\alpha$ , and IL-6 were determined to be higher in the patients with active trachoma than in the control subjects ( $p=0.049$ ), ( $p=0.000$ ), ( $p=0.003$ ), respectively.

**Conclusion:** The data suggest that TNF- $\alpha$  and IL-1 $\alpha$  with its regulatory cytokine IL-6 may play a role in trachoma. In conclusion, levels of the certain cytokine in tears to reflect inflammation in active trachoma.

Trachoma is a chronic ocular disease caused by Chlamydia trachomatis. In most patients with mild trachoma, it may heal without permanent visual loss, but in patients with severe chronic trachoma it may progress and cause serious damage of the ocular surface. Severe inflammatory trachoma is felt to be a marker for subsequent severe scarring<sup>1,2</sup>. The pathogenic mechanisms in trachoma are not well understood. Various immunologic mechanisms may give rise to trachomatous inflammation. Certain cytokines such as IL-6 could trigger or maintain the inflammatory immune response seen in trachomatous conjunctivitis<sup>2</sup>. Understanding the exact mechanisms involved in the pathogenesis of trachoma is important for future therapeutic approaches<sup>3</sup>.

In patients with active trachoma, both the epithelial and subepithelial layers of the conjunctiva are seen to be infiltrated with mononuclear and polymorphonuclear leukocytes, macrophages, and B and T lymphocytes. The pathogenesis of trachoma involves the recruitment of inflammatory cells to the

conjunctiva where they participate in a local inflammatory response producing severe tissue damage. Immunohistochemical studies have demonstrated that B and T cells that are stimulated by chlamydial antigens lead to the induction of reaction to tissue damage<sup>2</sup>.

Still endemic in many developing countries, trachoma is a common clinical problem in the Southeastern region of Turkey<sup>4</sup>. Long regarded as a standard in the laboratory confirmed diagnosis of trachoma, direct immunofluorescence assay staining is a simple, quick, and extremely trustworthy technique for detecting chlamydial infections. Previous studies have found direct immunofluorescence assay staining results to be more sensitive than those of culture<sup>5,6</sup>. Therefore, we decided to use this method in the determination of active trachoma.

In this study, we chose to investigate tear TNF- $\alpha$ , IL-1 $\alpha$ , and IL-6 levels in patients with active trachoma because TNF- $\alpha$  and IL-1 are considered primary

cytokines and they initiate a cascade of events integral to the inflammatory process. They also induce the production of secondary cytokines such as IL-6<sup>7</sup>. This is the first study in which tear cytokine levels have been detected in patients with active trachoma.

## MATERIAL AND METHODS

Fifteen eyes of 15 patients with active trachoma were included in this study. Patients complicated by infections or inflammations in addition to trachoma were excluded from the study. Active trachoma was diagnosed with a fluorescent monoclonal antibody test kit for the direct staining of *C. trachomatis* (Cellabs, Australia). Ocular specimens for chlamydial tests were taken from the upper tarsal conjunctiva after instillation of local anaesthetic. Specimens were processed according to the manufacturer's instructions. Slides were read on a fluorescence microscope (E 800 Nikon, Japan). A specimen was considered positive for *C. trachomatis* if three or more typical elementary bodies were identified<sup>8</sup>. In addition laboratory examination was performed on bacterial cultures (blood agar, thioglycolate broth, chocolate agar by Gram's stain and Giemsa stain.

The control group consisted of fifteen eyes of 15 age-matched healthy subjects with no evidence of inflammatory eye disease no symptoms of ocular irritation and no history of eye disease or surgery, or use of contact lenses or ocular medication. All control subjects had negative results in the direct staining of *Chlamydia trachomatis*. Informed consent was obtained after the nature and possible consequences of the study were explained.

Tear fluid samples were collected atraumatically from the conjunctival cul-de-sac by means of blunted-tip glass capillary tubes. Care was taken to avoid touching the ocular surface. Reflex tears from patients with active trachoma and normal subjects were collected by stimulating the nasolacrimal reflex with a cotton-tipped applicator. The amount of tears collected was about 150 µl from each eye. The obtained samples were immediately stored at -70<sup>o</sup> C within plastic tubes until assay.

### Immunoassays

The tear fluid cytokine levels were determined by ELISA. Measurements of TNF- $\alpha$ , IL-1 $\alpha$ , and IL-6 in tear samples were carried out with a commercially available kit (PeliKine, Amsterdam, The Netherlands). All tests were performed according to the manufacturers' recommended protocol. If the tear

fluid samples were not of adequate volume, they were diluted. The samples were analyzed in duplicate. The minimum detectable concentrations for the assay kits were 1 pg/ml, 2 pg/ml and 1 pg/ml for TNF- $\alpha$ , IL-1 $\alpha$  and IL-6, respectively.

### Statistical analysis

Statistical analysis of data was performed by the Paired t test.

## RESULTS

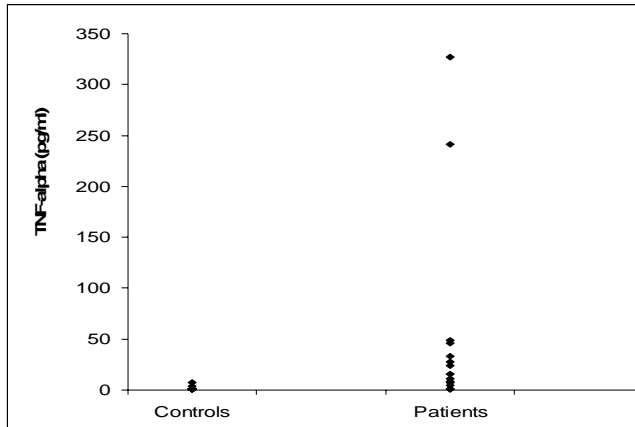
The patients with active trachoma had a mean age of 9.4 $\pm$ 5.7 years and comprised both sexes (8 females and 7 males). The normal subjects had a mean age of 10.8 $\pm$ 4.9 years and also comprised both sexes (8 females and 7 males). In this study, tear TNF- $\alpha$  levels were found to be significantly higher in patients with active trachoma than in control subjects ( $t=-2.160$ ,  $p=0.049$ ). While detectable tear TNF- $\alpha$  levels were found in 80.0% of patients with active trachoma, they were found in only 13.3% of control subjects. There appeared to be a wider range of tear TNF- $\alpha$  levels than in controls (Fig. 1).

The tear IL-1 $\alpha$  concentrations were found to be higher in patients with active trachoma than control subjects ( $t=-5.466$ ,  $p=0.000$ ). Tear IL-1 $\alpha$  levels were five times higher in the patients with active trachoma group than the control group (Table 1). While IL-1 $\alpha$  levels were 9.6 $\pm$ 3.5 pg/ml in control subjects, there were 48.5 $\pm$ 27.8 pg/ml in patients with active trachoma (Fig. 2).

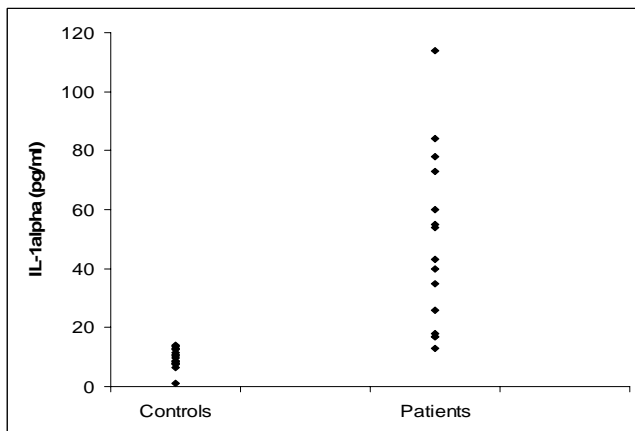
**Table 1:** Tear TNF- $\alpha$ , IL-1 $\alpha$  and IL-6 levels in patients with active trachoma and control subjects (mean  $\pm$  SD).

|                               | TNF- $\alpha$<br>(pg/ml) | IL-1 $\alpha$<br>(pg/ml) | IL-6<br>(pg/ml)   |
|-------------------------------|--------------------------|--------------------------|-------------------|
| Control subjects              | 1.1 $\pm$ 2.9            | 9.6 $\pm$ 3.5            | 11.4 $\pm$ 2.2    |
| Patients with active trachoma | 53.2 $\pm$ 96.4          | 48.5 $\pm$ 27.8          | 109.6 $\pm$ 104.8 |

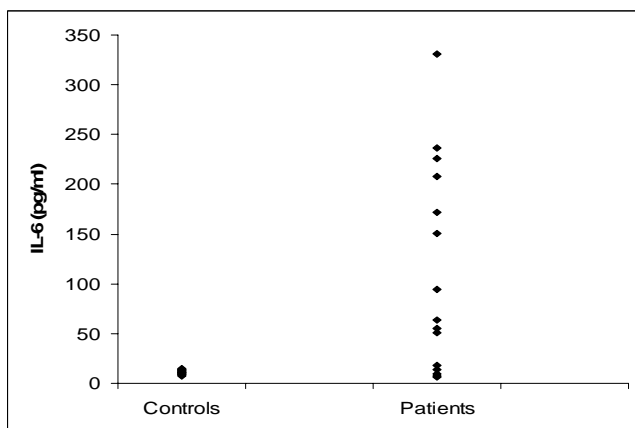
Higher IL-6 levels were detected in the tears of patients with active trachoma than the controls ( $t=-3.628$ ,  $p=0.003$ ). Tear IL-6 levels were ten times higher in patients with active trachoma than in controls (Table 1) (Fig. 3).



**Fig. 1.** Tear TNF- $\alpha$  levels in patients with active trachoma and control subjects.



**Fig. 2.** Tear IL-1 $\alpha$  levels in patients with active trachoma and control subjects.



**Fig. 3:** Tear IL-6 levels in patients with active trachoma and control subjects

## DISCUSSION

Cytokines produced by the immune system cells as a result of an immune response induced by viral or bacterial infection may play an important role in the inflammatory process<sup>9</sup>. The inflammatory response is caused by microorganisms, accompanied by the infiltration of polymorphonuclear leukocytes, macrophages and lymphocytes.

TNF- $\alpha$  is known to play an important role as primary mediator in the pathogenesis of inflammation. It is secreted mainly by activated monocytes/macrophages. Our results showed that the levels of TNF- $\alpha$  were higher in the tears of patients with active trachoma than in controls. The source of the high levels of TNF- $\alpha$  determined in the tears of active trachoma patients may be inflammatory cells to collect on the ocular surface.

TNF- $\alpha$  also triggers the in vivo and in vitro production of cytokines such as IL-1 and IL-6<sup>9</sup>. IL-1 is produced mainly by activated macrophages and neutrophils, but other cells such as conjunctival epithelial cells and B and T cells are capable of IL-1 synthesis as well IL-1 plays a variety of roles in the pathogenesis of many diseases. IL-1 cannot on its own cause tissue damage, but it can potentialize the damage caused by TNF- $\alpha$ . IL-1 and TNF- $\alpha$  induce the release of secondary cytokines such as IL-6<sup>10</sup>.

In this study we determined that tear levels of IL-1 $\alpha$  were higher in patients with active trachoma than in healthy subjects. Although IL-1 $\alpha$  is secreted by a number of cells, the increased levels determined in trachoma patients may have been caused by macrophages, neutrophils or lymphocytes infiltrating the conjunctiva, and or increased tear TNF- $\alpha$  levels. IL-6 is synthesized and released mainly by monocytes and macrophages in response to inflammatory stimuli. It is secondary to TNF- $\alpha$  and IL-1 production, but other cells for example, T and B lymphocytes may also produce it. IL-6, like IL-1 and TNF- $\alpha$  serves as an important immune mediator in inflammatory and immunologic processes. IL-6 acts as a signal in T cell activation, induces antibody secretion by B cells, and induces differentiation of cytotoxic T cells. TNF- $\alpha$ , IL-1, and IL-6 can exert synergistic effects in acute pathologic changes, including cellular infiltration<sup>10</sup>. Increased tear IL-6 levels are reported in many ocular inflammatory conditions.

IL-6 levels in the tears of patients with active trachoma were found to be significantly higher than in controls. The high IL-6 levels determined in patients

tears may have been caused by inflammatory cells infiltrating the area of inflammation and/or by increased tear TNF- $\alpha$  and IL-1 levels.

TNF- $\alpha$ , IL-1 and IL-6 are inflammatory cytokines playing a role in inflammatory process. In this study elevated tear TNF- $\alpha$ , IL-1 $\alpha$  and IL-6 levels were demonstrated in patients with active trachoma. These data suggest that TNF- $\alpha$  and IL-1 along with its regulatory cytokine IL-6, may play a role in the inflammatory processes of trachoma. Immunologic events occurring on the ocular surface due to chronic chlamydial infection may lead to blindness<sup>11,12</sup>.

Increased knowledge about trachoma will contribute to eradication blindness caused by this disease. These finding suggest that TNF- $\alpha$  and IL-1 may play important roles in the pathogenesis of trachoma, that it is worthwhile to investigate the role of cytokines in the pathogenesis of trachoma, and that further studies are necessary in order to better understand the inflammatory process in trachoma and identify the cellular sources of the cytokines found in high levels in the tears of trachoma patients.

#### **Author's affiliation**

Ahmet Satici  
Department of Ophthalmology  
Harran University  
School of Medicine Sanliurfa  
Turkey

Mustafa Guzey  
Department of Ophthalmology  
Harran University  
School of Medicine Sanliurfa  
Turkey

#### **REFERENCE**

1. **West SK, Munoz B, Lynch M, et al.** Risk factors for constant, severe trachoma among preschool children in Kongwa, Tanzania. *Am J Epidemiol.* 1996; 143: 73-8.
2. **Tabbara KF.** Chlamydia: Trachoma and inclusion conjunctivitis. In: Tabbara KF, Hyndiuk RA, editors. *Infections of the eye.* 2<sup>nd</sup> ed. Little, Brown Co: New York. 1996; 433-51.
3. **Conway DJ, Holland MJ, Bailey RL, et al.** Scarring trachoma is associated with polymorphism in the tumor necrosis factor alpha (TNF- $\alpha$ ) gene promoter and with elevated TNF- $\alpha$  levels in tear fluid. *Infect Immun.* 1997; 65: 1003-6.
4. **Negrel AD, Minassian DC, Sayek F.** Blindness and low vision in southeast Turkey. *Ophthalmic Epidemiol.* 1996; 3: 127-34.
5. **Schachter J, Sweet RL, Grossman M, et al.** Experience with the routine use of erythromycin for chlamydial infections in pregnancy. *N Eng J Med.* 1986; 314: 276-9.
6. **Preece PM, Anderson JM, Thompson RG.** Chlamydia trachomatis infection in infants: A prospective study. *Arch Dis Child.* 1989; 64: 525-9.
7. **Leonardi A, Borghesan F, DePaoli M, et al.** Procollagens and inflammatory cytokine concentrations in tarsal and limbal vernal keratoconjunctivitis. *Exp Eye Res.* 1998; 67: 105-12.
8. **Carta F, Zanetti S, Pinna A, et al.** The treatment and follow up of adult chlamydial ophthalmia. *Br J Ophthalmol.* 1994;78: 06-8.
9. **de Vos AF, Klaren VNA, Kijlstra A.** Expression of multiple cytokines and IL-1ra in the uvea and retina during endotoxin-induced uveitis in the rat. *Invest Ophthalmol Vis Sci.* 1994; 35: 3873-83.
10. **Boisjoly H, Laplante C, Bernatchez SF, et al.** Effects of EGF, IL-1 and their combination on in vitro corneal epithelial wound closure and cell chemotaxis. *Exp Eye Res.* 1993; 57: 293-300.
11. **Young E, Taylor HR.** Immune mechanisms in Chlamydial eye infection. *Invest Ophthalmol Vis Sci.* 1986; 27: 615-9.
12. **Taylor HR, Rapoza PA, West S, et al.** The epidemiology of infection in trachoma. *Invest Ophthalmol Vis Sci.* 1989; 30: 1823-31