

# Neodymium: Yag Laser Capsulotomy Rates Following Implantation of Silicone and Acrylic Intraocular Lenses

Muhammad Kashif Hanif, Syed Abid Hassan Naqvi, Uzma Ansari, Haseeb Ahmed Khan, Muhammad Kamran Saeed

*Pak J Ophthalmol 2009, Vol. 25 No. 4*

See end of article for authors affiliations

Correspondence to:  
Muhammad Kashif Hanif  
Classified Eye Specialist  
CMH Malir,  
Karachi

Received for publication  
January' 2009

**Purpose.** The objective of this study is to compare the frequency of Neodymium YAG laser capsulotomy in eyes receiving silicon foldable posterior chamber intraocular lenses with those receiving acrylic foldable posterior chamber intraocular lenses.

**Material and Methods.** This Comparative study was carried out at Ophthalmology Department C.M.H. Karachi from August 2007 to August 2008.

Sixty patients were included in this study. Thirty patients were included in-group A who opted for acrylic foldable IOLs and thirty patients in group B who opted for Silicon foldable IOLs. All the patients underwent phacoemulsification procedure with 3.2mm clean corneal self-sealing incision. Then they were followed for one year. During follow up on each visit visual acuity was taken, slit lamp examination was performed for posterior capsular opacification and cases selected for Nd YAG laser capsulotomy having posterior capsular opacification sufficient to cause decrease in visual acuity more than 2 lines. Chi-square test was used to calculate frequency of YAG laser capsulotomy in both groups.

**Results.** In group A one patient was diagnosed as having clinically significant posterior capsular opacification (PCO) enough to reduce visual acuity of two lines (snellen chart) requiring Nd: YAG laser capsulotomy at the end of one year and in Group B three patients were diagnosed as having clinically significant posterior capsular opacification (PCO) enough to reduce visual acuity of two lines (snellen chart) requiring Nd:YAG laser capsulotomy at the end of one year.

**Conclusion.** PCO and frequency of Nd: YAG laser capsulotomy was more common in eyes receiving silicone IOLs than eyes receiving acrylic IOLs.

Posterior capsule opacification (PCO) following cataract surgery is the manifestation of migration and proliferation of lens epithelial cells onto the central region of the posterior capsule<sup>1</sup>. Posterior capsular opacification (PCO) is the commonest complication of cataract surgery with a frequency of between 10% and 50% by 2 years postoperatively<sup>2</sup> and the rate seems to have remained unchanged over the recent years<sup>3</sup>.

Early posterior capsular opacification seems to be multi-factorial in origin<sup>4</sup>. At surgery it is physically

impossible to remove all lens epithelial cells from the capsular bag; those that remain proliferate and undergo metaplasia. In an aphakic eye, they cover the posterior capsule after surgery and can be thought of conceptually as the normal wound healing response<sup>5</sup>. This causes reduction of visual acuity and the need for intervention once again at the hospital level that may be disturbing, especially for the elderly.

In view of these problems, there is now considerable interest in strategies to reduce PCO. The presence of a posterior chamber intraocular lens (IOL)

in the capsular bag has been known to reduce the risk of PCO development<sup>6-9</sup>, probably by acting as a mechanical barrier against the migration of proliferating lens epithelial cells on the posterior capsule<sup>2, 6-10</sup>, and/or minimizing capsule wrinkling and limiting the space available for lentoid formation.<sup>11</sup> These effects are thought to be enhanced when an IOL has more contact with the posterior capsule<sup>1</sup>. Experimental and clinical studies have shown that polishing of posterior capsule during surgery, and a sharp optic edge can prevent the invasion of lens epithelial cells into the retrolental space, may lead to less PCO<sup>12-16</sup>. Small (4.5 to 5.0 mm) capsulorhexis and capsular bag implantation of 5.5 mm acrylic IOL are likely to reduce the PCO incidence when compared with the 6.0 to 7.0 mm capsulorhexis<sup>17</sup>. Nd: YAG laser capsulotomy is a method of choice to treat this complication<sup>18</sup>.

This study has been planned to find out the frequency of Neodymium YAG laser capsulotomy after phacoemulsification with implantation of acrylic and silicone foldable posterior chamber intraocular lenses. Hence, we will be able to find out a way to reduce the chances of development of posterior capsular opacification and decrease the number of patients coming again to hospital for treatment.

## MATERIAL AND METHODS

Sixty eyes of 60 patients scheduled to have IOL implantation were initially randomized into 2 groups based on IOL type: silicone, and acrylic. Of the 60 eyes, 60 completed the follow-up. The PCO density in these eyes was measured 1 week, 1 month, 11/2, 2,4,6,9 and 12 months postoperatively. Visual acuity and the frequency of Nd: YAG laser capsulotomy was examined. It was a hospital based comparative study. Sixty patients were selected from the outpatient department on the basis of non-probability convenience sampling who fulfilled the inclusion and exclusion criteria. Written consent was obtained. Chi-square test was used to calculate frequency of YAG laser capsulotomy in both groups.

All surgery was performed between August 2007 and August 2008. Tight inclusion criteria were used to define the presence of senile cataract in otherwise normal eye in-patients over 50 years of age. Exclusion criteria were a history of previous intraocular surgery or laser treatment, diabetes mellitus requiring medical control, glaucoma, previous uveitis, or any posterior

segment pathology precluding a postoperative vision of 6/12 or better. Patients using topical medications (apart from lubricants) and any patients taking systemic steroids were excluded. All patients were assessed preoperatively and postoperatively by the same person. Visual acuity was taken, slit lamp examination was performed for posterior capsular opacification and cases selected for Nd YAG laser capsulotomy having posterior capsular opacification sufficient to cause decrease in visual acuity more than 2 lines. A written informed consent was obtained from each patient and then these were randomly divided into group A having foldable acrylic implant or group B having Silicon foldable IOLs.

Surgical technique and medication were standardized. 3.2mm clean corneal self sealing incision with continuous curvilinear capsulorhexis measuring approximately 5.5mm in diameter was performed by a single surgeon using peribulbar anesthesia. After hydrodissection, endocapsular phacoemulsification of the nucleus and aspiration of the residual cortex were performed. The capsule was inflated with viscoelastic substance, after which the IOL was placed into the capsular bag using intraocular lens injector. After capsular polishing, the viscoelastic material was washed and wound was secured by hydro tamponade tested for leakage by gentle compression with sponge. All surgeries were uneventful and the IOLs were accurately placed in the capsular bag. AcrySof is a proprietary copolymer of phenyl ethyl acrylate and phenyl ethyl methacrylate cross linked with 1.4 butanediol diacrylate. The angle of flexion of the haptics was 10 degrees with the polyacrylic lenses and 5 degrees for silicone. Healon was thoroughly removed by irrigation with BSS. Subconjunctival cefuroxime 125 mg was given at the end of the operation. Any surgical complications such as capsulorhexis rim tear, zonular dehiscence, and failure to place the IOL into the capsular bag, posterior capsular rupture, or vitreous loss led to patient exclusion. Postoperatively all patients used antibiotic steroid combination drops four times a day for 02 months. No non-steroidal anti-inflammatory preparation was used pre-, peri-, or postoperatively. During follow up, on each visit visual acuity was taken and slit lamp examination was performed for posterior capsular opacification and cases were selected for Nd YAG laser capsulotomy having posterior capsular opacification sufficient to cause decrease in visual acuity by more than 2 Snellen's lines.

**Table 1:** Frequency of Nd Yag Laser Capsulotomy After Cataract Surgery in Acrylic Vs. Silicon Foldable IOL

Types of IOL	Number of patients developing PCO	Number of patients developing requiring Nd;YAG	%Age of patients
Acrylic foldable IOLs	01	01	3.33%
Silicone foldable IOLs	03	03	10%

**Table 2.** Gender Distribution

GENDER	Acrylic foldable IOL	Silicone foldable IOL	No. of patients	%Age of patients
Male	24	24	48	80%
Female	6	6	12	20%

**Table 3.** Chi-Square Tests

	Value	df	Asymp. Sig. (2-sided)	Exact Sig. (2-sided)	Exact sig. (1-sided)
Pearson Chi-Square	1.071b	1	.301		
Continuity Correction <sup>a</sup>	.268	1	.605		
Likelihood Ratio	1.118	1	.290		
Fisher's Exact Test				.612	.306
N of Valid Cases	60				

a. Computed only for a 2x2 table

b. 2 cells (50.0%) have expected count less than 5. The minimum expected count is 2.005

## RESULTS

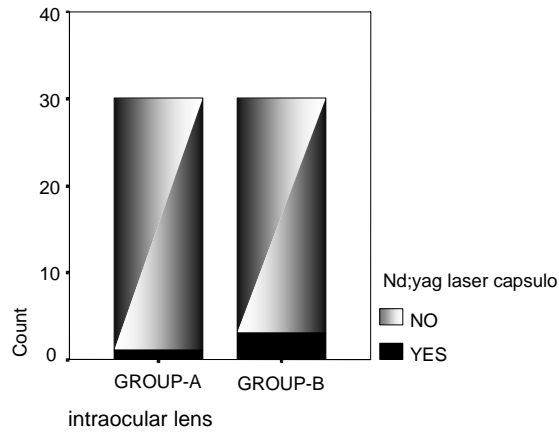
Sixty patients of age related cataract were included in the study, grouped into A and B. The patients included in Group A were those who opted for Acrylic foldable intraocular lens and group B those who opted for silicone foldable intraocular lens. Out of which 80% were male and 20% were female in the ratio of 4:1. The patients' age ranged from 50 to 80 years with a mean value of 65 years.

Our study showed that out of 30 patients in Group A those who opted for Acrylic foldable intraocular lens only one patient was diagnosed as having clinically significant posterior capsular opacification enough to reduce visual acuity by two lines (snellen chart) requiring Nd: YAG laser capsulotomy at the end of one year and out of 30 patients in Group B those who opted for silicone foldable intraocular lens three were patient diagnosed as having clinically significant posterior capsular opacification enough to reduce visual acuity by two lines requiring Nd:YAG laser capsulotomy at end of one year. Clinically significant posterior capsular opacification and frequency Of Nd: YAG laser capsulotomy was

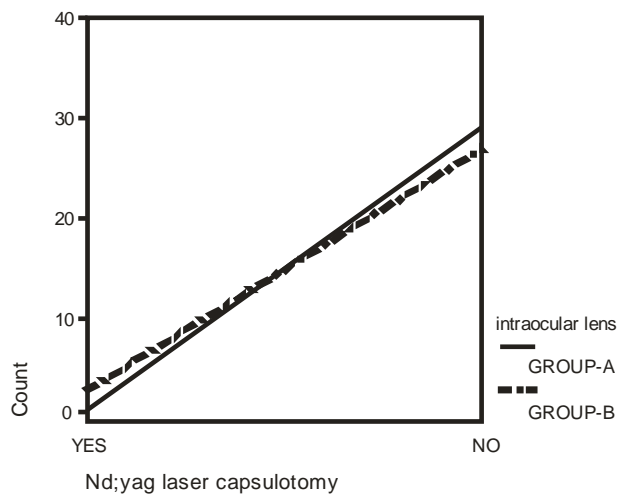
different in both groups; 3.33% in the acrylic group and 10% in the silicone group. The posterior capsule remained clear in 96.67% of the acrylic and 90% of the silicone IOL eyes. In the silicone IOL group, PCO was more common in eyes. Eyes with acrylic IOL showed difference in significant PCO. Our study was clinically significant.

## DISCUSSION

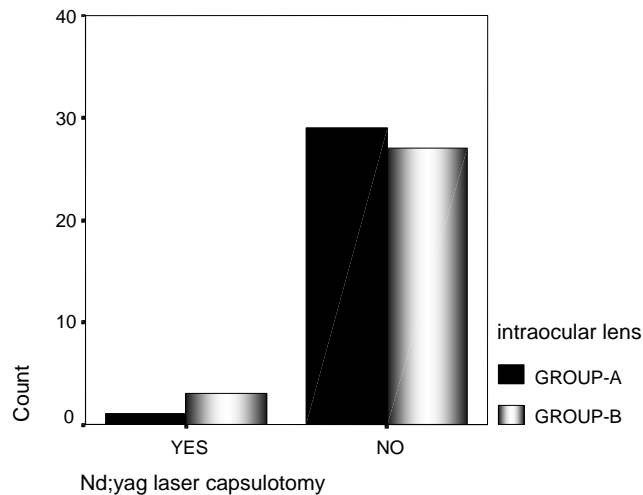
Posterior capsular opacification is the opacification of posterior capsule after cataract extraction due to proliferation of anterior epithelial lenticular cells on the posterior capsule sufficient to cause a significant decrease in vision. Early posterior capsular opacification seems to be multi-factorial in origin<sup>4</sup>. At surgery it is physically impossible to remove all lens epithelial cells from the capsular bag; those that remain proliferate and undergo metaplasia. Posterior capsular opacification after surgery can be thought of conceptually as the normal wound healing response. This causes reduction of visual acuity and the need for intervention once again at the hospital level that may be disturbing, especially for the elderly.



**Graph 1.**

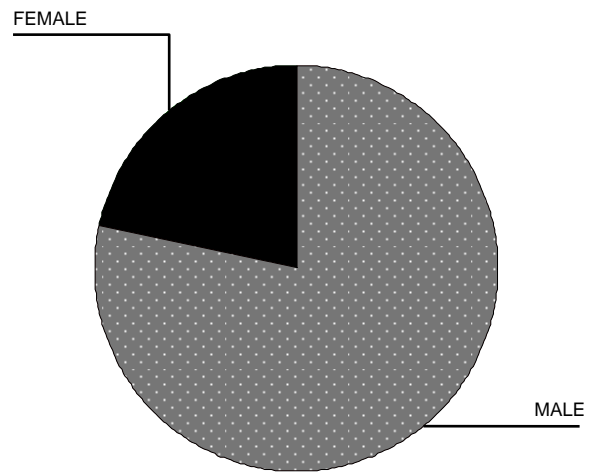


**Graph 2.**



**Graph 3. % of Nd: YAG laser capsulotomy**

Male=80female=20%



**Graph 4. Sex Distribution**

By keeping these problems in view, there is now considerable interest in ways to reduce PCO. Our study was planned to find out the frequency of Neodymium YAG laser capsulotomy after phacoemulsification with implantation of acrylic and silicon foldable posterior chamber intraocular lenses. Hence we are able to find out a way to reduce the chances of development of posterior capsular opacification and decrease the number of patients coming again to hospitals for treatment. Our study shows that the material from which an IOL is made influences the frequency of Nd: YAG laser capsulotomy. It was more common in eyes receiving a silicone IOL than an acrylic IOL.

In our study frequency of Nd: YAG laser capsulotomy was less common in eyes receiving the foldable acrylic IOL. There was comparison of the foldable acrylic IOL with the foldable silicone IOL, by Callebaut showed that Intraocular lenses made from hydrophobic acrylic material are associated with a significantly reduced rate of Nd: YAG laser capsulotomies as compared with intraocular lenses made from hydrophilic acrylic material<sup>19</sup>. Our duration of study was one year so the percentage of YAG laser capsulotomy was low as compared to mentioned study. In our study clinically significant posterior capsular opacification (PCO) and frequency Of Nd: YAG laser capsulotomy was 3.33% in the acrylic group and 10% in the silicone group. Intraocular lenses made from polyacrylic are associated with a significantly reduced degree of PCO and lower YAG rates<sup>20</sup>. Therefore, PCO in eyes with a

silicone IOL was significantly more extensive than in those with acrylic IOL and resulted in marked impairment of visual acuity. J Hollick et al studied the influence of intraocular lens (IOL) material on the process of (LECs) lens epithelial cells migration<sup>21</sup>. Lens epithelial cells (LECs) were seen in 93% of silicone and 97% of PMMA IOLs at 90 days, compared with 46% of polyacrylic ( $p < 0.001$ )<sup>21</sup>. At year 2 LECs were present in all patients with silicone or PMMA lenses, whereas 62% of patients with polyacrylic IOLs had LECs ( $p < 0.001$ )<sup>21</sup>. Of those patients with LECs at day 90 LEC regression occurred in 8% with silicone IOLs and 15% of PMMA cases, compared with 83% of patients with polyacrylic IOLs ( $p < 0.0001$ )<sup>21</sup>.

The presence of LECs on the posterior capsule was considerably lower with polyacrylic than PMMA or silicone IOLs and LEC regression occurred more frequently<sup>21</sup>. The lower incidence of LECs and the higher rate of regression may explain why PCO formation appears to be reduced with polyacrylic lenses. This has important clinical implications for the prevention of PCO<sup>21</sup>.

This study which showed that the material from which an IOL is made influences whether LECs are present on the posterior capsule after cataract surgery and can affect the behavior of these cells. The presence of LECs on the posterior capsule at 90 days and 2 years was considerably lower with polyacrylic lenses than PMMA or silicone ( $p < 0.001$ ). Polyacrylic IOLs have been reported to be associated with a low incidence of PCO<sup>22-23</sup> and the observation that the cells causing PCO are significantly less likely to be present on the posterior capsule with this lens supports these studies.

The mechanism by which IOL material influences LEC behaviour is unknown but could be explained by either mechanical or material related effects. The higher refractive index of polyacrylic (1.55) compared with silicone (1.41-1.46) and PMMA (1.49) allows these IOLs to have much thinner optics, suggesting that physical bulk cannot be the explanation for the reduced LEC migration<sup>24</sup>. Polyacrylic IOLs have a more defined and squarer optic edge than the other two implants and one study showed a significant decrease in PCO with sharp optic edges<sup>25</sup>. The authors suggest that the sharp edge acts as a mechanical barrier to lens epithelial cell migration onto the posterior capsule. This could be of importance in decreasing the number of cells on the posterior capsules with polyacrylic IOLs but would not explain the phenomenon of LEC regression and the stability of the anterior capsule on the IOL<sup>26</sup>.

Preclinical studies on AcrySof showed no evidence that it was toxic to LECs<sup>27</sup>. Macrophages can readily be seen on the anterior surface of some IOLs postoperatively, particularly in diabetic or uveitic patients, and are thought to be an indication of a foreign body reaction<sup>28</sup>. In one study no macrophages were seen when LEC regression occurs, suggesting that regression was not a necrotic process<sup>21</sup>.

IOLs made of this polyacrylic have a tacky surface. Indirect evidence for an adhesive relation between polyacrylic IOLs and the capsule has been provided by measuring anterior capsular movement on the lens optic<sup>24</sup>. It has been shown that the anterior capsule is much more stable on the anterior surface of a polyacrylic lens than PMMA or silicone and only minor capsule movement occurs with time, possibly as it is stuck to the anterior IOL surface<sup>26</sup>. T Neuhann presented a paper that there were a number of anecdotal accounts from surgeons which suggest that if polyacrylic IOLs have to be explanted for anisometropia they become adherent to the capsule soon after surgery and are relatively difficult to explant in comparison with PMMA or silicone lenses<sup>29</sup>. Ernest PH. study which showed that 50 eyes that had an Nd: YAG capsulotomy, 17 were in the AcrySof group and 33 were in the PhacoFlex II group<sup>30</sup>. All differences between groups were statistically significant ( $P < .05$ ) with conclusion that the AcrySof MA30BA IOL was associated with less PCO proliferation and thus fewer Nd: YAG laser posterior capsulotomies than the PhacoFlex II SI-40NB silicone (AMO) intraocular lenses (IOLs)<sup>30</sup>. Pohjalainen T, Vesti E, Uusitalo RJ, Laatikainen L. study showed that in a consecutive series of 80 cataract eyes central PCO was equally common in eyes receiving a silicone or an acrylic IOL<sup>31</sup>. In the silicone IOL group, however, significant PCO was more common if there was concurrent ocular disease, while with the acrylic IOL concurrent ocular disease did not seem to increase the risk of PCO<sup>31</sup>. Study of Ursell et al. showed that there was a significant difference in percentage of PCO at 2 years among the three lens types ( $P < .0001$ ). The AcrySof lenses were associated with less PCO (median 11.75%) than PMMA (43.65%) and silicone (33.50%) lenses ( $P < .001$  and  $P = .025$ , respectively). The difference between PMMA and silicone lenses was not statistically significant with conclusion that intraocular lenses made from AcrySof were associated with a significantly reduced degree of PCO<sup>32</sup>. Study of K Hayashi and H Hayashi showed that posterior capsule opacification in eyes with a hydrophilic hydrogel IOL

is significantly more extensive than that in eyes with a hydrophobic acrylic IOL, and results in a significant impairment of visual acuity<sup>33</sup>. Keeping in view all these studies, our study was showing results which were clinically significant but not statistically due to less duration.

## CONCLUSION

In a consecutive series of 60 cataract operated eyes, PCO and frequency of Nd: YAG laser capsulotomy was more common in eyes receiving a silicone IOL than eyes receiving acrylic IOLs.

The degree of PCO after silicone IOL implantation progressed significantly with time, while the progression after acrylic IOL implantation was slight. Therefore, PCO in eyes with a silicone IOL was significantly more extensive than in those with a acrylic IOL and resulted in marked impairment of visual acuity clinically though not significant statistically.

Silicone IOLs induced PCO is faster than acrylic IOLs, with fibrosis the most common type in the silicone group. Precautions should be taken to prevent damage during Nd: YAG laser capsulotomy in eyes with a silicone IOL.

### Author's affiliation

Dr. Muhammad Kashif Hanif  
Classified Eye Specialist  
CMH Malir, Karachi

Dr. Syed Abid Hassan Naqvi  
Classified Eye Specialist  
CMH Malir, Karachi

Dr. Uzma Ansari  
Department of Ophthalmology  
CMH Malir, Karachi

Dr. Haseeb Ahmed Khan  
Department of Ophthalmology  
PNS, Karachi

Dr. Muhammad Kamran Saeed  
Classified Eye Specialist  
PAF, Karachi


## REFERENCE

1. **Apple DJ, Solomon KD, Tetz MR.** Posterior capsule opacification. *Surv Ophthalmol.* 1992; 37: 73-116.
2. **Kappelhof JP, Vrensen GFJM.** The pathology of after-cataract. A minireview. *Acta Ophthalmol.* 1992; 205: 13-24.
3. **Schaumberg DA, Dana MR, Christen WG, et al.** A systematic overview of the incidence of posterior capsular opacification. *Ophthalmology.* 1998; 105: 1213-21.
4. **Iqbal Z, Palimar P.** Risk factors for early posterior capsular opacification and morbidity following Nd-YAG laser capsulotomy. *Pak J Ophthalmol.* 2002; 18: 98-101.
5. **Spalton DJ.** Posterior capsular opacification after cataract surgery. *Eye.* 1999; 13: 489-92.
6. **Nishi O.** Incidence of posterior capsule opacification in eyes with and without posterior chamber intraocular lens. *J Cataract Refract Surg.* 1986; 12: 519-22.
7. **Hansen TE, Otland N, Corydon L.** Posterior capsule fibrosis and intraocular lens design. *J Cataract Refract Surg.* 1988; 14: 383-6.
8. **Fezzotti R, Caporossi A.** Pathogenesis of posterior capsular opacification. Part I. Epidemiological and clinico-statistical data. *J Cataract Refract Surg.* 1990; 16: 347-52.
9. **Zetterström C, Kugelberg U, Lundgren B.** After-cataract formation in newborn rabbits implanted with intraocular lenses. *J Cataract Refract Surg.* 1996; 22: 85-8.
10. **Lindstrom RL, Harris WS.** Management of the posterior capsule following posterior chamber lens implantation. *Am Intra-Ocular Implant Soc J.* 1980; 6: 255-8.
11. **Nasissé MP, Dykstra MJ, Cobo LM.** Lens capsule opacification in aphakic and pseudophakic eyes. *Graefes Arch Clin Exp Ophthalmol.* 1995; 233: 63-70.
12. **Nishi O, Nishi K.** Preventing posterior capsule opacification by creating a discontinuous sharp bend in the capsule. *J Cataract Refract Surg.* 1999; 25: 521-6.
13. **Nishi O, Nishi K, Wickstrom K.** Preventing lens epithelial cell migration using intraocular lenses with sharp rectangular edge. *J Cataract Refract Surg.* 2000; 26: 1543-9.
14. **Nishi O, Nishi K, Akura J.** Speed of capsular bend formation at the optic edge of acrylic, silicone, and poly (methyl methacrylate) lenses. *J Cataract Refract Surg.* 2002; 28: 431-7.
15. **Kruger AJ, Schauersberger J, Abela C.** Two-year results: sharp versus rounded optic edges on silicone lenses. *J Cataract Refract Surg.* 2000; 26: 566-70.
16. **Buehl W, Findl O, Menapace R.** Effect of an acrylic intraocular lens with a sharp posterior optic edge on posterior capsule opacification. *J Cataract Refract Surg.* 2002; 28: 1105-11.
17. **Aykan U, Bilge AH, Karadayi K, et al.** The effect of capsulorhexis size on development of posterior capsule opacification: small (4.5 to 5.0 mm) versus large (6.0 to 7.0 mm). *Eur J Ophthalmol.* 2003; 13: 541-5.
18. **Awan A, Kazmi SH, Bukhari SA.** Intraocular pressure changes after ND-YAG laser capsulotomy. *J Ayub Med Coll Abbottabad* 2001; 13: 3-4.
19. **Javdani SM, Huygens MM, Callebaut F.** Neodymium: YAG capsulotomy rates after phacoemulsification with hydrophobic and hydrophilic acrylic intraocular lenses. *Bull Soc Belge Ophthalmol.* 2002; 283: 13-7.
20. **Hollick EJ, Spalton DJ, Ursell PG, et al.** The effect of polymethylmethacrylate, silicone, and polyacrylic intraocular lenses on posterior capsular opacification 3 years after cataract surgery. *Ophthalmology.* 1999; 106: 49-54.
21. **Hollick J, Spalton J, Ursell G, et al.** Lens epithelial cell regression on the posterior capsule with different intraocular lens materials. *Br J Ophthalmol.* 1998; 82: 1182-8.
22. **Oshika T, Suzuki Y, Kizaki H.** Two year study of a soft intraocular lens. *J Cataract Refract Surg.* 1996; 22: 104-9.
23. **Ursell PG, Spalton DJ, Pande MV.** The relationship between intraocular lens biomaterials and posterior capsule opacification: a 2 year prospective randomised trial comparing

- PMMA, silicone and polyacrylic lenses. *J Cataract Refract Surg.* 1998; 24.
24. **Pandey SK, Apple DJ, Werner L, et al.** Posterior capsule opacification: a review of the aetiopathogenesis, experimental and clinical studies and factors for prevention. *Indian J Ophthalmol.* 2004; 52: 99-112.
  25. **Nagata T, Wantanabe I.** Optic sharp edge or convexity: comparison of effects on posterior capsular opacification. *Jpn J Ophthalmol.* 1996; 40: 397-403.
  26. **Ursell PG, Spalton DJ, Pande MV.** Anterior capsule stability in eyes with intraocular lenses made of poly (methyl methacrylate), silicone and AcrySof. *J Cataract Refract Surg.* 1997; 23: 1532-8.
  27. **Ando H, Ando N, Oshika T.** Cumulative probability of neodymium: YAG laser posterior capsulotomy after phacoemulsification. *J Cataract Refract Surg.* 2003; 29: 2148-54.
  28. **Kim MJ, Lee HY, Joo CK.** Posterior capsule opacification in eyes with a silicone or poly (methyl methacrylate) intraocular lens. *J Cataract Refract Surg.* 1999; 25: 251-5.
  29. **Neuhann T.** Foldable IOLs: different materials and different designs. Presentation at the XIVth Congress of the European Society of Cataract and Refractive Surgeons, Gothenburg Sweden 1996.
  30. **Ernest PH.** Posterior capsule opacification and neodymium: YAG capsulotomy rates with AcrySof acrylic and PhacoFlex II silicone intraocular lenses. *J Cataract Refract Surg.* 2003; 29: 1546-50.
  31. **Pohjalainen T, Vesti E, Uusitalo RJ, et al.** Posterior capsular opacification in pseudophakic eyes with a silicone or acrylic intraocular lens. *Eur J Ophthalmol.* 2002; 12: 212-8.
  32. **Ursell PG, Spalton DJ, Pande MV, et al.** Relationship between intraocular lens biomaterials and posterior capsule opacification. *J Cataract Refract Surg.* 1998; 24: 352-60.
  33. **Hayashi K, Hayashi H.** Posterior capsule opacification after implantation of a hydrogel intraocular lens. *Br J Ophthalmol.* 2004; 88: 182-5.

---

## Guess Who? Answer



### Jannik Peterson Bjerrum

Danish ophthalmologist. Born 1851, died 1920

Jannik Petersen Bjerrum was born 26th December 1851 in Skarbak, a village in the most southern part of

Jutland in the border district between the Danish kingdom and the Duchy of Schleswig-Holstein. This was a highly disputed area and the object of numerous political debates and military battles. In 1848 just before Bjerrum was born, a local rebellion evolved into a war between the Danish king and the German-oriented duke. This war ended with a glorious Danish victory, and Schleswig-Holstein remained a part of Denmark, but only for a short period. In 1864 another war started, now between Germany (and Austria) and Denmark. In short order this campaign ended in a total Danish defeat, and Southern Jutland, almost one third of the kingdom, was incorporated in the new German Empire where it remained until 1920. Thus Bjerrum was born in Denmark, but grew up in Germany. He left the Cathedral School of Ribe, Denmark 1869 and completed his medical degree in 1876 in Copenhagen. Inspired by Hansen Grut, he soon became interested in ophthalmology and was appointed Hansen Grut's assistant in 1879. Bjerrum's scientific concern was the relationship between visual perception of form and the resolving power in localized areas of the retina. He demonstrated this in his thesis entitled ' Undersøgeleser over Formsans og Lyssands i forskellige Øjensyndomme (Investigations on the form sense and light sense in various eye diseases). This title is deliberately given in Danish to indicate that through his entire lifetime it was

(Continue See Page 227)