

Optic Nerve Involvement in Retinoblastoma: Role of Computed Tomography with and without Contrast

Soufia Farrukh, Farooqi Saghir, Muhammad Zubair, Mughese Amin

Pak J Ophthalmol 2009, Vol. 25 No. 4

See end of article for authors affiliations

Correspondence to:
Soufia Farrukh
27-B Mediacolony
Bahawalpur.

Received for publication
March' 2009

Purpose: The study was designed to evaluate the role of contrast enhanced CT scan as a non invasive test in the detection of optic nerve involvement in retinoblastoma.

Material and Methods: This retrospective study was conducted in Bahawal Victoria Hospital, Bahawalpur over a period of one year. 19 consecutive retinoblastoma patients underwent CT scan without and with I/V contrast. If the central retinal vessels were subjectively visualized with I/V contrast the optic nerve (ON) was considered to be free of RB. 19 enucleated globes were also sent for histopathology, all the optic discs and nerves examined for presence or absence of tumor and the level of involvement.

Results: The correlation between visualization/enhancement of central retinal vessels and the presence or absence of optic nerve involvement histopathologically was found to be significant. ($p=0.0006$, Fisher exact test).

Conclusion: In high spatial resolution enhanced CT with 1.5mm sections, non visualization of central retinal vessels reliably indicates optic nerve involvement with retinoblastoma.

The diagnosis of RB is made primarily by indirect ophthalmoscopic examination with ultrasonography used as a confirmatory procedure. Since most intra ocular RB contains calcium, sonography is ideal because even a small amount of calcium produces a significantly high internal reflectivity in USG^{1,2}. However once RB infiltrates the ON or extends into the orbit through sclera, sonography is ineffective because of shadowing artifact from intra ocular calcifications on the non calcific nature of extra ocular tumor.

Consequently other imaging procedures as CT or MRI are considered better modalities for evaluation of extra ocular extension of RB³.

Of the two procedures CT is preferred because of MRI's relative insensitivity to calcifications^{3,4}. (Fig 1) Both imaging procedures are valuable in detecting the presence of associated midline brain lesion, "trilateral RB^{5,6}.

The involvement of optic nerve indicates poor prognosis in RB, therefore special attention is directed towards investigation of optic disc area with imaging procedure⁷.

In this study we evaluated the role of enhanced CT to demonstrate the involvement of optic nerve.

MATERIAL AND METHOD

This retrospective study was conducted in Bahawal Victoria Hospital, Bahawalpur over a period of one year. Nineteen patients with RB were selected for the study consecutively. Two patients were referred by pediatric surgeon and one by plastic surgeon. Nineteen eyes were studied with CT of the globe and orbits. High spatial resolution scans (1.5 mm section) were performed without and after administration of I/V contrast Ultravist-300, 2ml/kg). Multiplanar slices were obtained in enhanced scans. Special attention was paid to visualization of central retinal vessels. If

central area of optic nerve (ON) was enhanced anteriorly with intra venous contrast, central retinal vessels enhancement was labeled as 'present'; (Fig 2), if not visualized it was labeled as 'absent'. If entire optic nerve was enhanced diffusely with contrast, not only central retinal vessels but entire nerve was considered 'positive'. These categories were based on subjective interpretation by the radiologist and the ophthalmologist.

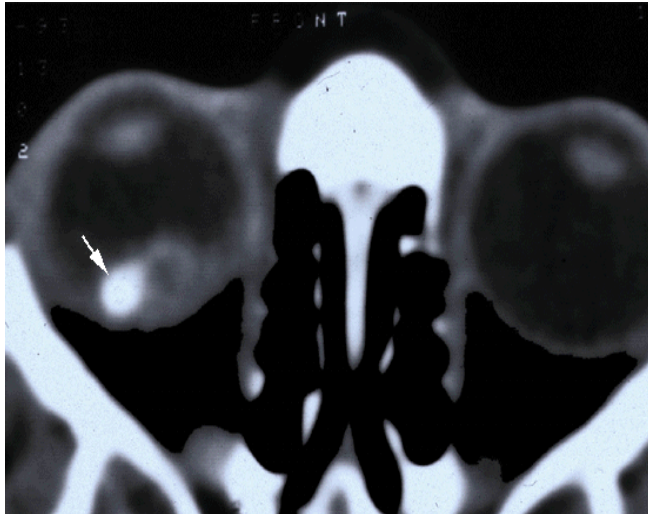


Fig. I: Retinoblastoma right eye showing calcification (arrow).

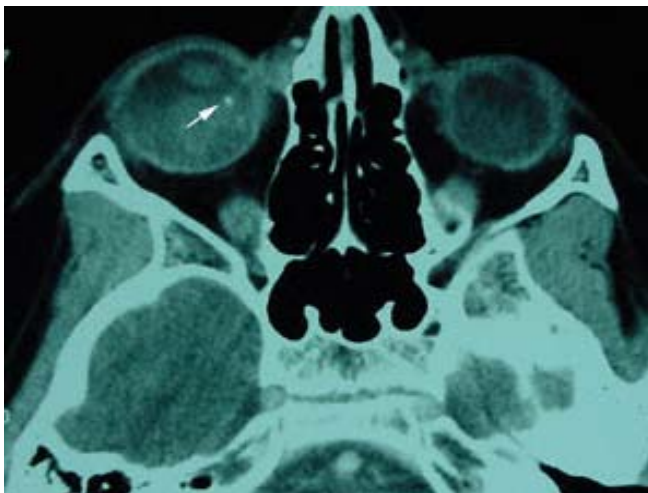


Fig. II: Retinoblastoma right eye showing enhancement after contrast and calcification (arrow).

Nineteen globes were enucleated and fixed in 10% formaldehyde and sent for histopathology. The optic disc was examined in at least 6 sequential sections for

the presence or absence of RB. If tumor was identified within the nerve fiber layer of the ON head the case was considered positive (anterior or posterior to lamina cribrosa) for optic nerve involvement; if not it was considered negative.

RESULTS

Of 19 eyes, central retinal vessels enhancement was present in 8 (42.1%), absent in 8 (42.1%) and questionably present in 3 (15.8%). Optic nerve enhancement was present in 3 (15.8%) and absent in 16 (84.2%) eyes.

On histopathological examination of 19 enucleated globes ON involvement was negative in 10 (52.6%). RB was present anterior to lamina cribrosa in 1 (5.3%) and posterior to lamina cribrosa in 8 (42.1%).

The correlation between the presence of central retinal vessels enhancement on CT and histopathological ON involvement was studied in 19 eyes and found to be significant. All 8 cases (100%) in which CRV enhancement was absent showed histopathologic tumor involvement posterior to lamina cribrosa. Of 8 eyes in which central retinal vessels enhancement was present, 7 (87.5%) histopathological revealed non involvement of the ON and in 1 case (12.5%) the ON was involved with tumor anterior to lamina cribrosa.

The correlation between visualization of central retinal vessels on enhanced CT scan and Histopathologic ON involvement (positive or negative) was highly significant ($p = 0.0006$, Fisher exact test) whereas correlation between central retinal vessels visualization on enhanced CT scan and choroidal involvement on histopathological was found to be statistically insignificant ($p = 0.14$).

DISCUSSION

During investigation for retinoblastoma, the two main aims are to establish the diagnosis and to determine the extent of the tumor^{7,9}. Most RB patients present with leucocoria and ophthalmoscopic recognition of RB. In a small percentage of cases, however, other conditions cause leucocoria; congenital cataract, toxocariasis, retinopathy or prematurity, PHPV, and Coats disease may be confused with RB⁸.

A number of modalities including ultrasonography, CT and MRI are helpful in establishing the diagnosis. Because of the frequency of calcification, sonography is considered the most sensitive test for confirmation of diagnosis^{5,10,11}.

Once diagnosis is established, the next step is to determine the boundaries of the tumor within the eye and whether there is extension into optic nerve, sclera and beyond the globe, for the later purpose CT and MRI are superior to sonography because they offer better marginal details and are not affected by artifactual shadowing due to intra ocular calcification.

(Gd-DPTA) enhanced MRI provides good delineation of the tumor from adjacent fluid medium, better detecting tumor vascularity and better definition of orbital blood vessels but there are also limiting factors for studying optic nerve head with MRI, including poor signal to noise ratio, reduced

spatial resolution and thicker sections (usually 3 mm). The most serious short coming of MRI in RB cases is its relative insensitivity towards calcification¹².

On the other hand, calcification can be detected by CT with a high degree of accuracy in approximately 90% of cases¹³. Further advantages of CT are its easy enhancement capability and its potential for detecting the presence of calcified midline lesions. CT studies are also favored over MRI due to relatively easier access and lower cost with MRI reserved for more difficult cases^{14,15}. The short acquisition time of orbital CT studies (seconds) compared with MRI (minutes) decreases motion artifact.

Table 1:

CRV Enhancement P/A/Q	ON Enhancement Present/Absent	ON Involvement Neg/ant LC/pos LC	Tumor H/P
Absent	Absent	Post. LC	Poorly Differentiated, ++Ca
Present	Absent	Negative	Poorly Differentiated
Absent	Present	Post. LC	Diffuse Necrosis
Present	Absent	Negative	Poorly Differentiated
Absent	Absent	Post. LC	Extrascleral Nodule
Questionable	Absent	Negative	Diffuse Necrosis
Absent	Present	Post. LC	Poorly Differentiated, necrotic, +Ca
Absent	Absent	Post. LC	Poorly Differentiated, ++Ca
Absent	Absent	Post. LC	Diffuse Necrosis, ++Ca
Present	Absent	Negative	Diffuse Necrosis, +++Ca
Present	Absent	Negative	Well Differentiated, ++Ca
Present	Absent	Ant. LC	Well Differentiated
Present	Absent	Negative	Necrosis, ++Ca
Present	Absent	Negative	Necrosis, ++Ca
Present	Absent	Negative	Poorly Differentiated
CRV Enhancement P/A/Q	ON Enhancement Present/Absent	ON Involvement Neg/ant LC/pos LC	Tumor H/P
Absent	Absent	Post. LC	Poorly Differentiated, ++Ca
Present	Absent	Negative	Poorly Differentiated
Absent	Present	Post. LC	Diffuse Necrosis

CRV, central retinal vessels; ON, optic nerve; Ca, calcium (+, ++, +++)

Using ultra thin (1.5 mm) sections to evaluate structures with a density significantly different from adjacent tissues, our results indicated improved visualization of the CRV. Although thin sections lead to low contrast resolution, this was not a disadvantage in our study because contrast enhancement was used.

In 8 cases where tumor was posterior to lamina cribrosa architectural disruption of central retinal vessels with tortuosity and distension could be visualized histopathologically. Any mass formation in the area such as RB or edema can easily produce distension with and without direct compression of the central retinal vein and/or artery, leading to their non visualization¹⁶.

CONCLUSION

Our study concluded that in high spatial resolution enhanced CT with 1.5 mm section, non visualization of central retinal vessels reliably indicates optic nerve invasion with RB. Although advances in CT and MR Angiography, echoplaner techniques and MR Spectroscopy may eventually offer better and safer imaging modalities, it seems that utilization of enhanced CT with ultra thin sections is a reliable and practical addition to our current armamentarium for retinoblastoma management.

Author's affiliation

Dr. Soufia Farrukh
27-B Mediacl Colony
Bahawalpur

Dr. Farooqi Saghira
Department of Radiology
QAMC & BVH,
Bahawalpur

Dr. Muhammad Zubair
Associate Professor
Pediatric Surgery
QAMC & BVH
Bahawalpur

Dr. Mughese Amin
Assistant Professor
Plastic Surgery
QAMC & BVH
Bahawalpur

REFERENCE

1. **Byrne SF, Green RL.** Ultrasound of eye and orbit. St. Louis: Mosby, 1992: 196-200.
2. **Shields GA, Michaelson JB, Leonard BC, et al.** B Scan ultrasonography in the diagnosis of atypical retinoblastomas. *Can J Ophthalmol.* 1976; 11: 42-51.
3. **Mafee MF, Goldberg MG, Greenwald JM et al.** Retinoblastoma and simulating lesions: role of CT and MR imaging. *Radiol Clin North Am.* 1987; 25: 667-82.
4. **Wilms G, Marchal G, Von Fraeyenhoven L, et al.** Shortcoming and pitfalls of MRI. *Neuroradiology.* 1991; 33: 320-5.
5. **Blach LE, McCormick E, Abramson EH, et al.** Trilateral retinoblastoma - incidence and outcome: a decade of experience. *Int J Radiat Oncol Biol Phys.* 1994; 29: 729-33.
6. **Nucci P, Modorati G, Pierrol L, et al.** Comparative evaluation of echography an CAT in diagnosis of retinoblastoma. *Minerva Pediatr* 1989; 41:129-31.
7. **Kopelman JE, McLean IW, Rosenberg SH.** Multivariate analysis of risk factors for metastasis in retinoblastoma treated by enucleation. *Ophthalmology.* 1987; 94: 371-7.
8. **Shields JA, Shields CL.** Intra ocular tumors: a text and atlas. Philadelphia: Saunders, 1992: 341-62.
9. **Karcioglu ZA, Al-Masfer SA, Jabak MH, et al.** Workup for metastatic retinoblastoma: a review of 261 patients. *Ophthalmology.* 1997; 104: 307-12.
10. **Shields JA, Stephens RF.** Ultrasonography in pediatric ophthalmology. Philadelphia: Saunders, 1982: 145-54.
11. **Shields JA, Michaelson JB, Leonard BC, et al.** Retinoblastoma in 18 years old male. *J Pediatr Ophthalmol.* 1976; 13: 275-7.
12. **Weber AL, Mafee MF.** Evaluation of the globe using computed tomography and magnetic resonance imaging. *Isr J Med Sci.* 1992; 23: 145-52.
13. **Beets-Tan RGH, Hendricks MJ, Ramos LMP, et al.** Retinoblastoma: CT an MRI. *Neuroradiology.* 1994; 36: 59-62.
14. **Hermans R, Marchal G, Feenstra L, et al.** Spiral CT of the temporal bone: value of image reconstruction of submillimetric table increments. *Neuroradiology.* 1995; 37: 150-4.
15. **Katz DA, Marks MP, Napel SA, et al.** Circle of Willis: evaluation with spiral CT angiography, MR angiography and conventional angiography. *Radiology.* 1995; 195: 445-9.
16. **Hayreh SS, Edwards J.** Ophthalmic artery and venous pressures: effects of acute intra cranial hypertension. *Br J Ophthalmol.* 1997; 55: 649-66.