

Case Report

Choroidal Melanoma in Ocular Melanocytosis

Muhammad Tariq Khan, Sanaullah Jan, Zakir Hussain, Samina Karim, Muhammad Kamran Khalid, Lal Mohammad

Pak J Ophthalmol 2010, Vol. 26 No.2

See end of article for authors affiliations

.....

Correspondence to:
Muhammad Tariq Khan
2-Lakhkar Khan Road
University Town
Peshawar

Received for publication
May' 2009

.....

Ocular melanocytosis is the melanocytic hyperplasia of the deeper layers of conjunctiva or the episclera. This should be differentiated from the other clinical entity, i.e. ocular melanosis, which is defined as melanocytic hyperplasia of the epithelial layers of conjunctiva.

Ocular melanocytosis, although rare in white races, is associated with somehow increased risk of uveal malignant melanoma. In darkskinned races, the disease entity is comparatively more common but its association for developing uveal melanomas is extremely rare.

We report a case of congenital ocular melanocytosis, later on complicated by choroidal malignant melanoma, in a dark-skinned Pakistani citizen.

A 35 years old male with congenital conjunctival melanocytosis of the right eye (left eye being un-affected) presented to us. His visual functions remained un-affected till the age of 33 years, when he noticed slight dimness of vision in his right eye. At the time of presentation, his vision had dropped to light perception in the affected eye. After detailed clinical work up and after performing some necessary investigations, a diagnosis of choroidal malignant melanoma was made. The eye was enucleated and histopathological examination confirmed the diagnosis.

Ocular melanocytosis is one of the three clinical variants of "congenital melanocytosis"; the other two being the dermal and the oculo-dermal melanocytosis.

"Ocular melanocytosis" is the least common of these three clinical settings. This is a congenital melanocytic hyperplasia involving only the eye and is typically unilateral¹.

Ocular melanocytosis of the deep conjunctiva or superficial sclera occurs in about 1 in every 2500 individuals and is more common in the Black, Hispanic and Asian populations. In Caucasians, it affects approximately 0.04% of population.

Pathologically, ocular melanocytosis consists of focal proliferation of sub-epithelial melanocytes. Patches of episcleral pigmentation appear slate gray through the normal conjunctiva. About one half of patients with ocular melanocytosis have ipsilateral dermal melanocytosis (nevus of Ota), a proliferation of

dermal melanocytes in the periocular skin of the first and second dermatomes of cranial nerve V².

Ocular melanocytosis has been associated with an increased incidence of malignant melanomas in white patients. Malignant melanoma can develop in conjunctiva, uvea or orbit. In whites, the lifetime risk of uveal melanoma in a patient with ocular melanocytosis is about 1 in 400; much greater than the risk of 1 in 13,000 of the general white population³.

Incidence of ocular melanocytosis is comparatively more common in Asians and Blacks, while the other entity, i.e. the benign acquired ocular melanosis, predominantly affects darkskinned and black population. The incidence of developing uveal malignant melanoma in patients with ocular melanocytosis in darkskinned population, although reported before, is extremely rare. We are hereby presenting a case report, where a 35 years old dark-skinned Pakistani developed malignant melanoma of the choroid in an

eye, previously diagnosed as a case of congenital conjunctival melanocytosis.

CASE REPORT

A 35 years old male, taxi driver by profession, presented with congenital ocular melanocytosis of the right eye (left eye being un-affected). On slit-lamp examination, the melanotic hyper-pigmentation had clinically involved the conjunctiva and the episclera of the right eye. There was no periocular dermal involvement.

The visual functions of the patient remained un-affected till the age of 33 years, when he for the first time, noticed slight dimness of vision in his right eye. At the time of presentation, his vision had dropped to perception of light in the affected eye. After clinical evaluation, A&B-scan ultrasonography was performed. A-scan typically showed initial high spike followed by low to medium internal reflectivity in the tumor. B-scan findings were consistent with mushroom-shaped melanoma showing choroidal mass with the typical internal acoustic hollowing and excavation (Fig. 1).

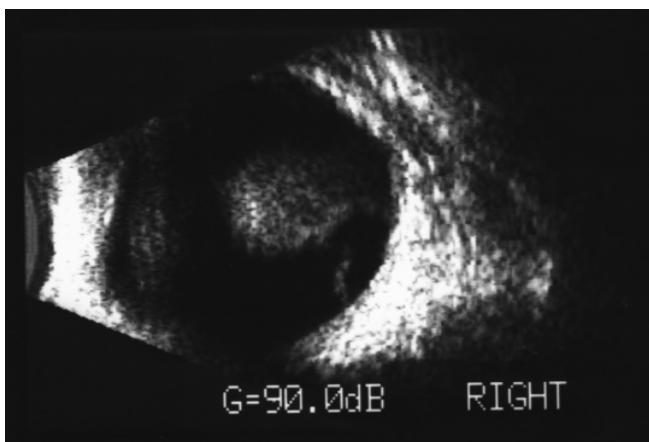
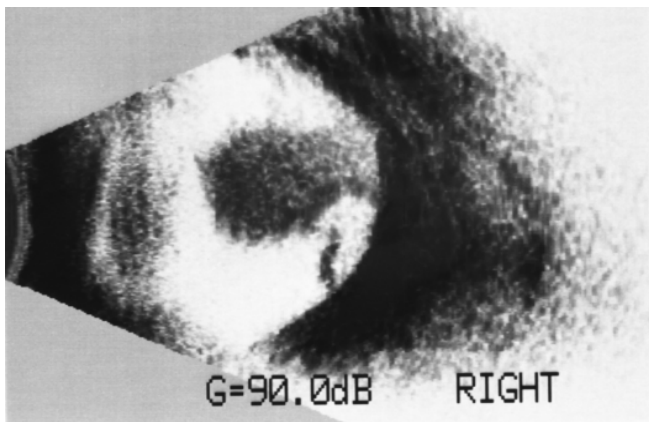
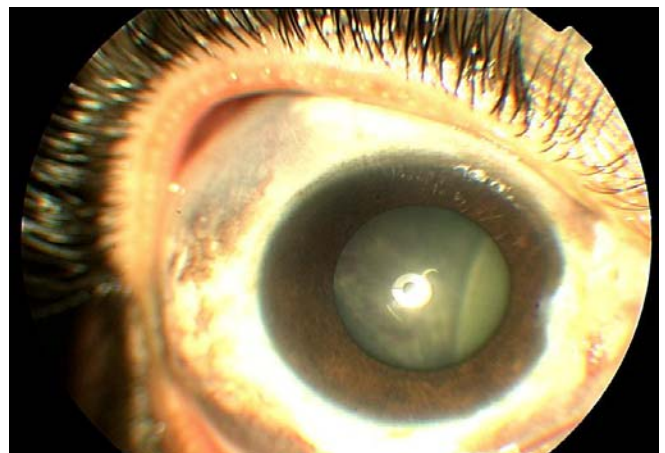
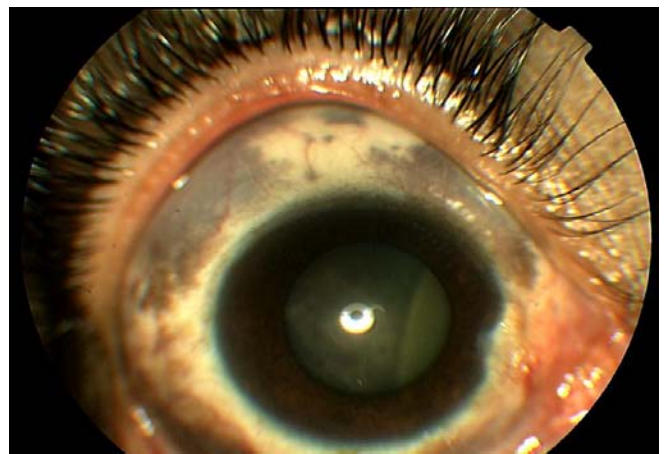
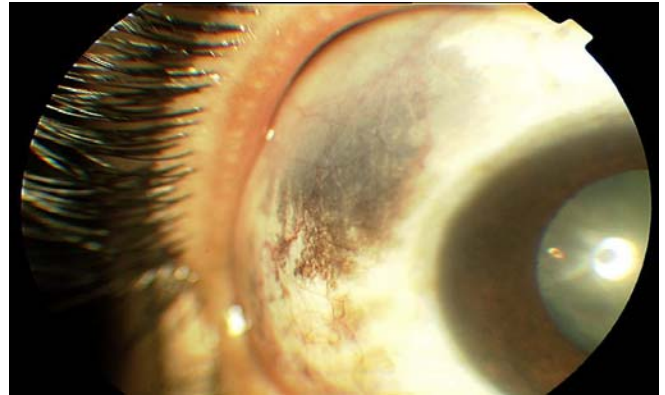


Fig: B-scan ultrasound of the right eye of the patient



After ruling out any metastatic spread by doing chest X-ray, abdominal ultrasound and blood profiles, a diagnosis of non-metastatic choroidal malignant melanoma was made. Enucleation of the eye was done and the histopathology confirmed the diagnosis (mixed variety of the choroidal malignant melanoma).

DISCUSSION

Choroidal melanoma is the most common primary intraocular malignant tumor in adults, with an annual incidence of six per million populations. It is typically unilateral and uni-focal tumor, although bilateral and bi-focal cases have been reported⁴.

Melanocytosis oculi is often under-estimated as a risk factor for uveal and conjunctival melanoma in dark-skinned population.

Sabates FN and Yamashita T, in 1967, reported a case of congenital melanocytosis oculi complicated by two independent malignant melanomas of the choroids⁵.

Hubel K, Hanselmayer H. in 1979 reported a case with melanosis bulbi observed in a relatively young patient of 33 years, in which a malignant melanoma of the choroid developed. As reported earlier, the incidence of malignant melanoma in cases of melanosis bulbi in white races is much higher than in normal eyes. The authors recommended strongly routine biomicroscopic examinations in cases of melanosis bulbi every 1-2 years to recognize the development of a melanoma at an early stage⁶.

Straatsma BR, Duffin RM, Foos RY, and Kreiger AE in 1981 reported that in a white patient with melanosis oculi, a small choroidal melanoma in the hyperpigmented eye was observed for 8 years before enucleation. An important factor in the decision to enucleate was echographic evidence of extra-ocular tumor extension. Histopathologic examination confirmed the presence of a small choroidal melanoma (with an intraocular tumor volume of about 60 mm³), scleral tumor infiltration, and extra-scleral tumor extension. Discussion considered the extremely important role of echography in the management of even small choroidal melanomas, and its significance in extra-ocular tumor extension⁷.

Wilkes TD, Uthman EO, Thornton CN and Cole RE, in 1984, reported a case of a choroidal melanoma in a black patient with oculo-dermal melanocytosis⁸.

Brini A. in 1985 reported a case of melanocytosis oculi with malignant melanoma of the choroid. Microscopical examination confirmed the clinical diagnosis in this case⁹.

Roldan M, Llanes F, Negrete O and Valverde F. of the department of ophthalmology, University Hospital of Madrid Spain, in 1987, reported malignant melanoma of the choroid associated with melanocytosis oculi in a child¹⁰.

Gonder JR, Shields JA, Shakin JL, and Albert DM. reported a woman with bilateral ocular melanocytosis, who later on developed a malignant melanoma of the choroid in one eye¹¹.

Gunduz K, Shields JA, Shields CL, and Eagle RC Jr. in 1998, presented a 14-years old male adolescent with ocular melanocytosis and secondary glaucoma in the left eye, in whom ophthalmoscopy disclosed diffuse choroidal pigmentation and a pigmented mass that occupied the macular area and surrounded the optic nerve. Ultrasonography showed an acoustically hollow lesion with scleral bowing and choroidal excavation. Based on clinical and ultrasonographic findings, a diagnosis of choroidal melanoma was made. The eye was enucleated and histopathology confirmed the diagnosis¹².

Lopez-Caballero C, Saornil-Alvarez MA, Blanco-Mateos G, Frutos-Baraja JM, Lopez-Lara F, and Gonzalez-Sansegundo C. in 2003, presented four cases of ocular melanosis. Choroidal melanoma was detected in all of them. Three eyes had decreased visual acuity and were enucleated because they contained large active tumors. In the fourth case, the melanoma was detected on routine examination and the authors were able to apply a conservative treatment with I₁₂₅ brachytherapy.

The authors recommended that ophthalmic surveillance, every 6 or 12 months is important in patients with ocular melanosis, for early detection of high-risk diseases¹³.

Velazquez N, and Jones IS found fifteen patients with ocular or oculo-dermal melanocytosis, after reviewing 1210 cases of histologically proved uveal melanomas. The melanoma in each of these patients developed in the eye affected with ocular or oculo-dermal melanocytosis and not in the unaffected eye. In one case with bilateral oculo-dermal melanocytosis, the patient developed melanoma in the eye with more pronounced signs of melanocytosis. In case of partial ocular melanocytosis, melanoma developed in the sector of the eye affected by melanocytosis¹⁴.

CONCLUSION

Previous statistical data shows that the risk of uveal melanoma in white races is greater in patients with ocular melanocytosis than the normal white population. But this increased risk in case of dark-skinned (like South-Asians) or Black population has hardly being supported by the literature in the past.

With this case report, we strongly recommend a yearly eye examination and B-scan ultrasound assessment in cases of ocular melanocytosis, so as to recognize the development of a choroidal melanoma at an early stage.

Author's affiliation

Dr. Muhammad Tariq Khan
Trainee Medical Officer (Vitreoretinal Ophthalmology)
Khyber Institute of Ophthalmic Medical Sciences
PGMI, Hayatabad Medical Complex
Peshawar

Dr. Sanaullah Jan
Senior Registrar
Khyber Institute of Ophthalmic Medical Sciences
PGMI, Hayatabad Medical Complex
Peshawar

Dr. Zakir Hussain
Trainee Medical Officer
Khyber Institute of Ophthalmic Medical Sciences
PGMI, Hayatabad Medical Complex
Peshawar

Dr. Samina Karim
Trainee Medical Officer
Khyber Institute of Ophthalmic Medical Sciences
PGMI, Hayatabad Medical Complex
Peshawar

Dr. Muhammad Kamran Khalid
District Eye Specialist
Lakki Marwat, NWFP

Dr. Lal Mohammad
Assistant Professor
Kohat Medical College
Kohat University of Science and Technology
Kohat, NWFP

REFERENCE

1. **Kanski JJ.** Clinical Ophthalmology. 5th Ed; Butterworth-Heinemann. 2003; 84-6.
2. **Kirk RW, Andrew JW, David GH, et al.** Clinical approach to neoplastic disorders of the conjunctiva and cornea- external diseases and cornea: AAO, BCSC Sec. 8, San Francisco. 1999; 244.
3. **Sakel JA, Meyer LH, Marcus DM, et al.** Nevus and melanocytoma. In: Albert DM, Jakobiec PA. Principles and practice of Ophthalmology. Philadelphia WB Saunders. 2002; 6: 5006-12.
4. **Honavar SG, Shields CL, Singh AD, et al.** Two discrete choroidal melanomas in an eye with ocular melanocytosis. Surv Ophthalmol. 2002; 47: 36-41.
5. **Sabates FN, Yamashita T.** Congenital melanosis oculi complicated by two independent malignant melanomas of the choroid. Arch Ophthalmol. 1967; 77: 801-3.
6. **Hubel K, Hanselmayer H.** Malignant melanoma of the choroid in melanosis bulbi. Klin Monatsbl Augenheilkd. 1979; 174: 404-7.
7. **Straatsma BR, Duffin RM, Foos RY, et al.** Melanosis oculi, small choroidal melanoma, and extraocular extension. Dev Ophthalmol. 1981; 2: 92-104.
8. **Wilkes TD, Uthman EO, Thornton CN, et al.** Malignant melanoma of the orbit in a black patient with ocular melanocytosis. Arch Ophthalmol. 1984; 102: 904-6.
9. **Brini A.** A case of melanosis oculi with malignant melanoma of the choroid. Int Ophthalmol. 1985; 7: 169-74.
10. **Roldan M, Llanes F, Negrete O, et al.** Malignant melanoma of the choroid associated with melanosis oculi in a child. Am J Ophthalmol. 1987; 104: 662-3.
11. **Gonder JR, Shields JA, Shakin JL, et al.** Bilateral ocular melanocytosis with malignant melanoma of the choroid. Br J Ophthalmol. 198; 65: 843-5.
12. **Gunduz K, Shields JA, Shields CL, et al.** Choroidal melanoma in a 14-year-old patient with ocular melanocytosis. Arch Ophthalmol. 1998; 116: 1112-4.
13. **Lopez-Caballero C, Saornil-Alvarez MA, Blanco-Mateos G, et al.** Choroidal melanoma in ocular melanosis. Arch Soc Esp Oftalmol. 2003; 78: 99-102.
14. **Velazquez N, Jones IS.** Ocular and oculodermal melanocytosis associated with uveal melanoma. Ophthalmology. 1983; 90: 1472-6.