

Presentation Pattern of Retinoblastoma

Sadia Bukhari, Aziz-ur-Rehman, Israr Ahmed Bhutto, Umair Qidwai

Pak J Ophthalmol 2011, Vol. 27 No. 3

See end of article for
authors affiliations

Purpose: To determine the pattern of presentation of retinoblastoma.

Correspondence to:
Sadia Bukhari
Isra Postgraduate Institute of
Ophthalmology, Al-Ibrahim Eye
Hospital, Old Thana Village
Memon Goth Road Malir,
Karachi

Materials and Methods: This is a retrospective case series based on clinical records of patients less than 15 years identified with retinoblastoma from January 2006 to December 2009. Demographic characteristics including; presenting symptoms and signs, family history, age, gender, laterality and provided treatment were analyzed.

Submission of paper
May' 2011

Results: Sixty two patients with retinoblastoma were identified, out of which 79% had unilateral involvement while 21% had bilateral involvement. The most common sign of presentation was leukocoria 56.5% followed by proptosis 24.2%. Other presenting signs include fungating mass in orbit, red and watery eyes with raised intraocular pressure and diffuse vitreous haze.

Acceptance for publication
August' 2011

Conclusion: The most common presenting sign is leukocoria but proptosis also accounts for significant number of cases. Because of delay in presentation and diagnosis of retinoblastoma preservation rate of globe is very low. Raising awareness and education of primary health care providers and parents is strongly recommended.

Retinoblastoma is the most common intraocular malignancy of childhood with an incidence of 1: 14,000 - 1: 20,000 live births¹. It accounts for about 3% of all childhood malignancies under 15 years of age². Untreated retinoblastoma is almost fatal but with availability of resources for early detection and treatment the survival rate has increased to more than 90% in developed countries^{3,4}. However in developing countries majority of patients present with advanced disease with resultant 5 year survival rate ranging from 40-79%⁵⁻⁷.

Most common presentation of retinoblastoma in children is with leukocoria⁸. Other presentations are strabismus, glaucoma, hyphema. Proptosis although rare in developed countries is still a frequent mode of presentation in developing countries^{9,10}.

The aim of this study is to determine the clinical presentation of children presented with retinoblastoma's limited amount of work has been carried out on this subject within our community.

MATERIAL AND METHODS

This hospital based retrospective study was carried out at pediatric ophthalmology department of Al-Ibrahim eye hospital. The medical records of patients under 15 years between January 2006 to December 2009, were reviewed and analyzed. Data was compiled on demographic characteristics, clinical examination, histopathology findings, treatment given and their outcomes. The initial evaluation of children included complete ocular history including presenting complaints, duration of symptoms, family history, birth history, prior treatment and any associated systemic problems. Complete ophthalmological examination was carried out including visual acuity, slit lamp examination and dilated fundus examination with scleral indentation under GA. The diagnosis was made on basis of clinical signs as leukocoria associated with retinal mass. Chalky areas of calcification were also visible majority of times and /or proptosis preceded by a history of abnormal glow in eye. Sometimes leukocoria associated with corneal edema

and raised IOP with or without hyphema was the presenting feature or advanced proptosis with huge fungating mass in orbit. Confirmation was made on imaging studies i.e. CT scan or B-scan ultrasonography looking for presence of calcification in intraocular mass arising from retina. MRI was advised in those patients who presented with proptosis to see extra ocular extension (orbit, optic nerve and brain). Treatment given includes enucleation with long piece of optic nerve in unilateral cases and at least one eye in bilateral cases along with chemotherapy including vincristine, etoposide, carboplatin or cyclophosphamide. After primary enucleation the diagnosis was confirmed on histopathological examination and patients were further evaluated for any signs of metastasis. Systemic evaluation includes full blood count, lumbar puncture for CSF cytology. Bone marrow aspirates for tumor cells and MRI. Data was analyzed for mode of presentation, age and gender, laterality, involvement of cut section of optic nerve by tumor, scleral and extra scleral infiltration.

RESULTS

Sixty two patients were seen with retinoblastoma between January 2006 to December 2009 out of which, 33 (53.2%) were males while 29 (46.7%) were females. Mean age of the patient at the time of presentation was 33.31 months with standard deviation of 22.8. Minimum and maximum age of presentation was 5 months and 144 months respectively. Only 2 (3.2%) patients had positive family history while rest of the 60(96.8%) patients had no family history of retinoblastoma. Most of the patients i.e. 49 (79%) had unilateral involvement at the time of presentation while, 13 (21%) patients had bi-lateral involvement. Different modes of primary presenting signs were noted of which leukocoria was the most commonly seen primary presentation. Thirty five (56.5%) patient presented with leukocoria while proptosis also accounts for significant number of cases i.e. 24.2%. Frequency of other different modes of primary presentations is shown in (Fig. 1).

None of the patients presented with squint. Accidental diagnosis in a 6 months old girl having bilateral retinoblastoma who presented with sty in lower lid of left eye and parents were unaware of white pupillary reflex. The different treatment options applied on the patients are shown in (Table 1).

Twenty four (38.7%) patients refused treatment and didn't follow-up therefore their extent of

extension is not known while extension of tumor in rest of the patients is shown in Table 2. Primary enucleation was performed in 31 patients (one patient had bilateral enucleation) while exentration was performed in 7 patients. After enucleation it was found that in 21 eyes (33.9%) the tumor had not extended beyond the cut section of optic nerve. The level of extension and sites of metastasis is shown in (Table 2).

The patients were followed from one day to 48 months. The survival rate of patients, who underwent any form of treatment for retinoblastoma, is shown in (Fig. 2).

Table 1: Treatment for retinoblastoma

	Frequency n (%)
Enucleation	14 (22.6)
Exentration	2 (3.2)
Enucleation+Chemotherapy	16 (25.8)
Exentration+Chemotherapy	5 (8.1)
Eneucleation B/E	1 (1.6)
Refused for intervention	24 (38.7)

Table 2: Extension of the retinoblastoma

	Frequency n (%)
Extension not known (due to refusal of treatment)	29 (46.8)
Optic nerve free	21 (33.9)
Optic nerve involved	2 (3.2)
Orbit involved	3 (4.8)
Brain involved	2 (3.2)
Second eye involved	3 (4.8)
Brain and Bone involved	2 (3.2)
Total	62 (100)

DISCUSSION

The different modes of presentations reported in this study are almost similar to what have been reported in

many other studies conducted in developing countries. The common clinical presentation of leukocoria and proptosis in this study are also comparable to those in other developing countries including study from former NWFP of Pakistan¹¹. These features together with other signs such as secondary glaucoma, fungating mass and hyphema are known signs of advance disease or high risk of metastasis¹²⁻¹⁴. A study was performed in Congo on 29 patients revealed the common presenting signs to be leukocoria that is 49% followed by proptosis 28%. Other signs were strabismus, red eye, anterior scleral staphyloma, hyphema and Buphthalmos¹⁵. Although in our patients no case presents with squint. In Nepal an analysis of 43 patients demonstrated proptosis to be the commonest manifestation.

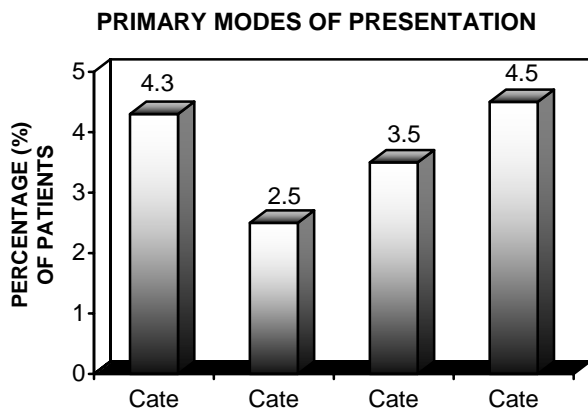


Fig. 1: Primary modes of presentation in retinoblastoma

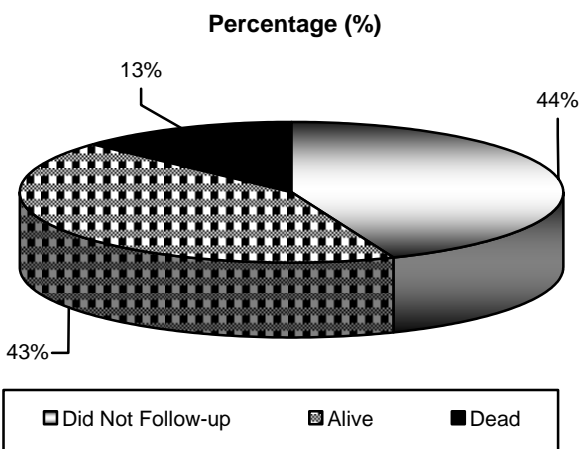


Fig. 2: Survival rate

This study showed that the majority of the patients presented with unilateral retinoblastoma. This

confirms with studies from both developed and developing countries^{15,17}. The mean age of diagnosis was high. This finding confirms observation from other developing countries of Africa and Asia^{15,18}. A high mean age of diagnosis has been found to be associated with advance or metastatic retinoblastoma. This is in sharp contrast with findings from developed countries where the mean age of diagnosis is less than 24 months^{15,17}. Another problem observed in our patients is the denial of disease by the parents. Those who presents while the tumor is still intraocular the parents don't generally accept the fact that their child can have cancer, which can necessitate removal of the eye and there is therefore delay in disease management. Some of them straight away refused for removal of the eye ball and they prefer to let their child die. Enucleation is still the most common treatment option as documented in most studies.¹⁹ This was also the commonest option in our study due to late presentation. At the early 20th century the survival rate of retinoblastoma patients was 25-30%, which was now improved to more than 90% in developed countries. In Europe it is reported as (95%)⁴ and in US (more than 93%)²⁰. However in developing countries the five years survival rate is still very low⁵⁻⁷. In our small series the survival rate could not be properly elicited because out of 62 patients 24 (38.7%) patients initially refused for any intervention and they left away. Surgical intervention was done in 38 patients of, which five patients did not come back once enucleation / exentration was done and the tissue was handed over to them for biopsy, so we followed 32 patients (at least for one year with maximum follow-up of five years).The main limitation of our study was that it was conducted in only one centre, and not much of ethnic variation was possible.

CONCLUSION

Majority of patients that presented with advanced disease found it difficult to accept the treatment options. Counseling is necessary to achieve complete understanding of the condition by care providers so as to avail the patients of the benefit of complete treatment and let them know the implications of defaulting.

The most common presenting sign is leukocoria but proptosis also accounts for significant number of cases. Due to the delay in presentation and diagnosis of retinoblastoma preservation rate of globe was very low. Raising awareness and education of primary

health care providers and parents is strongly recommended.

Author's affiliation

Dr. Sadia Bukhari
Assistant Professor,
Isra Postgraduate Institute of Ophthalmology
Al-Ibraheem Eye Hospital, Malir, Karachi

Dr. Aziz-u-Rehman
Associate Professor
Isra Postgraduate Institute of Ophthalmology
Al-Ibraheem Eye Hospital, Malir, Karachi

Dr. Israr Ahmed Bhutto
Senior Registrar
Isra Postgraduate Institute of Ophthalmology
Al-Ibraheem Eye Hospital, Malir, Karachi

Dr. Umair Qidwai
Postgraduate Student
Isra Postgraduate Institute of Ophthalmology
Al-Ibraheem Eye Hospital, Malir, Karachi

REFERENCE

1. American Academy of Ophthalmology Basic and clinical science course. Ocular and periocular tumors in childhood. IN: Pediatric ophthalmology and strabismus section 6 (2008-2009). LEO; Singapore. 2008. 390.
2. **Lennox EL, Draper GJ, Sanders BM.** Retinoblastoma: A study of natural history and progress of 268 cases. Br. Medical Journal. 1975; 3: 731-4.
3. **Shields JA, Shields CL.** Current management of retinoblastoma. Mayo Clin Proc. 1994; 69: 50-6.
4. **Mac Carthy A, Draper GJ.** Retinoblastoma incidence and survival in European children (1978-1997). Report from automated childhood cancer information system project. Eur J Cancer. 2006; 42: 2092-102.
5. **Naseirpour M, Falavarjani KG.** Retinoblastoma survival in Iran: 10 years experience of a referral centre. Iranian Journal of Ophthalmol. 2009; 21: 17-24.
6. **Andia LR, Cordero HR.** Epidemiological features and survival of retinoblastoma patients in Peru. 7th Internet world congress for biomedical sciences. Inabis. 2002; 14-20.
7. **Canturk S, Quddoumil.** Survival of retinoblastoma in less developed countries impact of socio-economic and health related indicators. B J Ophthalmol. 2010; 94: 1415-6.
8. **Taylor D, Hoyt CS.** Retinoblastoma. IN: Pediatric ophthalmology and strabismus 3rd Ed. Elsevier Saunders; London. 2005. 491.
9. **Kayembe-Lubeji D.** Retinoblastoma in Zaire. Tropical Doctor 1990; 20: 38.
10. **Kingston JE, Hungerford JL.** Retinoblastoma. IN: Paediatric Oncology, 2nd Ed. Pinkerton CR and Plowman PN (Eds). Chapman and Hall, London. 1997; 357.
11. **Arif M, Iqbal Z, Islam Z.** Retinoblastoma in NWFP, Pakistan. J Ayub Med Coll Abbottabad. 2009; 21: 60-2.
12. **Akang EE.** Retinoblastoma in Ibadan Nigeria II- Clinico Pathological Features. West Afr J Med. 2000; 19: 6-11.
13. **Klauss V, Chana HS.** Ocular tumors in Africa. Soc Sci Med. 1983; 17: 1743-50.
14. **Balasubramanya R, Pushker N.** Atypical presentations of retinoblastoma. J Pediatr Ophthalmol Strabismus. 2004; 41: 18-24.
15. **Akimbo WA.** Presenting signs of retinoblastoma in Congolese patients. Bull Soc Belge Ophthalmol. 2002; 283: 37-41.
16. **Badhu B, Sah SP, Thakur SK.** Clinical presentation of retinoblastoma in eastern Nepal. Clinical and Experimental Ophthalmol. 2005; 33: 386-9.
17. **Ozkan A, Pazarli H.** Retinoblastoma in Turkey survival and clinical characteristics 1981-2004. Pediatr Int. 2006; 48: 369-73.
18. **Sahu S, Banavali SD.** Retinoblastoma problems and perspectives from India. Pediatr Hematol Oncol. 1998; 15: 501-8.
19. **Owoeye JF, Afolayan TA.** Retinoblastoma - a clinical pathological study in Ilorin Nigeria. Afr J Health Sci. 2006; 13: 117-23.
20. **Abramson DH, Beaverson K.** Screening for retinoblastoma; presenting signs as prognosticators of patients and ocular survival. Pediatrics. 2003; 112: 1248-55.