

Presentation of Ocular and Orbital Dermoid Cysts at Holy Family Hospital Rawalpindi

Sana Nadeem, Ali Raza

Pak J Ophthalmol 2012, Vol. 28 No. 2

See end of article for authors affiliations

Correspondence to:
Sana Nadeem
Department of Ophthalmology
Rawalpindi Medical
College/Holy Family Hospital
Rawalpindi

Purpose: To evaluate the presentation of dermoid cysts related to the eye and orbit, appropriate management and results.

Material & Methods: This prospective study was conducted in Department of Ophthalmology, Holy Family Hospital, Rawalpindi. A total of twenty eight (28) cases of dermoids presented to us from 1st January, 2007 to 1st December, 2011. CT scanning/MRI were done where deemed necessary and all lesions were confirmed on histopathology. Limbal dermoids were shaved off with conjunctival autografting or flap. Superficial dermoids were removed via appropriate skin incisions and for deep dermoids, we performed orbitotomies.

Results: Out of 28 cases of dermoids, 12 were limbal dermoids, 5 were superficial superonasal dermoids and 2 were superficial superotemporal, and 9 were deep orbital dermoid cysts. One superficial dermoid presented as a recurrence. Post-operative hematoma developed in one patient only. Follow up ranged from one month to four years.

Conclusion: Dermoid cyst en bloc excision is a relatively safe procedure with minimal complications. Recurrence can be effectively prevented by a careful evaluation and complete surgical removal.

Dermoid cysts are the most common congenital lesions of the orbit. They are developmental choristomatous tumors which are defined as normal tissue in an abnormal location. They are composed of derivatives of epithelial or connective tissue elements that are entrapped within facial clefts during embryogenesis, or from failure of separation of surface ectoderm from the neural tube. The solid or cystic masses are formed by proliferation of these cells¹. They represent 24% of all orbital and eyelid masses, 6 – 8 of deep orbital tumors and 80% of cystic orbital masses². Conjunctival dermoid cysts are solid choristomas², typically unilateral and located at the inferotemporal limbus.

They are well – defined slow growing painless lesions and have local mass effect on the bone with erosion and remodeling. Growth may be outward into the eyelid, noted typically in childhood, or inward into the orbital cavity, and hence presents later. Although congenital, only one fourth lesions are clinically

obvious at birth, the remaining presenting within the first year. Occasionally they present acutely after rupture simulating an acute inflammation with erythema, tenderness and swelling due to leakage of keratin³.

Mostly, dermoid cysts arise from keratinized squamous epithelium, but they may occasionally originate from the nonkeratinized conjunctival epithelium⁴. Treatment is complete surgical excision, following which recurrences are rare. The purpose of our study is to segregate dermoids according to their site and to manage them diagnostically and surgically using different surgical approaches and to evaluate the results.

MATERIAL AND METHODS

All patients with dermoid cysts presented to the ophthalmology department at Holy Family Hospital from 1st January, 2007 to 1st December, 2011 were included in this study. CT scan or MRI were

performed on all patients with orbital dermoids and all the lesions were confirmed on histopathology.

All limbal dermoids were superficial and removed by shave excision and conjunctival autografting or a sliding flap. The superficial medial orbital dermoids were excised via medial skin incision or frontoethmoidal (Lynch) incision. The superficial lateral dermoids were removed by sub-brow incisions. Deep orbital dermoids were removed with a lateral orbitotomy in six (6) cases and Lynch medial orbitotomy in one (1) case. In ten (10) cases, drainage was considered necessary before total removal. Follow-up ranged from one month to four years and there was no recurrence seen.

RESULTS

A total of 28 cases were diagnosed and treated, out of which 12 (42.9%) were limbal dermoids. Seven (25%) were superficial orbital, out of which 5 were medial (supero-nasal) orbital related to the frontoethmoidal suture and 2 were lateral (supero-temporal) orbital related to the zygomaticofrontal suture. Nine (32%) were deep orbital, out of which 5 were related to the zygomatico-frontal suture, one superior orbital fissure, one posterior ethmoido-sphenoidal suture and 2 were related to the trochlear fossa (Table 1) (Fig. 1).

Table 1. Location of Dermoid

Location	Frequency n (%)
Inferotemporal	12 (42.9)
Superotemporal	8 (28.6)
Superonasal	6 (21.4)
Temporal	2 (7.1)
Total	28 (100)

Limbal dermoids were all superficial and located on the inferotemporal limbus. Removal resulted in mild corneal thinning and scarring, but no lesion required keratoplasty. One case was diagnosed as Goldenhar syndrome.

Superficial medial and lateral dermoid cysts were present below the brow. Rupture occurred in four (4) cases and the area was irrigated with saline and a dilute steroid solution. There was one case of recurrent superficial lateral dermoid which was treated

successfully. Deep orbital cysts were difficult to excise with drainage being considered necessary to facilitate posterior wall removal. No significant postoperative inflammation was observed in any case.

All cysts were completely removed and sent for histopathology. They were found to be lined with stratified squamous epithelium, filled with keratin, sebaceous material and hair.

Patients were followed up for one month to four years to check for recurrences. One (1) patient developed a peri-ocular hematoma which spontaneously resolved.

DISCUSSION

Solid limbal dermoids are usually unilateral pale lesions² located most commonly at the inferotemporal limbus. Mostly they are superficial and deep extension into cornea, sclera and conjunctiva is a rarity. Treatment is shave excision, while lamellar or penetrating keratoplasty may be needed for deeper extension. Bilateral limbal dermoids are found in patients with Goldenhar's syndrome.

Orbital dermoids can present at any age from infancy to old age. A slow growing, painless, subcutaneous mass presents in 90% of cases. They are non-tender, fluctuant or firm, and enlarge slowly as they become filled with keratin and sebum. Deeper lesions usually symptomless initially, present later in life, in early adolescence or adulthood. Deep dermoids if enlarge sufficiently may result in proptosis, diplopia due to globe compression or motility restriction due to cranial nerve palsies (III, IV or VI)³. Decreased vision due to optic nerve compression is rare. Rarer still is its location within a rectus muscle⁵. They are usually unilateral with no predilection for laterality, gender or race.

In our study, limbal dermoids were greatest in frequency, followed by deep orbital dermoids and lastly, superficial dermoids. We found superficial orbital dermoids predominantly superonasally, however Cavazza et al⁶ in their study, found predominantly superotemporal dermoids and Sherman⁷ et al found equal number of medial and lateral dermoids in their study. Deep dermoids were mostly lateral in our study. Dermoids occur along the superotemporal orbital margin at the zygomatico-frontal suture in 75% of cases, although the frontoethmoidal suture, superonasally is the next most common site⁵. Other sites are frontonasal and frontolacrimal sutures.

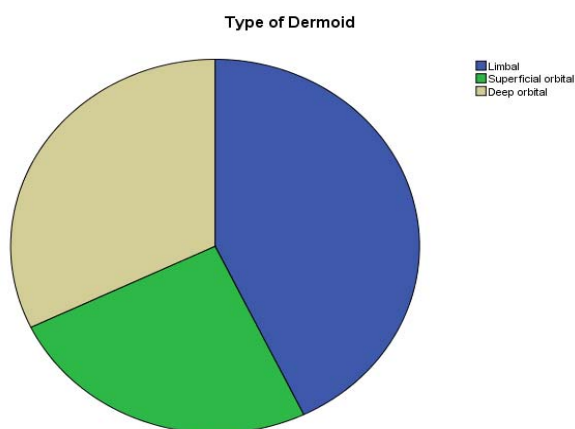


Fig. 1: Pie chart depicting percentages of types of Dermoid

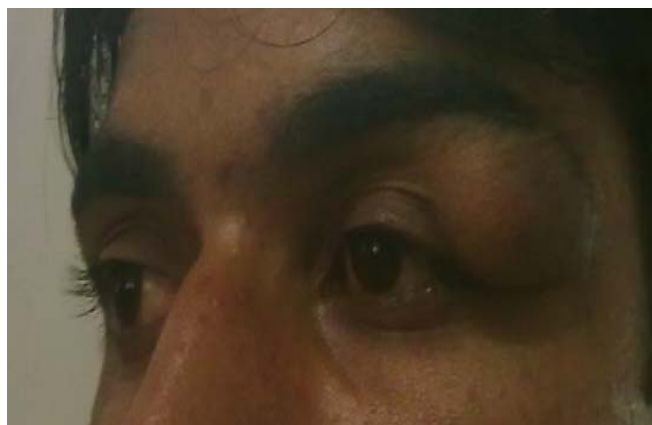

Fig. 2. A large left recurrent superficial orbital dermoid cyst

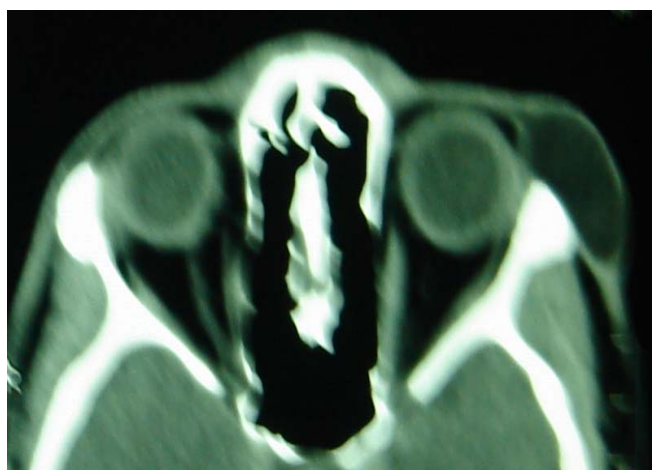

Fig. 3: CT scan depicting the same cyst

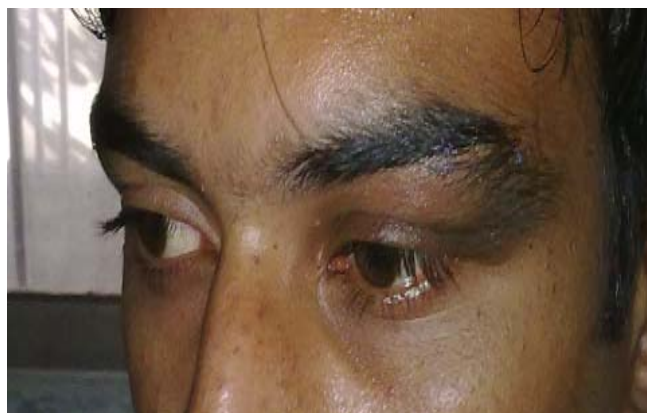

Fig. 4: Postoperative appearance at 3 weeks after excision

Dermoids are classified clinically into superficial or deep dermoids or exophytic and endophytic, according to their site of attachment in relation to the orbital rims⁸. Superficial dermoids lie subcutaneously anterior to the orbital septum and their posterior margins can be palpated easily. Deep lesions are located posterior to the orbital septum within the orbital cavity, discovered later in life when they produce bone damage, with or without invasion of the adjacent structures. Deep dermoids are often complicated and may be misdiagnosed due to extent and complexity. In order to distinguish between deep and superficial dermoids, a thorough investigation is necessary, since deep dermoids may extend beyond the orbit into the temporalis fossa or intracranially⁹. Also significant is the recognition of size, character, extension, and bony defects.

Histopathologically, dermoids are lined with keratinized, stratified, squamous epithelium with dermal appendages like hair follicles, sebaceous and eccrine glands and filled with keratin and sebaceous secretions. Rupture leads to intense inflammation mimicking orbital cellulitis. Histological evidence of leakage with inflammation has been found in more than half of these lesions¹⁰.

Ultrasonography reveals irregular internal structure on A-scan, with low to medium internal reflectivity, with the cyst wall being highly reflective. B-scan shows these lesions as round, smooth and well-defined with variable internal appearance¹¹ and occasional fluid levels. Excavation of adjacent bone or defects are frequent.

Management of dermoid cysts is complete surgical excision of the cyst wall and contents. Most lesions show leakage and associated inflammation on

histopathology. The risk of rupture increases with patient age and size of the cyst¹², due to thinning of the wall with increased size and also increased risk of trauma with age. Therefore, these should be removed early to prevent tissue fibrosis. The superficial lesions are managed by a direct approach over them with. An upper-eyelid incision provides adequate exposure of most orbital lesions¹³.

Recognition of clinical features and imaging findings of dermoids is essential and with the help of imaging examinations and the combination of various surgical skills, the recurrence of dermoid cysts can be effectively prevented.

CONCLUSION

To conclude, we clinically evaluated dermoid cysts which presented to us, calculated their frequency and investigated them with CT scanning/ MRI and managed them surgically and confirmed via histopathology. Enbloc dissection is the best method to remove these cysts with minimal complications.

Author's affiliation

Dr. Sana Nadeem
Senior Registrar
Department of Ophthalmology
Rawalpindi Medical College/
Holy Family Hospital, Rawalpindi

Dr. Ali Raza
Associate Professor
Head of Ophthalmology Department
Rawalpindi Medical College/
Holy Family Hospital, Rawalpindi

REFERENCE

1. **Apple DJ, Rabb MF.** Ocular Pathology. Fifth edition. Mosby: St Louis. 1998; 568.
2. **Yanoff M, Duker JS.** Ophthalmology. Second Edition. Mosby: St Louis. 2004; 397-740.
3. **Karcioglu ZA.** Orbital tumors: diagnosis and treatment. Springerlink: New York. 2005; 293-6.
4. **Dutton JJ, Fowler AM, Proia AD.** Dermoid cyst of conjunctival origin. Ophthal Plast Reconstr Surg. 2006; 22: 137-9.
5. **Howard GR, Nerad JA, Bonavolonta G, et al.** Orbital dermoid cysts located within the lateral rectus muscle. Ophthalmology. 1994; 101: 767-71.
6. **Cavazza S, Laffi GL, Lodi L, et al.** Orbital dermoid cyst of childhood: clinical pathologic findings, classification and management. Int Ophthalmol. 2011; 31: 93-7.
7. **Sherman RP, Rootman J, LaPointe JS.** Orbital dermoids: clinical presentation and management. Br J Ophthalmol. 1984; 68: 642-52.
8. **Bonavolontà G, Tranfa F, de Conciliis C, et al.** Dermoid cysts: 16-year survey. Ophthal Plast Reconstr Surg. 1995; 11: 187-92.
9. **Pfeiffer RL, Nicholl RJ.** Dermoid and epidermoid tumours of the orbit. Arch Ophthalmol. 1948; 40: 639.
10. **Shields JA, Kaden IH, Eagle RC Jr, et al.** Orbital dermoid cysts: clinicopathologic correlations, classification, and management. The 1997 Josephine E.
11. Schuleler lecture. Ophthal Plast Reconstr Surg. 1997; 13: 265-76.
12. **Traboulsi EI, Azar DT, Khattar J, et al.** A-scan ultrasonography in the diagnosis of orbital dermoid cysts. Ann Ophthalmol. 1988; 20: 229-32.
13. **Colombo F, Holbach LM, Naumann GO.** Chronic inflammation in dermoid cysts: a clinicopathologic study of 115 patients. Orbit. 2000; 19: 97-107.
14. **Bartlett SP, Lin KY, Grossman R, et al.** The surgical management of orbitofacial dermoids in the pediatric patient. Plast Reconstr Surg. 1993; 91: 1208-15.