

Graded Recession for Primary Inferior Oblique Over Action

Asad Ali Asim, Sharif Hashmani, Muhammad Ather Jamil, Captain Muhahmmad Zaheer

Pak J Ophthalmol 2012, Vol. 28 No. 3

See end of article for authors affiliations

Correspondence to:
Asad Ali Asim
Senior Consultant
Ophthalmologist
Lakson Medical Trust
Sahiwal

Purpose: To evaluate the results of graded recession of inferior oblique for primary inferior oblique over action.

Material and Methods: Ten patients were selected from OPD of Lakson Medical Trust, Sahiwal having primary inferior oblique over action with V pattern of more than 5 degrees. Bilateral graded inferior oblique recession was carried out using a Fink's caliper. Final follow-up was at one year.

Results: Mean age of the patients was 15.7 years. Mean Pre operative V pattern was 7.5 degrees (15PD). Mean post operative V pattern was 1.6 degrees (3.2 PD). Mean pre-op extorsion in primary position was 4.3 degrees. It was decreased to mean post operative value of 1.3 degrees. Cyclo vertical diplopia was also corrected that was present in one patient.

Conclusions: Graded inferior oblique recession by Fink's Method is an effective procedure to correct cyclo vertical deviations due to Primary inferior oblique over action. It also improved cyclovertical diplopia in few cases.

Primary Inferior Oblique over action (PIOOA) is usually associated with horizontal strabismus such as congenital esotropia or intermittent exotropia. Isolated PIOOA can occur without associated horizontal strabismus. Although PIOOA is bilateral in most of the cases but it is usually asymmetrical. Since the inferior oblique muscle is an elevator, abductor and extortor (the primary action of inferior oblique being extorsion), these elements are exaggerated in direct proportion to over action. There is typical upshoot of adducting eye and shows V-Y pattern. In case of Y pattern there may be little or no change in deviation in down gaze. Bagolini test may reveal fusion in down gaze and diplopia in upgaze^{1,7}. Asymmetry can cause vertical deviation (VD) and extorsion. Indirect ophthalmoscopy may show significant fundus extorsion in both primary and secondary inferior oblique over action. One of the main secondary cause of IO over action is trochlear nerve palsy. PIOOA should be differentiated from trochlear palsy where vertical deviation (VD) is incomitant and exocycloptropia is maximum in downgaze³. Park 3 step test is also important to isolate paretic muscle in case of vertical deviation/diplopia.

PIOOA should also be differentiated from pseudo V due to DVD (Dissociated Vertical Deviation) and Duane syndrome. Pseudo V may be present in intermittent exotropia with poor control in upgaze¹. It is necessary to treat V pattern when child is adapting abnormal head position and having some fusional potential. The V patterns associated with exotropia are more cosmetically disturbing particularly in up gaze⁸.

Inferior oblique surgery is indicated in V pattern larger than 5 degrees. Many surgical procedures for weakening of inferior oblique have been described including graded recession, anteriorization, myectomy, disinsertion, denervation, extirpation and Z-myotomy^{1,2,7,8}.

Graded recession is very logical approach to treat PIOOA according to its severity. Grades are 8 mm, 10 mm and maximum recession (Fig. 1, 2). In maximal recession anterior portion of muscle is attached at lateral side of insertion of inferior rectus muscle. Maximum amount is an average 14.6 mm recession². Graded IO recession by Fink's method is designed to correct cyclovertical deviations due to inferior oblique over action^{2,3,14}. The effectiveness of graded recession

of inferior oblique for PIOA was evaluated in this study.

MATERIALS AND METHODS

Ten patients with primary inferior oblique over action with V pattern of more than 5 degrees were selected from OPD of Lakson Medical Trust Hospital, Sahiwal from February 2006 to June 2007. Detailed orthoptic assessment was carried out which included examination for chin up/down, head tilt, nystagmus and A, V or X pattern. Horizontal and vertical deviations were measured by using prism cover test (PCT). PCT was done with full correction in place at 6 meters in primary position, 30° chin up, 20° chin down, right, left and near fixation. Finding of PCT were described in prism diopters, which were converted into degrees by taking half of its value. Cyclo-torsions were measured by using double Maddox rod test in primary position.

Versions were also checked for over action of inferior oblique. Pseudo V was excluded by relying on prism cover test (PCT). It was also differentiated from trochlear palsy where vertical deviation (VD) is incomitant and exoclotropia is maximum in down gaze. Park 3 step test was done in routine to isolate paretic muscle in case of vertical deviation/diplopia. All the patients who were clinically diagnosed as V pattern more than 5 degrees due to PIOA associated with either exotropia (Exo) or esotropia (Eso) were included in the study. Patients with poor fixation, coexisting DVD and associated congenital ptosis were excluded from the study.

Bilateral graded IO recession was done by using Fink's caliper along with horizontal corrections. For 5-10 degrees V pattern, 8 mm recession was done. Fink's Point defines 8 mm recession (Fig.1, 2)^{2,14}. For 10-15 degrees V pattern 10 mm recession was performed. For more than 15 degrees of V pattern, maximal recession was done. Co-existing horizontal deviations (Exo/Eso) were also corrected according to measurements in primary position by performing surgery on horizontal muscles. The data, measurements of horizontal deviations and post-operative results were not included in the study.

Surgical procedure

Incision was made by grasping inferolateral conjunctival fold adjacent to lateral canthus. Squint hook was passed under insertion of lateral rectus, tenon was dissected, IO muscle was localized, grasped

and cut from its distal end where it inserts by a short tendon onto posterolateral part of globe along the inferior border of lateral rectus muscle. Vicryl 6/0 suture was passed through anterior portion of IO muscle and reinserted onto sclera according to Fink's measurements. Graded recession was done according to pre op evaluation of V pattern. One end of Fink's caliper was placed at lateral rectus insertion; other end marked the Fink's point. Fink's Point defines 8mm recession. (Fig 1, 2). In 10 mm recession the anterior part of IO muscle was reattached 2 mm from fink's point on a line connecting fink's point and the lateral insertion of inferior rectus. In maximal recession, anterior portion of muscle was attached at lateral side of insertion of inferior rectus muscle.

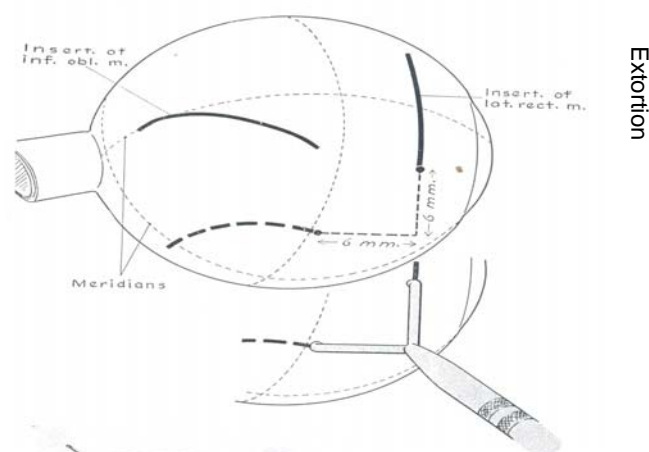


Fig. 1: Fink's point¹⁴

Scanned from Fink WH: Surgery of the Oblique Muscles of the Eye. First edition, St. Louis, C.V.Mosby, 1951.

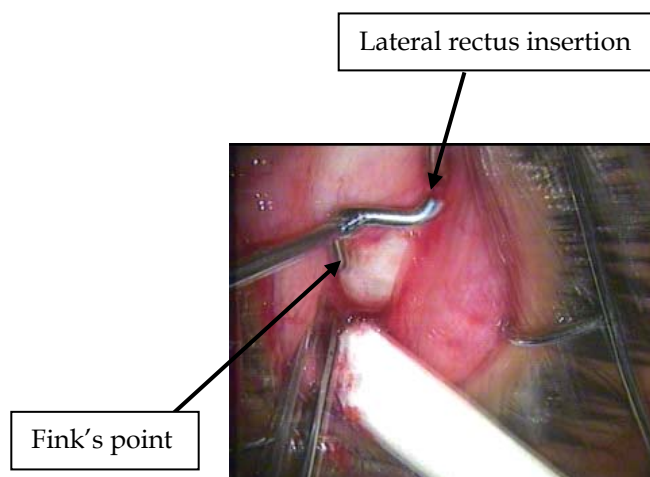


Fig 2. Use of Fink's caliper in surgical procedure of Graded Inferior Oblique recession.

Follow up was at post op day 1, one week, 2 weeks, 6 months and one year. The post op measurements taken at six months and one year were found to be stable. While comparing preoperative and post-operative results, post op values at one year follow up were considered.

RESULTS

Mean age of the patients was 15.7 years. Mean pre-op V pattern was 7.5 degrees (15PD). Although we found correction of V pattern and reduction of extortion on the 1st post- op day and one week as shown in Fig.5. Mean post op V pattern is 1.6 degrees (3.2 PD), (Fig 3). Mean correction of V was 5.9 degrees (11.8 PD).

Mean pre-op extortion in primary position was 4.3 degrees. It was decreased to mean post-op value of 1.3 degrees (Fig. 4).

One patient was suffering from cyclo vertical diplopia. On Bagolini testing this patient was fusing in downgaze and described diplopia in upgaze preoperatively. Diplopia was corrected after surgery in addition to correction of V pattern.

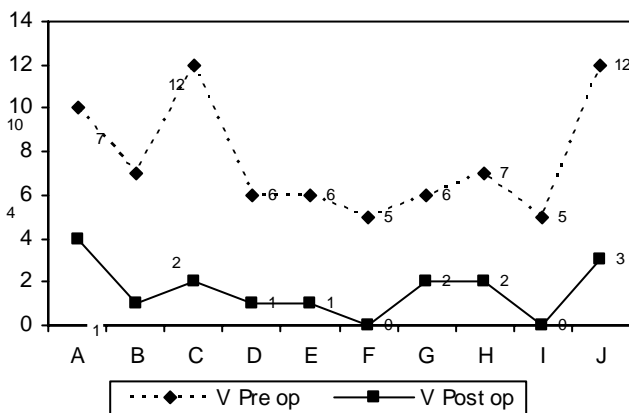


Fig 3: Comparing amount (in degrees) of Pre op and post op V pattern. (Names of patients are not acceptable ethically, label as pat A to J, Label Y axis of graph): done

DISCUSSIONS

In our study, grades of recession were designed according to severity of inferior oblique over action. Amount of V pattern determined the grade of recession. It is more logical than doing myectomy for all cases of V pattern⁸. Although different methods of grading IO recession have been mentioned in the literature⁷ but we used Fink’s method^{2,14}. During recession, anterior portion of inferior oblique tendon was reinserted on sclera and posterior portion was left

loose hanging on posterior check ligament. Posterior portion would self adapt by sliding backwards. In our study 10 patients were treated. Mean age was 15.7 years. Mean correction of V pattern was 5.9 degrees. Mean correction of extortion was 3 degrees. Our results showed correction of cyclovertical deviation and improved cosmesis. It also eliminated diplopia in a case where fusion was present.

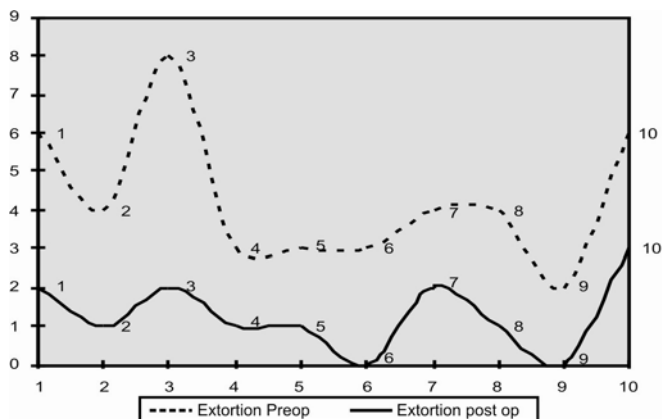


Fig. 4: Comparison of Pre op and post op Extortion in degrees. Patients Label X and Y axis of graph (done)

Kamlesh et al showed mean preoperative V pattern as 38.3 PD (19.15 degrees) and mean post- op residual V pattern was 11.4 PD (5.70 degrees). Mean correction of V was 26.9 PD (13.45 degrees)⁴. Residual V in this study is 3.2 PD (1.06 degrees) which is quiet low. Kamlesh et al selected very large amount of V pattern and did 10 mm recession in all cases while in this study, IO recession was done according to degree of V pattern.

Akar et al selected patients with mean V pattern of 27.7 PD. Mean post-op V was 9.6PD (4.8 degrees). Mean change in V pattern was 18.6 PD (9.3 degrees). They performed a variety of surgical procedures on inferior oblique like myotomy, myectomy, recession and anterior transposition⁵.

Cooper and Sond all reported that IO recession led to a correction of V pattern of 11.96 PD (5.98 degrees) with a residual over correction of 3.11 PD¹⁰. Our study shows mean correction of V pattern of 11.8 PD (5.9 degrees) with no over correction.

Burian et al reported an average change of 15.4 PD (7.7 degrees) in V pattern esotropia and an average change of 11.47 PD (5.85 degrees) in V pattern exotropia with a residual V of 9.13 PD (4.56 degrees) and 14.07 PD (7.03 degrees) respectively.

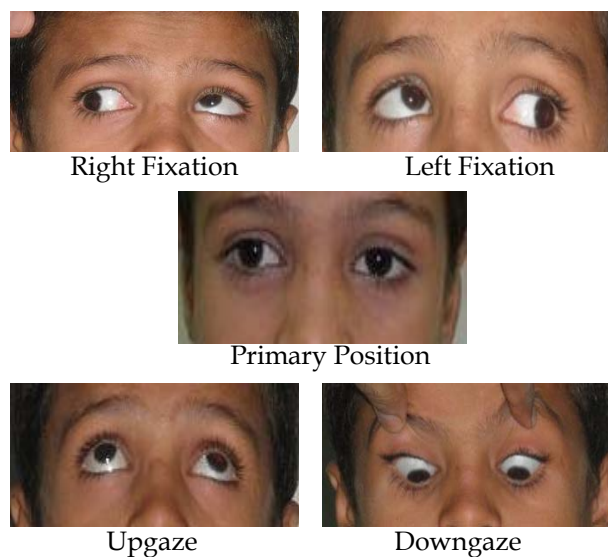


Fig 5: (Preop). A 8 years old boy suffering from PIOOA. **Primary position** shows Exotropia; **Right fixation:** Left Eye in adduction shows IO overaction.

Left fixation: Right Eye in adduction shows IO over action. **Upgaze/downgaze:** Exotropia increases in upgaze and decreases in primary position and further in down gaze manifesting V pattern.

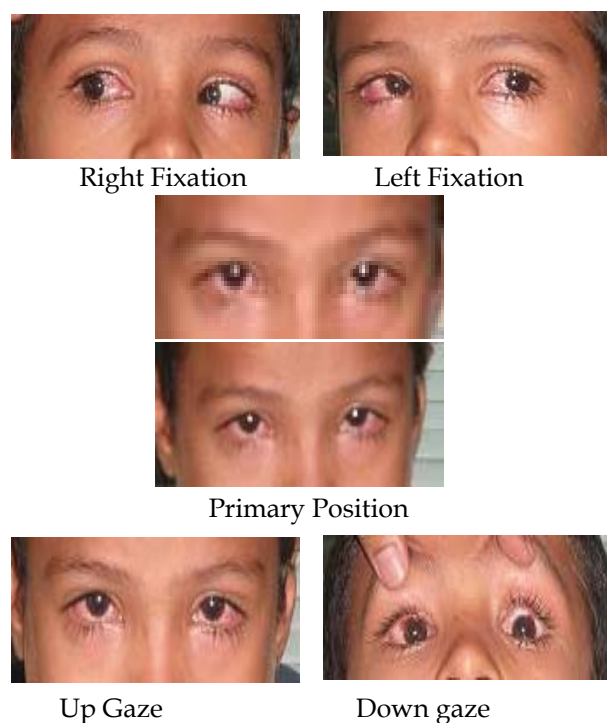


Fig 6: Post operative (1 Week): Orthotropic in **primary position**. **Right and left fixation** shows almost no IO over action and excessive Extortion. **Upgaze and downgaze** shows correction of V pattern

In the series of Costanbader and Kertey, Fink's 8 mm recession lead to an average correction of 2.2 U of IOOA (I U: 1-9 PD)⁶. In both Burian et al and Costanbader and Kertey studies postoperative V pattern is comparable to that in our studies.

Baker et al reported decrease in Inferior oblique over action (IOOA) and extorsion after IO weakening procedures. They graded both IO over action and fundus extorsion from 0 to 4. They used Inferior oblique recession as a primary procedure. They performed Extirpation and disinsertion as a second procedure for residual IOOA¹³. We also found decrease in amount of V pattern that is proportional to IO over action. We also found decrease in extorsion. In the sense our results are comparable with Baker et al. Some authors also reported recurrence, post-op hypotropia, adherence syndrome and internal ophthalmoplegia. However we did not get any of these complications^{11,12}.

CONCLUSIONS

Graded IO recession by Fink's Method is an effective procedure to correct cyclo vertical deviations due to primary Inferior oblique over action. It also improves cyclovertical diplopia in selective cases.

Author's affiliation

Dr. Asad Ali Asim
Senior Consultant Ophthalmologist
Lakson Medical Trust
Sahiwal

Dr. Sharif Hashmani
Medical Director
Lakson Medical Trust
Sahiwal

Dr. Muhammad Ather Jamil
Ophthalmologist
Lakson Medical Trust
Sahiwal

Dr. Captain Muhahmmad Zaheer
Senior Medical Officer
Lakson Medical Trust
Sahiwal

REFERENCE

1. **Wright KW.** Oblique dysfunction and A and V pattern; In: strabismus and pediatric Ophthalmology; 2nd Edition, Baltimore; William and Wilkins; 1997: 297-309.

2. **Boergan KP, Ali AL, Shworm HD.** Effect of Maximal Inferior Oblique recession in V pattern. Trans 22nd ESA meeting, Cambridge, UK. 1995: 147-152.
3. **Boergan KP, Arzt M, Schworm HD.** Results of Different Surgical procedures in trochlear palsy. Trans 23rd ESA meeting, Farance. 1996: 289-92.
4. **Kamlesh, Dadeya S, Kohli V, et al.** Primary Inferior Oblique over action management by Inferior Oblique recession. Indian J Ophthalmol. 2002; 50: 97-101.
5. **Akar S, Gokyigit B, Eren A, et al.** Efficiency of Bilateral Inferior Oblique procedure in V pattern Strabismus. Trans 32 ESA meeting, Munich, Germany. 2008; 253-6.
6. **Costonbadar FD, Kertey E.** Relaxing procedure of inferior Oblique. Am J Ophthalmol. 1964; 57: 276-80.
7. **Plager AD, Buckley EG, Repka MX, et al.** Oblique Dysfunction; In: Strabismus surgery basics and advanced strategies, First Ed. New York: Oxford Press. 2004: 40-44.
8. **Pratt-Jhonson JA, Tilson G. A,V and X Patern Strabismus.** In: Management of Strabismus and Amblyopia,a practical guide, First ed. NewYork; Thieme Medical Publishers. 1994: 138-142.
9. **Masaya-anon P, Subhangkasen I, Hiriotappa J.** The Surgical outcome of Inferior Oblique Recession on Bilateral Superior Oblique palsy in children: J Medical Association Thai. 2009; 92: 217-23.
10. **Cooper EL, Sondall GS.** Recession versus free myotomy at the insertion of IO muscle. J pediatr Ophthalmol. 1969; 6: 6-10.
11. **Burian H Symposium.** The A and V patterns in strabismus Treatment. Trans. Am Acad Ophthalmol Otolayng. 1964; 68: 375-80.
12. **Parkash P, Menon V Nath J.** Surgical management of A and V pattern. Indian J Ophthalmol. 1983; 31: 463-65.
13. **Baker JD, MacFarlane WA.** Effectiveness of Inferior Oblique Surgery. Trans 30th ESA meeting; Ireland: 125-6.
14. **Fink WH.** Surgery of the Oblique Muscles of the Eye. First edition, St. Louis, C.V. Mosby. 1951.