

# Safety of 23 Gauge Transconjunctival Sutureless 3 Port Pars Plana Vitrectomy for Vitreoretinal Diseases

Syed Raza Ali Shah, Nadeem Ahmad, Qasim Lateef Chaudry, Chaudary Nasir Ahmad, Asad Aslam Khan

*Pak J Ophthalmol 2013, Vol. 29 No. 3*

See end of article for authors affiliations

Correspondence to:  
Syed Raza Ali Shah, Associate Professor, Ophthalmology Department, King Edward Medical University, Vitreo-Retinal Fellow, College of Ophthalmology & Allied Visual Sciences, Mayo Hospital Lahore.

**Purpose:** To evaluate the safety of 3 port pars plana 23 gauge transconjunctival sutureless vitrectomy for vitreoretinal diseases.

**Material and Methods:** A prospective study was conducted at the Institute of Ophthalmology, Mayo Hospital Lahore from July 2010 to December 2010. All patients were admitted in the eye ward from the outpatients department. Total 30 patients were included in the study. Male to female ratio was 70:30. Mean age of patients was 45.5 years. Those included had idiopathic epiretinal membrane (ERM), diabetic vitreous hemorrhage, traumatic vitreous haemorrhage, vitreous haemorrhage secondary to Eale's disease, diabetic macular edema, macular hole, Diabetic (tractional retinal detachment) TRD and dislocated lens. Outcome measures were recorded at baseline, 1 day, 1 week and 1 month, 2 months and 3 months post operatively. Applanation tonometry, intra & post-operative complications, ancillary tests such as ocular coherence tomography (OCT) and ultrasound were done as required.

**Results:** Intra-operative complications noted were retinal tear 9% (2.7 patients), lens touch 4% (1.2 patients), sclerotomy leak requiring stitches 35% (10.5 patients), conjunctival hemorrhage 31% (9.3 patients), cannula slippage 13% (3.9 patients), entry site break 4% (1.2 patients) and retinal touch 4% (1.2 patients). First day post-operative complications were hypotony 20%, conjunctival inflammation 30%, mild eye discomfort 23.3% & corneal edema 13.3%. No complication was noted on 7<sup>th</sup> post operative day.

**Conclusion:** This study showed that procedure is safe and can be adopted in different vitreoretinal procedures. It is minimally invasive surgical technique that enhances the postoperative recovery and outcomes by simplifying the surgical procedure.

Twenty-three gauge instrumentation offer advantages in fluidics, providing retinal stability in all of the surgeries. The benefits of patient comfort are important. However, anatomic and visual outcomes, which are superior after this surgery, are even more important. The first - generation 23-G trocar-cannulas had high insertion force, which

created stabilization issues. The second-generation trocar-cannulas have low insertion force, roughly equivalent to that of a 20-G microvitreoretinal (MVR) blade, so stabilization of the eye is no longer a problem.<sup>1</sup> The surgeon clearly benefits from these smaller - gauge systems compared to the more invasive systems. The capabilities of the systems have

evolved significantly, specifically the rigidity of instrumentation and the lighting. Surgery with 23-G instruments, however, is very similar to surgery with 20-G instruments.<sup>2</sup> 23-G system addresses many of the initial concerns, which have been related to instrument availability and sclerotomy site closure.<sup>3</sup> The advantages of 23 – gauge sutureless trans-conjunctival vitrectomy compared to conventional 20 – gauge vitrectomy are shorter surgical<sup>4,5,6</sup> and recovery time<sup>4</sup> and less postoperative discomfort.

The purpose of the study was to describe the initial experience, effectiveness and safety profile of 23 gauge transconjunctival sutureless vitrectomy for various vitreo-retinal diseases.

Safety was defined as the incidence of per-operative complications such as lens touch, entry site retinal break, retinal touch, sclerotomy site requiring stitches, choroidal detachment, cannula slippage, conjunctival haemorrhage, incidence of post-operative complications such as hypotony, corneal edema, endophthalmitis, conjunctival scarring and eye discomfort.

## MATERIAL AND METHODS

This study was carried out at College of Ophthalmology and Allied Vision Sciences / King Edward Medical University, Mayo Hospital Lahore from July 2010 till December 2010. The patients were admitted from Eye OPD of Mayo Hospital Lahore. Thirty eyes were included in this study using non-probability convenience sampling technique. It was prospective, non-comparative, interventional study. Those included in the study had epiretinal membranes (Idiopathic ERM), macular hole, non-clearing vitreous hemorrhage, lens or fragments dislocated in the vitreous, vitreomacular traction and diabetic macular edema. Those excluded were patients with TRD, Intra ocular foreign body and rhegmatogenous RD and those requiring silicon Oil injection. Equipment used was Muller's Microscope / Leica's Microscope with BIOM, Accurus / Millennium vitrectomy machines, 23 – gauge system (Infusion cannula, Fiberoptic Endoilluminator, Vitrectomy cutter, trocar cannulas set, MVR Blade) and Gas (C3F8 / SF6).

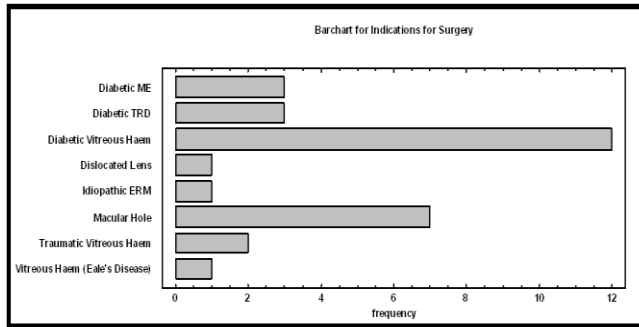
Informed consent was taken before surgery. Data abstract included patient's age, sex, date of admission, date of operation, date of discharge, address, presenting complaints, pre-operative record, indication for surgery, investigations, probable diagnosis, incidence of intra-operative complications

such as lens touch, entry site retinal break, retinal touch, sclerotomy site requiring stitches, choroidal detachment, cannula slippage and conjunctival haemorrhage, incidence of post-operative complications such as hypotony, corneal edema, endophthalmitis, conjunctival scarring and eye discomfort. These post-operative complications were noted on post-operative day 1, 1<sup>st</sup> week, 1<sup>st</sup> month, 2<sup>nd</sup> month and 3<sup>rd</sup> month.

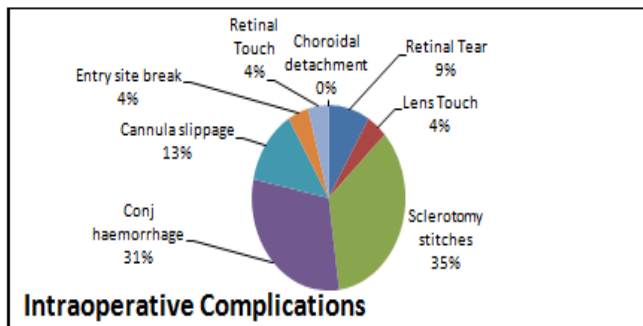
A 23 – gauge 3 – port vitrectomy setup was used for all cases. A drop of adrenaline was instilled to prevent conjunctival haemorrhage as vessels got blanched. The conjunctiva was displaced with the tooth forceps and to make eye stable. The 23 – gauge MVR keratome was inserted through the conjunctiva and sclera, parallel to the limbus, at an angle of approximately 20° to the sclera, 3.5/4.0mm posterior to the limbus. On the blunt micro trocar 6 mm cannula was fixed and inserted through the hole already made by 23G MVR blade while maintaining apposition of the conjunctival and scleral openings. 6 mm cannula was inserted and micro trocar removed. That produced a tunnel incision through the sclera. After the distal part of the blunt trocar was inserted, the direction of the trocar was angled to be normal with the eye, and the cannula was fully inserted. It was very important to look through the pupil for proper entry. Once cannula was properly inserted, infusion line was opened that prevented hypotony while making 2<sup>nd</sup> and 3<sup>rd</sup> sclerotomy ports. In a similar fashion 2<sup>nd</sup> sclerotomy port was made 3.5/4.0mm from the limbus just superior to the infusion cannula. After injecting the 2<sup>nd</sup> 6mm cannula it was again visualized for proper placement. It was plugged to prevent hypotony when 3<sup>rd</sup> sclerotomy port was made. Three port trans-conjunctival sutureless pars plana vitrectomy was done and in the end the cannulas were removed and wound secured.

## RESULTS

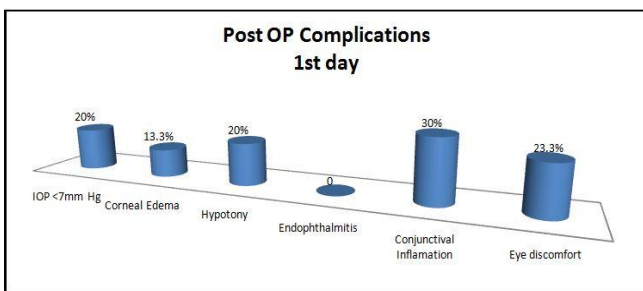
Thirty eyes of 30 patients were operated at the Institute of Ophthalmology, Mayo Hospital Lahore. The average age of the patients was 45.5 years ranging from 10 years to 80 years. Male to female ratio was 70:30. Total mean hospital stay was 3 days ranging from 2 to 4 days. The patients selected for surgery had different indications, idiopathic ERM 1 eye, diabetic vitreous hemorrhage 12 eyes, traumatic vitreous haemorrhage in 2 eyes, vitreous haemorrhage secondary to cataract's disease in 1 eye, diabetic macular edema was present in 3 eyes, macular hole 7 eyes, diabetic TRD 3 eyes and dislocated lens in one eye.




**Fig. 1:** Shows the maximum number of cases were of diabetic vitreous haemorrhage (12), followed by macular hole (7), 3 cases each for DME and diabetic TRD, 2 having traumatic vitreous haemorrhage and 1 each having dislocated lens, idiopathic ERM and vitreous haemorrhage secondary to eales disease.



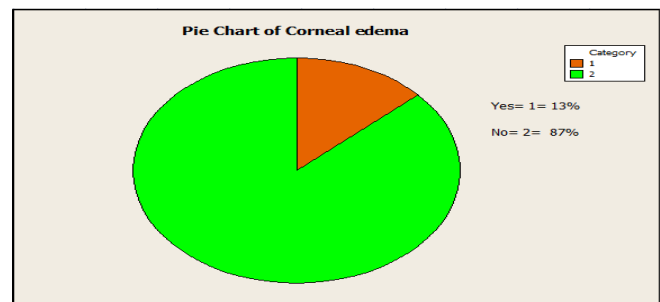
**Fig. 2:** Intra Operative Complications. Shows 35% (8 cases) required sclerotomy stitches, 31% (7 cases) had sub-conjunctival haemorrhage, 13% (3 cases) had cannula slippage, 9% (2 cases) retinal tear, 4% (1 case) each had lens touch, entry site break and retinal touch



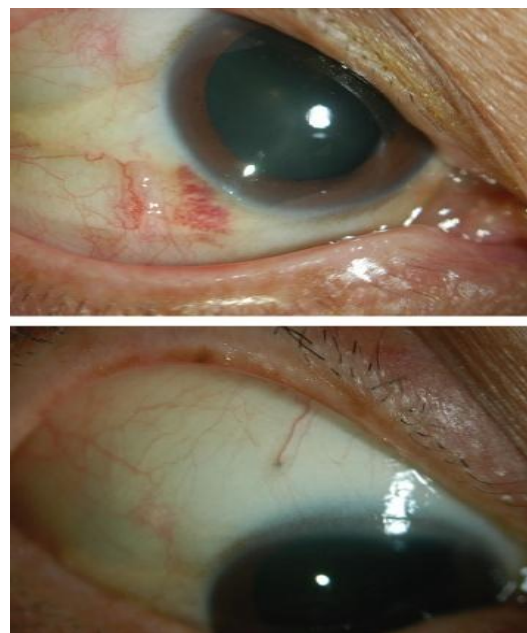
**Fig. 3:** Post Op Complications on day 1. Shows the post op complications 1<sup>st</sup> post op day. Conjunctival inflammation was noted in 9 cases (30%), mild eye discomfort noted in 7 cases (23.3%), 6 eyes (20%) had each IOP < 7 mmHg and hypotony and 4 cases (13.3%) had corneal edema. All eyes were normal on 7<sup>th</sup> post op day.



**Fig. 4:** IOP 1<sup>st</sup>post operative day. Shows only 6 cases had IOP below 7mm Hg on 1<sup>st</sup> post op day and all of them settled the very next day and no suture was required.



**Fig. 5:** Corneal edema 1<sup>st</sup> post op day. Show that 13% (4 cases) had corneal edema on 1<sup>st</sup> post op day. All of them settled on 7<sup>th</sup> post op day.



**Fig. 6:** Shows conjunctival inflammation 1 day and 7 day post operatively

Intra-operative complications noted were retinal tear in 2 eyes, lens touch in 1 eye, sclerotomy leak requiring stitches in 8 eyes, conjunctival hemorrhage in 7 eyes, cannula slippage in 3 eyes, entry site break in 1 eye and retinal touch in 1 eye.

Post Operative complications noted were hypotony at 1<sup>st</sup> day in 6 eyes (having IOP less than 7 mm of Hg) which resolved spontaneously in all eyes. Conjunctival inflammation was noticed in 9 eyes and ocular discomfort was of mild nature was noted in 7 eyes at 1<sup>st</sup> postoperative day, which was not seen after 1 week in any of the cases. No case developed endophthalmitis. Fig 1: Indications for Surgery.

## DISCUSSION

In our study, 6 out of 30 eyes (20%) received a gas tamponade, 35% (8 eyes) required suture to the 23 – gauge sclerotomy site at the time of surgery due to leakage of gas / air, 13% (3 eyes) had cannula slippage during surgery, 31% (7 eyes) had sub-conjunctival haemorrhage which settled on 7<sup>th</sup> post op day, 9% (2 eyes) retinal tear which required silicon oil injection, 4% (1 eye) had crystalline lens touch from the infusion cannula. The patient was operated for cataract surgery 2 months following vitrectomy, 1 eye had entry site break for which cryo was applied and retina was stable after 3 months of follow-up. One eye had retinal touch in which endolaser with gas tamponade was given with face down position for 5 days, retina remained stable after 3 months follow-up. Six eyes had hypotony on postoperative day 1(having IOP less than 7 mm of Hg) and on 2<sup>nd</sup> day hypotony settled and no surgical intervention was required. No eyes developed choroidal effusions or endophthalmitis.

Two eyes were treated with topical and / or oral medications for relatively high postoperative pressures secondary to intraocular gas tamponade or from use of topical prednisolone acetate. Two eyes required one of the sclerotomies to be converted to 20 gauge for injection of silicon oil. These 2 eyes were those which had iatrogenic retinal tears during segmentation of diabetic TRD. Conjunctival inflammation was noted in 30% (9 eyes), which settled on 7<sup>th</sup> post- operative day. Eye discomfort was of mild nature noted in 23% (7 eyes) at 1<sup>st</sup> postoperative day, which was not seen after 1 week in any of the eyes. Of the 30 eyes, 17 eyes were phakic, 10 eyes were pseudophakic, 1 eye was aphakic and 2 had cataract. Per-operatively cataract was removed and IOL was

implanted in them to get clear retinal view. Total mean hospital stay of patients was 3 days ranging from 2 to 4 days. The patients selected for surgery had different indications, idiopathic ERM 1 patient, diabetic vitreous hemorrhage 12 patients, traumatic vitreous haemorrhage in 2 eyes, vitreous haemorrhage secondary to Eale's disease in 1 patient, diabetic macular edema was present in 3 patients, macular hole 7 patients, diabetic TRD 3 patients and dislocated lens in vitreous 1 patient.

Howard F. Fine<sup>5</sup> in their study showed 2 patients had hypotony on postoperative day 1, 1 patient required suturing of sclerotomy peroperatively, and no patient developed choroidal effusions. Ashraf M et al<sup>8</sup> in his study showed that 4 eyes (13.3%) required suturing of sclerotomy intraoperatively, conversion to 20-gauge was done in one eye (3.3%), hypotony was reported in one eye (3.3%) postoperatively & sub-conjunctival silicone oil was reported in one eye (3.3%).

Sutureless posterior segment surgery provides numerous potential advantages over traditional 20-gauge vitrectomy, including faster wound healing, diminished conjunctival scarring, improved patient comfort, decreased postoperative inflammation, and reduced postoperative astigmatic change.<sup>9-17</sup>

## CONCLUSION

The transconjunctival 23-gauge vitrectomy approach appears effective for sutureless transconjunctival posterior segment surgery with an acceptable safety profile. Rates of sclerotomy leakage, hypotony, and choroidal detachment were favorable compared with previously published data. Rates of intraoperative and postoperative retinal tears and detachments also appeared comparable to rates for 23-gauge systems. The 23-gauge transconjunctival sutureless vitrectomy system is an effective and safe technique for a number of vitreoretinal procedures that enhances the postoperative recovery by simplifying the surgical procedure. It appears to be a less traumatic and more convenient alternative to 20-gauge vitrectomy.

### Author's Affiliation

Dr. Syed Raza Ali Shah  
College of Ophthalmology & Allied Visual Sciences,  
Institute of Ophthalmology, King Edward Medical  
University / Mayo Hospital Lahore

Dr. Nadeem Ahmad

College of Ophthalmology & Allied Visual Sciences,  
Institute of Ophthalmology, King Edward Medical  
University / Mayo Hospital Lahore

Dr. Qasim Lateef Chaudry

College of Ophthalmology & Allied Visual Sciences,  
Institute of Ophthalmology, King Edward Medical  
University / Mayo Hospital Lahore

Dr. Chaudary Nasir Ahmad

College of Ophthalmology & Allied Visual Sciences,  
Institute of Ophthalmology, King Edward Medical  
University / Mayo Hospital Lahore

Prof. Asad Aslam Khan

College of Ophthalmology & Allied Visual Sciences,  
Institute of Ophthalmology, King Edward Medical  
University / Mayo Hospital Lahore

## REFERENCES

1. **Charles S.** Innovative approaches to small-gauge vitrectomy surgery. *Retinal Physician*. 2007.
2. **Fang SY, Deboer CM, Humayun MS.** Performance analysis of new - generation vitreous cutters. *Graefes Arch Clin Exp Ophthalmol*. 2007; 18.
3. **Timothy G Murray.** Innovative approaches to small-gauge vitrectomy surgery. *Retinal Physician*. 2007.
4. **Chen E.** 25 - Gauge transconjunctival sutureless vitrectomy. *Curr Opin Ophthalmol*. 2007; 18: 188-193.
5. **Fine HF, Iranmanesh R, Iturralde D, Spaide RF.** Outcomes of 77 consecutive cases of 23-gauge transconjunctival vitrectomy surgery for posterior segment disease. *Ophthalmology*. 2007; 114: 1197-1200.
6. **Oshima Y, Ohji M, Tano Y.** Surgical outcomes of 25-gauge transconjunctival vitrectomy combined with cataract surgery for vitreoretinal diseases. *Ann Acad Med Singapore*. 2006; 35: 175-80.
7. **Lakhanpal RR, Humayun MS, de Juan Jr E, Lim JI, Chong LP, Chang TS et al.** Outcomes of 140 consecutive cases of 25-gauge transconjunctival surgery for posterior segment disease. *Ophthalmology*. 2005; 112: 817-24.
8. **Ashraf M.** El-Batarny Department of Ophthalmology, Magrabi Eye and Ear Hospital, Muscat, Sultanate of Oman. 2009 Web Published "Transconjunctival sutureless 23 - gauge vitrectomy for vitreoretinal diseases: Outcome of 30 consecutive cases".
9. **Chen JC.** Sutureless pars plana vitrectomy through self-sealing sclerotomies. *Arch Ophthalmol*. 1996; 114: 1273-5.
10. **Milibak T, Suveges I.** Complications of sutureless pars plana vitrectomy through self-sealing sclerotomies. *Arch Ophthalmol*. 1998; 116: 119.
11. **Kwok AK, Tham CC, Lam DS, Li M, Chen JC.** Modified sutureless sclerotomies in pars plana vitrectomy. *Am J Ophthalmol*. 1999; 127: 731-3.
12. **Schmidt J, Nietgen GW, Brieden S.** Self-sealing, sutureless sclerotomy in pars plana vitrectomy. *Klin Monatsbl Augenheilkd*. 1999; 215: 247-51.
13. **Jackson T.** Modified sutureless sclerotomies in pars plana vitrectomy. *Am J Ophthalmol*. 2000; 129: 116-7.
14. **Assi AC, Scott RA, Charteris DG.** Reversed self-sealing pars plana sclerotomies. *Retina*. 2000; 20: 689-92.
15. **Rahman R, Rosen PH, Riddell C, Towler H.** Self - sealing sclerotomies for sutureless pars plana vitrectomy. *Ophthalmic Surg Lasers*. 2000; 31: 462-6.
16. **Theelen T, Verbeek AM, Tilanus MA, van den Biesen PR.** A novel technique for self - sealing, wedge - shaped pars plana sclerotomies and its features in ultrasound biomicroscopy and clinical outcome. *Am J Ophthalmol*. 2003; 136: 1085-92.
17. **Fujii GY, De Juan E, Humayun MS, et al.** Initial experience using the transconjunctival sutureless vitrectomy system for vitreo-retinal surgery. *Ophthalmology*. 2002; 109: 1814-20.