

Smart Phone: A Smart Technology for Fundus Photography in Diabetic Retinopathy Screening

Ahmad Zeeshan Jamil, Luqman Ali, Muhammad Younis Tahir, Fazal Shah Shirazi

Pak J Ophthalmol 2018, Vol. 34, No. 4

.....
See end of article for authors affiliations
.....

Correspondence to:
Ahmad Zeeshan Jamil
Assistant Professor of Ophthalmology,
Sahiwal Medical College, Sahiwal.
Email: ahmadzeeshandr@yahoo.com

Purpose: To find the reliability of fundus photography using smart phone in diabetic patients compared to Slit lamp biomicroscopic examination.

Study design: Comparative cross sectional.

Place and Duration of Study: This study was conducted in district headquarter teaching hospital affiliated with Sahiwal Medical College, Sahiwal from January 2017 to December 2017.

Material and Methods: 250 eyes of 125 diabetic patients visiting outpatient department were examined for diabetic retinopathy by smart phone fundus photography and slit lamp biomicroscopy by 2 independent ophthalmologists. Examination was performed after dilatation of the pupil. Diabetic retinopathy changes were noted and graded by each observer for the same patient on a form. Age and gender were recorded for all patients.

Results: There was high degree of agreement in findings of the smart phone and the slit lamp which was used as a gold standard. The kappa value was found to be 0.87 between the two methods of diagnosing clinically significant macular oedema (CSME). Sensitivity, specificity, positive predictive value, negative predictive value and diagnostic accuracy of smart phone fundus photography in diagnosis of CSME was 82.6%, 99.55%, 95%, 98.26% and 98%.

Conclusion: Smart phone fundus photography shows reasonable agreement with slit lamp microscopy for the diagnosis of diabetic retinopathy and can be used for the screening purposes.

Key words: Diabetic Retinopathy, Macular oedema, Slit Lamp Microscopy, Smart phone, Telemedicine.

.....
According to 2017 census, Pakistan is the 6th most populous country of the world with population of 207,774,520¹. According to WHO, prevalence of diabetes mellitus in Pakistan is 9.8% and Pakistan has seventh largest diabetic patients in the world^{2,3}. The prevalence of diabetic retinopathy in Pakistan is 28.78% among the diabetic population⁴. Management of diabetic retinopathy requires long-

term patient's education and comprehensive eye care to prevent vision impairment.

Imaging has unique and widespread role in the field of ophthalmology. Imaging is widened to diagnosis, treatment, documentation, research and learning purposes. Imaging is extensively used for screening purpose of eye diseases. This is especially true for various retinal conditions⁵. It is very expensive

and technically demanding to get good quality ophthalmic images through dedicated workstations and image capturing units in hospital environment.

Recent development in the hardware and software of smart phones has spread their use widely. Like all other professionals, ophthalmologists are not lagging behind in adopting this revolutionary technology. Smart phones have found their valuable use in the field of ophthalmology. They are readily available, handy, easy to use and have great capability for connectivity wirelessly⁶. Apart from their conventional role of phone calls and text messaging smart phones are now able to do multiple tasks like video recording, running soft-wares and applications, remote connectivity with internet.^{7,8,9}

Coupled with their portability and connectivity with other gadgets, smart phone acceptability in the professional use in the field of ophthalmology is ever increasing¹⁰. Use of smart phone photography is as useful in hospital setting as is in the remote community setting. For the screening and diagnosis of retinal diseases particularly diabetic retinopathy by utilizing smart phone, different modalities are being used. Various attachments have been developed to help smart phone getting images of the retina. Alternatively, a high power condensing lens can be used on the principle of indirect ophthalmoscopy to capture retinal images^{11,12}.

This novel use of smart phone can overcome constrains of socioeconomic and cultural barriers in providing eye care facilities to areas where comprehensive eye care facilities are non-existing¹³. Many eye diseases causing blindness are preventable like morbidity related to diabetic retinopathy, glaucoma and age related macular degeneration¹⁴. Effective screening is the key to prevention¹⁵. Screening protocols should address the community as most of the population never visits hospital before there is permanent damage. Utilization of smart phone fundus photography to screen and diagnose these crippling diseases has a great potential.

High quality fundus images can be captured and transferred to distant specialized centres for expert opinion. This tele-ophthalmic use of smart phone is widely utilized, and there is much more to come in the future¹⁶. The rationale of the study was to find a cheap, easy to use and reliable tool for screening of diabetic retinopathy. The purpose of the present study was to compare the reliability of fundus photography with smart phone in the screening of diabetic

retinopathy with slit lamp microscopy, which is the gold standard.

MATERIAL AND METHODS

This prospective study was conducted in ophthalmology department of District Head Quarter Teaching Hospital affiliated with Sahiwal Medical College Sahiwal from January 2017 to December 2017. The study was approved by the ethical committee of the institution. Consent was obtained from all patients who were included in the study. Diabetic patients coming in outpatient department were included in the study. This was cross sectional study and sampling technique was purposive sampling.

All diabetic patients older than 15 years of both genders were included. Patients with media opacity were excluded from the study. Pupillary dilatation was achieved by instilling 1% tropicamide and 10% phenylephrine eye drops that were repeated twice after five minutes interval. After full dilatation of the pupil fundus photographs were taken with the help of smart phone and 20 diopter condensing lens. Images of posterior pole, superior, nasal, inferior and temporal periphery were captured. Smart phone used for this purpose was Samsung galaxy N9000. Images were taken using a resolution of 1920×1080. Afterwards patients went through comprehensive eye examination on slit lamp. Fundus photographs taken by smart phone were sent by whatsapp to one specialist (ML). Slit lamp examination was performed by another specialist (AZ). Findings were recorded according to a specially designed proforma. Both specialists were unaware of each other's findings. Findings were categorized on the presence or absence of microaneurysms, exudates, retinal thickening, haemorrhages, intra-retinal micro-vascular changes, neovascularization of retina and optic disc. Each specialist individually placed patients into following categories based on his findings: no diabetic retinopathy, non-proliferative diabetic retinopathy, proliferative diabetic retinopathy and clinically significant macular oedema.

Age was presented as mean and standard deviation while gender was presented as percentage. K statistics was used to assess agreement between smart phone and slit lamp findings. Sensitivity, specificity, positive predictive value, negative predictive value and diagnostic accuracy were calculated using slit lamp examination as gold standard. Statistical analysis

was performed using statistical programme for social sciences (SPSS version 21).

RESULTS

There were 250 eyes of 125 diabetic patients in the present study. Mean age was 52.11 ± 11.33 years. There were 136 (54.4%) males and 114 (45.6%) females.

Table 1 shows frequency of findings along with agreement value between the two groups. Table 2 gives the sensitivity, specificity, positive predictive value, negative predictive value and diagnostic accuracy by using smart phone fundus photography for diagnosis of diabetic retinopathy with slit lamp examination as gold standard.

Table 1: Frequency of findings along with agreement value between slit lamp and smart phone.

| | Diabetic Retinopathy | | Non-proliferative Diabetic Retinopathy | | Proliferative Diabetic Retinopathy | | Clinically Significant Macular Oedema | |
|--------------|----------------------|----------------|--|----------------|------------------------------------|----------------|---------------------------------------|----------------|
| | Yes | No | Yes | No | Yes | No | Yes | No |
| Slit lamp | 67 (26.2%) | 183 (73.2%) | 55 (22%) | 195 (78%) | 22 (8.8%) | 228 (91.2%) | 23 (9.2%) | 227 (90.8%) |
| Smart phone | 61 (24.4%) | 189 (75.6%) | 53 (21.2%) | 197 (78.8%) | 19 (7.6%) | 231 (92.4%) | 20 (8%) | 230 (92%) |
| κ(agreement) | 0.916 | | 0.787 | | 0.814 | | 0.873 | |

Table 2: Sensitivity, specificity, positive predictive value, negative predictive value and diagnostic accuracy by using smart phone fundus photography for diagnosis of diabetic retinopathy with slit lamp examination as gold standard.

| | Diabetic Retinopathy | Non-proliferative diabetic retinopathy | Proliferative diabetic retinopathy | Clinically significant macular oedema |
|---------------------------|----------------------|--|------------------------------------|---------------------------------------|
| Sensitivity | 89.5% | 81.81% | 77.27% | 82.60% |
| Specificity | 99.45% | 95.89% | 99.12% | 99.55% |
| Positive predictive value | 98.36% | 84.90% | 89.47% | 95.0% |
| Negative predictive value | 96.29% | 94.92% | 97.83% | 98.26% |
| Diagnostic accuracy | 96.8% | 92.8% | 97.2% | 98% |

DISCUSSION

Diabetic retinopathy is a potentially blinding condition. Timely diagnosis and appropriate treatment is of paramount importance to lessen the morbidity of this disease. Traditional fundus imaging cameras are costly, and they require dedicated environment for their operation¹⁷. There is a need for some alternative that is cheap, readily available, practical in community settings and has connectivity through telemedicine to specialist centres if we want to extend our health care services to underserved areas of the community¹⁸.

In the present study, 250 eyes of 125 diabetic patients were screened with the help of smart phone fundus photography. Slit lamp examination was used as gold standard to diagnose diabetic retinopathy. Sensitivity, specificity, positive predictive value, negative predictive value and diagnostic accuracy of

smart phone fundus photography in diagnosis of clinically significant macular oedema was 82.6%, 99.55%, 95%, 98.26% and 98%. Our findings are comparable to the results presented by Russo A and co-authors. They reported 81% sensitivity and 98% specificity of diagnosing clinically significant macular oedema with the help of smart phone. In their study, agreement between examined techniques was 0.79 as compared to 0.87 in our study. However, Russo and co-authors used D-Eye system as smart phone camera attachment as compared to 20 diopter condensing lens used in our study. Our approach utilized the principle of indirect ophthalmoscopy to capture retinal images. Flashlight of smart phone provided the light source to illuminate the retina.

Work of Maamari et al¹⁷ showed the quality of retinal images captured with the help of smart phone

using 20 diopter condensing lens were of high quality to detect retinal changes.

Smart phone fundus imaging yields high quality photographs that are comparable to that obtained through fundus camera¹⁹. Like any other skill quality of images captured with smart phone improves with practice and experience of the examiner. Light exposure by smart phone camera is very less as compared to indirect ophthalmoscope light, making it a safe technique in terms of retinal light toxicity²⁰. This decreased light intensity is more comforting for the patient but at the same time, it makes it difficult to get fundus images in the presence of media opacity.

Advantages of capturing retinal images with smart phone are many. Smart phone is an economical device that is readily available in almost every setting of our community. Moreover, its acceptability among doctors and public is very high. It needs no extra expensive attachments. It is true when high power condensing lens is used to take photographs. Nurses, community health workers and paramedics can be trained to capture images and send these images through whatsapp or email to retinal specialist located in specialist centres for expert opinion.

There are limitations of our study. The field of view by smart phone fundus imaging is less as compared to that obtained by slit lamp fundus examination that is gold standard. Stereopsis is lacking in fundus images by smart phone. Moreover, examiner practice is required before getting high quality images by smart phone. Patient's cooperation is very important in getting good images.

Nonetheless smart phone fundus photography is a promising technique that makes it possible to get high quality retinal images to detect retinal changes in population of remote and less served areas. Use of tele-ophthalmology in combination with smart phone fundus imaging can open a new prospect for screening and diagnosis of potentially blinding diabetic retinopathy.

Author's Affiliation

Dr. Ahmad Zeeshan Jamil
MBBS, MCPS, FCPS, FRCS, FCPS (VRO)
Associate Professor of Ophthalmology, Sahiwal
Medical College, Sahiwal.

Dr. Luqman Ali
MBBS, FCPS, Fellowship Refractive and Cornea
Surgery

Assistant Professor of Ophthalmology, Shahida Islam
Medical College, Lodhran.

Dr. Muhammad Younis Tahir
MBBS, FCPS, Fellowship in Vitreoretina
Assistant Professor of Ophthalmology, Quaid e Azam
Medical College, Bahawalpur.

Dr. Fazal Shah Shirazi
MBBS, DOMS, MCPS
Consultant Ophthalmologist, District Head Quarter
Teaching Hospital Sahiwal

Role of Authors

Dr. Ahmad Zeeshan Jamil
Concept and design of study, Interpretation of data

Dr. Luqman Ali
Drafting and critical version of intellectual content

Dr. Muhammad Younis Tahir
Statistical analysis, manuscript writing, proof reading

Dr. Fazal Shah Shirazi
Literature search and drafting of article

REFERENCES

1. Pakistan bureau of statistics. Province Wise Provisional Results of Census – 2017. Available at: http://www.pbs.gov.pk/sites/default/files/PAKISTAN%20TEHSIL%20WISE%20FOR%20WEB%20CENSUS_2017.pdf [Accessed on 25/05/2018].
2. Pakistan-World Health Organization-Diabetes country profiles, 2016. Available at: http://www.who.int/diabetes/country-profiles/pak_en.pdf?ua=1 [Accessed on 26/05/2018]
3. **Shera AS, Jawad F, Maqsood A.** Prevalence of diabetes in Pakistan. *Diabetes Res Clinical Prac* 2007; 76 (2): 219-22.
4. **Mumtaz SN, Fahim MF, Arslan M, Shaikh SA, Kazi U, Memon MS.** Prevalence of diabetic retinopathy in Pakistan: A systematic review. *Pak J Med Sci.* 2018; 34 (2): 493-500.
5. **Nazari KH, Nakatsuka A, El-Annan J.** Smart phone Fundus Photography. *Journal of Visualized Experiments:* 2017; (125) :55958.
6. **Lord RK, Shah VA, San Filippo AN, Krishna R.** Novel Uses of Smart phones in Ophthalmology. *Ophthalmology*, 2010; 117 (6): 1274-.e3.
7. **Zvornicanin E, Zvornicanin J, Hadziefendic B.** The Use of Smart phones in Ophthalmology. *Acta Informatica Medica.* 2014; 22 (3): 206-9.
8. **Tahiri HR, El Sanharawi M, Dupont-Monod S, Baudouin C.** Smart phones in ophthalmology. *Journal francais d'ophtalmologie.* 2013; 36 (6): 499-525.
9. **Bastawrous A, Cheeseman RC, Kumar A.** iPhones for eye surgeons. *Eye*, 2012; 26 (3): 343-54.

10. **Russo A, Morescalchi F, Costagliola C, Delcassi L, Semeraro F.** Comparison of smart phone ophthalmoscopy with slit-lamp biomicroscopy for grading diabetic retinopathy. *Am J Ophthalmol* 2015; 159 (2): 360-4.e1.
11. **Haddock LJ, Kim DY, Mukai S.** Simple, inexpensive technique for high-quality smart phone fundus photography in human and animal eyes. *J Ophthalmol.* 2013; 2013: 518479.
12. **Myung D, Jais A, He L, Blumenkranz MS, Chang RT.** 3D printed smart phone indirect lens adapter for rapid, high quality retinal imaging. *J Mob Technol Med.* 2014; 3 (1): 9-15.
13. **Chow SP, Aiello LM, Cavallerano JD, Katalinic P, Hock K, Tolson A, et al.** Comparison of non-mydratic digital retinal imaging versus dilated ophthalmic examination for non-diabetic eye disease in persons with diabetes. *Ophthalmology*, 2006; 113 (5): 833-40.
14. **Mohamed Q, Gillies MC, Wong TY.** Management of diabetic retinopathy: a systematic review. *JAMA* 2007; 298 (8): 902-916.
15. **Cheung N, Mitchell P, Wong TY.** Diabetic retinopathy. *Lancet.* 2010; 376 (9735): 124-136.
16. **Chhablani J, Kaja S, Shah V.** Smart phones in ophthalmology. *Indian J Ophthalmol*, 2012; 60 (2): 127-31.
17. **Maamari RN, Keenan JD, Fletcher DA, Margolis TP.** A mobile phone-based retinal camera for portable wide field imaging. *Br J Ophthalmol*, 2014; 98 (4): 438-41.
18. **Shanmugam M, Mishra D, Madhukumar R, Ramanjulu R, Reddy S, Rodrigues G.** Fundus imaging with a mobile phone: A review of techniques. *Indian J Ophthalmol*, 2014; 62 (9): 960-2.
19. **Adam MK, Brady CJ, Flowers AM, Juhn AT, Hsu J, Garg SJ, et al.** Quality and Diagnostic Utility of Mydratic Smart phone Photography: The Smart phone Ophthalmoscopy Reliability Trial. *Ophthalmic surgery, lasers & Imaging retina*, 2015; 46 (6): 631-7.
20. **Kim DY, Delori F, Mukai S.** Smart phone photography safety. *Ophthalmology*, 2012; 119 (10): 2200-1; author reply 1.

Annexure

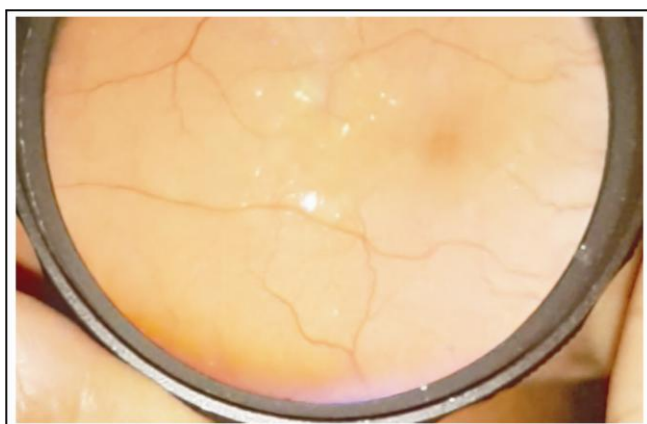

Fig. 1: Retinal thickening, hard exudates and clinically significant macular oedema

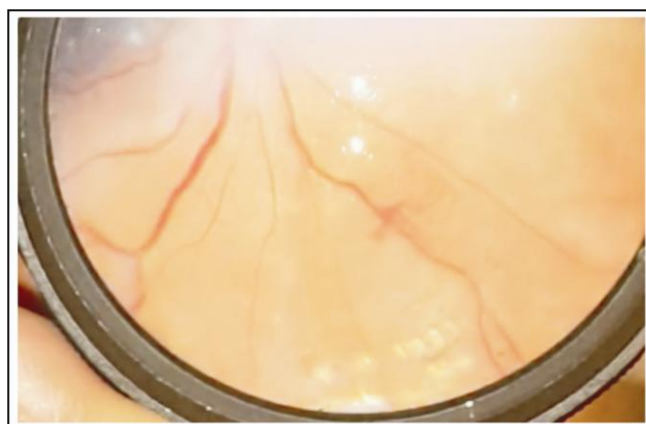


Fig. 2: Neo vascularization elsewhere and laser marks.




Fig. 3: Fibrous tractional fold at disc and macula along with neo vascularization at disc.

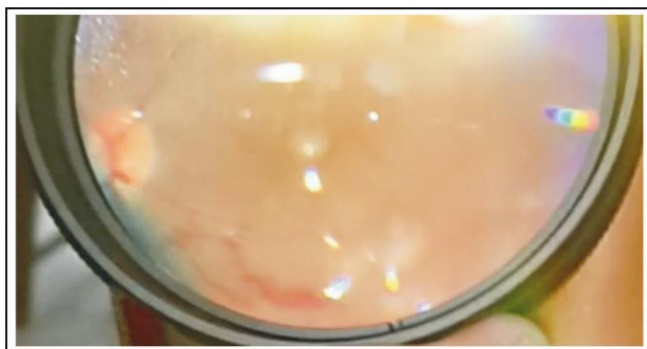

Fig. 4: In a silicone oil filled eye there is neo vascularization at disc and neo vascularization elsewhere.

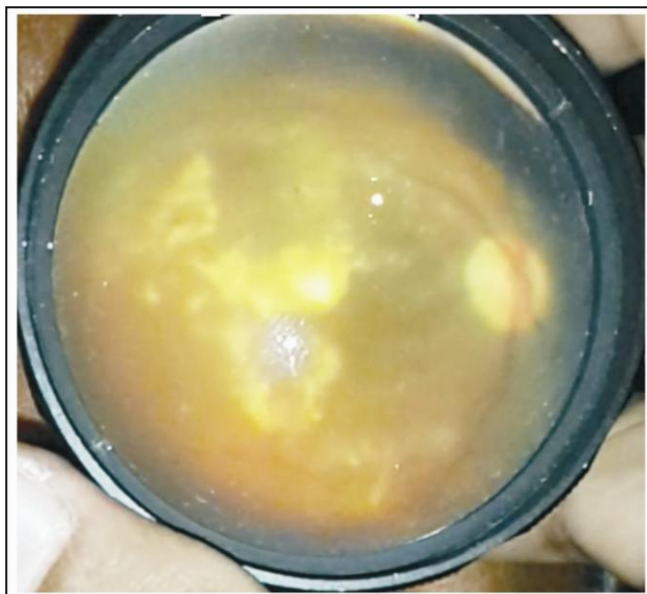

Fig. 5: Massive plaque exudative maculopathy.

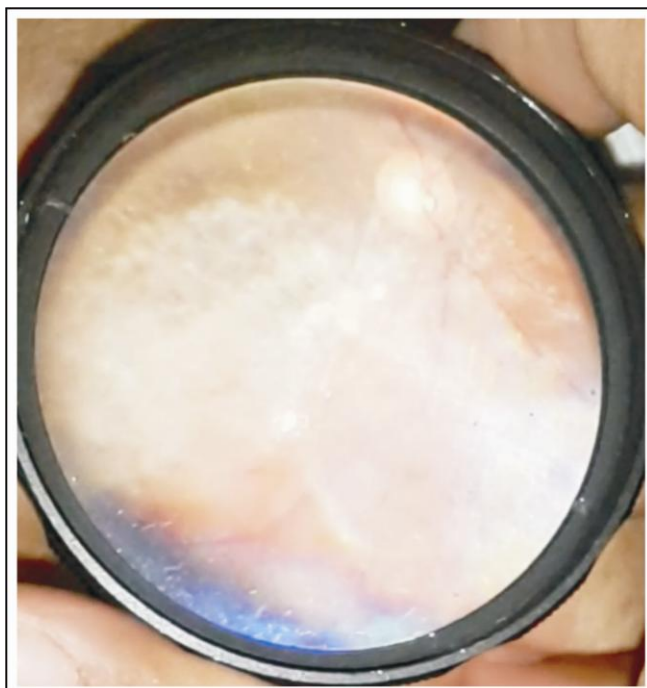

Fig. 6: Asteroids hyalosis.