

# Limbal Epithelial Stem Cell Transplantation for Ocular Chemical Burns: A Systematic Review



Andintia Aisyah Santoso<sup>1</sup>, Muhammad Rheza Hilfaziyan Lubis<sup>2</sup>,  
Mohammad Amin Rais Perfernandi Ilham<sup>3</sup>  
<sup>1-3</sup>Faculty of Medicine, Universitas Indonesia, Depok, Indonesia

## ABSTRACT

Ocular burns can cause limbal stem cell deficiency (LSCD), which may require limbal stem cell transplantation (LSCT) to restore corneal function. This review evaluates outcomes of different LSCT techniques for treating ocular chemical injuries. A comprehensive search of Cochrane Library, PubMed, Scopus, EBSCO, and ProQuest, was conducted for studies published between 2014 and 2024, supplemented by manual searches. Studies focusing on LSCT for chemical injuries were included. The primary outcome was achievement of a stable, completely epithelialized, avascular corneal surface. Twelve studies, encompassing 473 eyes, met the inclusion criteria. Alkali injury was reported as the most common aetiology. The cumulative surgical success rates were 74.8% for autografts, 47.6% for allografts, and 54.4% for cultivated limbal epithelial transplantation. LSCT is a safe and effective intervention for ocular burns, particularly in severe LSCD cases, offering both anatomical restoration and functional visual improvement.

**Keywords:** Limbal Stem Cell Deficiency, Limbal Stem Cell Transplantation, Ocular Chemical Burns.

**How to Cite this Article:** Santoso AA, Lubis MRH, Ilham MARP. Limbal Epithelial Stem Cell Transplantation for Ocular Chemical Burns: A Systematic Review. 2025;41(3):348-354. **Doi:**10.36351/pjo.v41i3.2029

---

*Correspondence: Andintia Aisyah Santoso  
Faculty of Medicine, Universitas Indonesia, Depok,  
Indonesia  
Email: andintiasantoso@rocketmail.com*

---

*Received: February 9, 2025  
Revised: April 4, 2025  
Accepted: April 17, 2025*

## INTRODUCTION

Ocular chemical burns are a critical ophthalmic emergency that can lead to severe anterior segment damage and permanent visual impairment.<sup>1</sup> Studies reported that chemical injuries account for 7.7 to 22.1% of all ocular trauma.<sup>1,2</sup> Among the chemical aetiologies, alkaline burns are more common due to widespread domestic and industrial use. One of the most visually significant long-term sequelae of severe chemical injury is limbal stem cell deficiency (LSCD), a condition characterized by dysfunction of the corneal epithelial progenitor cells. This condition compromises corneal clarity, impairs wound healing, and results in progressive visual deterioration.<sup>1</sup>

Prompt identification and management of chemical burns are crucial for optimizing patient outcomes. The most widely used classification systems for ocular chemical burns are the Roper-Hall and Dua Classifications. In cases of severe LSCD, limbal stem cell transplantation (LSCT) is an essential intervention that restores the damaged corneal surface by replenishing lost or damaged limbal cells. LSCT can be categorized into three main types based on the source of stem cells: autologous (from the patient's unaffected eye), allogeneic (from a donor's eye), and cultivated transplantation (involves ex vivo expansion of cells).<sup>3,4</sup>

The management of severe ocular burns is overly complex and individualized, as these injuries often involve extensive structural damage and require long-term follow-up. Despite advancements in LSCT, no standardized guidelines currently exist for managing severe LSCD or comparing the effectiveness of different LSCT techniques. This study aims to evaluate the clinical outcomes of various LSCT approaches in treating ocular chemical burns.

## METHODS

A systematic review was conducted following the Preferred Reporting Items for Systematic Review and Meta-analysis (PRISMA) guidelines. A comprehensive literature search was performed across several databases, including Cochrane Library, PubMed, Scopus, EBSCO, and ProQuest, covering studies published between January 1<sup>st</sup> 2014 and December 31<sup>st</sup> 2024. The search strategy incorporated specific keywords: “limbal stem cell” / “limbal epithelial”, “transplantation” / “therapy”, “ocular” / “eye”, and “chemical injury” / “chemical burn”. After the electronic database search, a manual search of the references from selected studies was conducted to identify additional relevant publications.

### Study Selection and Data Extraction

Following criteria was followed for inclusion of studies: studies published in English or Bahasa, available in full text, and conducted within the past 10 years. Studies that did not investigate LSCT or did not assess chemical injury as a primary parameter were excluded. The initial screening of titles and abstracts was conducted by one author (AA), followed by an independent appraisal of eligible full text studies by two authors (MR and MA) for final inclusion. Data extraction focused on key study characteristics and clinical outcomes. Extracted variables included the author and year of publication, sample size, age group of subjects, affected eye, main aetiology of injury, type of LSCT performed, interval to surgery, minimum follow-up duration, and primary clinical outcomes.

### Definition of Outcomes and LSCT Classification

The primary outcome was defined as surgical success, measured by the achievement of a completely epithelialized, stable, and avascular corneal surface. The duration or survival rate of complete epithelialization was also considered a primary outcome. Adverse events and complications were also analysed. LSCT was categorized into specific subtypes: autologous transplants, including CLAU (Conjunctival Limbal Autograft), SLET (Simple Limbal Epithelial Transplantation), and cultivated types; and allogeneic transplants, including Ir-CLAL (Living-Related Conjunctival Limbal Allograft), cadaveric KLAL (Keratolimbal Allograft), and cultivated types.<sup>4</sup> Cultivated LSCT was grouped

separately due to the specialized techniques and advanced equipment required.

### Risk of Bias Assessment

Three authors (AA, MR, MA) independently assessed quality and risk of bias of the included full-text articles using the Joanna Briggs Institute (JBI) Critical Appraisal Tool for Cohort Studies or Case Series.<sup>5</sup> Specific items within the appraisal tool addressed risk of bias, while others evaluated the adequacy of reporting and statistical analysis. A response of ‘no’ to any appraisal question indicated potential limitations, thereby negatively impacting the overall quality of the study.

## RESULTS

The initial electronic search identified 423 articles, with an additional 12 records found through manual searches. After removing 179 duplicates, the titles, and abstracts of the remaining 244 studies were screened. Of these, 223 studies were excluded due to inappropriate parameters, outcomes, or being published more than 10 years ago. The full texts of 21 potentially relevant articles were then evaluated, and 12 articles met all inclusion criteria and were included in this review (Figure 1).

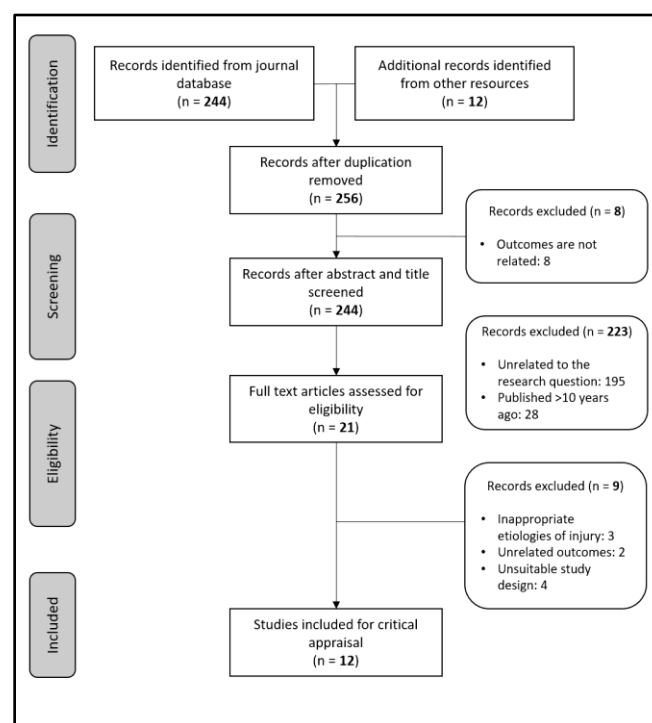


Figure 1: Study selection flowchart.

**Table 1:** *Quality assessment of selected case series studies.*

No	Author, year	Q1	Q2	Q3	Q4	Q5	Q6	Q7	Q8	Q9	Q10
1	Jain et al <sup>6</sup> , 2014	✓	⊗	⊗	✓	✓	✓	✓	✓	N/A	✓
2	Mittal et al <sup>7</sup> , 2016	✓	✓	✓	⊗	Unclear	✓	✓	✓	⊗	✓
3	Basu et al <sup>8</sup> , 2016	✓	✓	✓	✓	✓	✓	✓	✓	⊗	✓
4	Iyer et al <sup>9</sup> , 2017	⊗	Unclear	Unclear	✓	✓	✓	✓	✓	⊗	Unclear
5	Cheng et al <sup>10</sup> , 2017	✓	✓	✓	⊗	Unclear	✓	✓	✓	⊗	✓
6	Gupta et al <sup>11</sup> , 2017	✓	✓	✓	✓	✓	✓	✓	✓	⊗	✓
7	Basu et al <sup>12</sup> , 2018	✓	✓	Unclear	✓	⊗	✓	✓	✓	⊗	✓
8	El-Hofi et al <sup>13</sup> , 2019	✓	✓	Unclear	⊗	⊗	✓	✓	✓	⊗	✓
9	Agarwal et al <sup>14</sup> , 2020	✓	✓	✓	✓	✓	⊗	✓	✓	⊗	✓
10	Ozer et al <sup>15</sup> , 2020	✓	✓	✓	⊗	Unclear	✓	✓	✓	⊗	✓

**Appraisal questions:**

- Q1: Were there clear criteria for inclusion in the case series?
- Q2: Was the condition measured in a standard, reliable way for all participants included in the case series?
- Q3: Were valid methods used for identification of the condition for all participants included in the case series?
- Q4: Did the case series have consecutive inclusion of participants?
- Q5: Did the case series have complete inclusion of participants?
- Q6: Was there clear reporting of the demographics of the participants in the study?
- Q7: Was there clear reporting of clinical information of the participants?
- Q8: Were the outcomes or follow up results of cases clearly reported?
- Q9: Was there clear reporting of the presenting site(s)/clinic(s) demographic information?
- Q10: Was statistical analysis appropriate?

**Table 2:** *Quality assessment of selected cohort studies.*

No	Author, year	Q1	Q2	Q3	Q4	Q5	Q6	Q7	Q8	Q9	Q10	Q11
1	Arora et al <sup>16</sup> , 2017	Unclear	✓	✓	Unclear	✓	✓	✓	⊗	Unclear	⊗	✓
2	Korkmaz et al <sup>17</sup> , 2023	⊗	⊗	✓	✓	✓	✓	✓	✓	✓	⊗	✓

**Appraisal questions:**

- Q1: Were the two groups similar and recruited from the same population?
- Q2: Were the exposures measured similarly to assign people to both exposed and unexposed groups?
- Q3: Was the exposure measured in a valid and reliable way?
- Q4: Were confounding factors identified?
- Q5: Were strategies to deal with confounding factors stated?
- Q6: Were the groups/participants free of the outcome at the start of the study (or at the moment of exposure)?
- Q7: Were the outcomes measured in a valid and reliable way?
- Q8: Was the follow up time reported and sufficient to be long enough for outcomes to occur?
- Q9: Was follow up complete, and if not, were the reasons to loss to follow up described and explored?
- Q10: Were strategies to address incomplete follow up utilized?
- Q11: Was appropriate statistical analysis used?

Tables 1 and 2 present the risk of bias and quality assessment of the 12 included studies using the JBI

Critical Appraisal Tool. Of these studies, 10 were case series and 2 were cohort studies. The case series

**Table 3:** Summary of studies.

No	Author, year	Subject number	Age group	Eye affected	Main etiology	LSCT type	Interval to surgery	Minimum follow-up time (months)	Main outcome
1	Jain et al <sup>6</sup> , 2014	9	Children and adults	Unilateral	Alkali (100%)	Autologous (SLET)	Chronic	3	Success rate: 66.7%
2	Mittal et al <sup>7</sup> , 2016	4	Children	Unilateral	Alkali (50%)	Autologous (SLET)	Chronic	6	Success rate: 100%
3	Basu et al <sup>8</sup> , 2016	125	Children and adults	Unilateral	Alkali (69.6%)	Autologous (SLET)	Chronic	12	Success rate: 76.0%
4	Arora et al <sup>16</sup> , 2017	20	Children and adults	Unilateral	Alkali (100%)	Autologous (SLET, CLAU)	Chronic	6	Success rate: 100%
5	Gupta et al <sup>11</sup> , 2017	30	Children and adults	Unilateral	Alkali (56.7%)	Autologous (SLET)	Chronic	5	Success rate: 70.0%
6	Basu et al <sup>12</sup> , 2018	30	Children and adults	Unilateral	Alkali (76.7%)	Autologous (SLET)	Chronic	12	Success rate: 80.0%
7	Iyer et al <sup>9</sup> , 2017	18	Children and adults	Mixed	Alkali (70.6%)	Allogeneic (SLET)	Acute	3	Mean time to epithelization: 22.5±9.14 days
8	El-Hofi et al <sup>13</sup> , 2019	20	Adults	Bilateral	Alkali (70.0%)	Allogeneic (Lr-CLAL)	Chronic	18	Success rate: 75.0%
9	Agarwal et al <sup>14</sup> , 2020	39	Children and adults	Mixed	Alkali (69.2%)	Allogeneic (SLET)	Acute	20 (median)	Mean time to epithelization: 41.2±26.12 days
10	Ozer et al <sup>15</sup> , 2020	18	Children and adults	Bilateral	Alkali (85.7%)	Allogeneic (Lr-CLAL, KLAL)	Chronic	12	Survival rates (1 yr): 65±11% (Lr-CLAL), 67±16% (KLAL)

**Table 4:** Common complications of LSCT.

Author, Year	Complications
<b>Autologous Type</b>	
Jain et al <sup>6</sup> , 2014	Symblepharon (33%)
Mittal et al <sup>7</sup> , 2016	Symblepharon (100%)
Basu et al <sup>8</sup> , 2016	Progressive conjunctivalization (18.4%), symblepharon (16.8%)
Arora et al <sup>16</sup> , 2017	Corneal thinning and micro-perforation (5%), haemorrhage under amniotic membrane (5%)
Gupta et al <sup>11</sup> , 2017	Symblepharon (56.7%), progressive conjunctivalization (30%)
Basu et al <sup>8</sup> , 2018	LSCD recurrence (20%), haemorrhage under amniotic membrane (6.7%)
<b>Allogeneic Type</b>	
Iyer et al <sup>9</sup> , 2017	Symblepharon (16.7%)
El-Hofi et al <sup>13</sup> , 2019	Severe inflammation (25%), acute graft rejection (15%)
Ozer et al <sup>15</sup> , 2020	Glaucoma (62%), recurrent conjunctivalization (22.2%), infectious keratitis (17%)
<b>Cultivated Type</b>	
Cheng et al <sup>10</sup> , 2017	Symblepharon (50%), cicatricial entropion/trichiasis (41.3%)

demonstrated generally good quality; however, none reported demographic information about the presenting site or clinic. Similarly, while the cohort studies were of adequate quality, they did not address strategies for managing incomplete follow-up.

A summary of the 12 relevant studies, encompassing a total of 473 eyes, is presented in Table 3. Among the LSCT techniques analysed, 6 focused on autologous transplants, 4 on allogeneic transplants, 1 on cultivated transplants, and 1 compared all three types. Alkali burns were identified as the main aetiology, posing significant management challenges due to their aggressive impact on ocular tissues. Most surgeries were performed during the chronic phase or the transition from the acute to chronic phases.

The overall surgical success rate across all LSCT types was approximately 75.9%. Autologous transplants had a success rate of 75.4%, allogeneic procedures achieved a 62.5% success rate, and cultivated transplants demonstrated the highest success rate at 82.2%. Symblepharon was the most frequently reported complication (Table 4), though it was reversible and manageable through additional surgical interventions.

## DISCUSSION

LSCD is a severe ocular condition often resulting from chemical burns, with alkali substances being the most common causative agents. Alkali injuries induce saponification of fatty acids in cellular membranes, facilitating rapid penetration into the cornea and dissolution of stromal collagen. This process triggers prolonged inflammation and increases the severity of LSCD. In our findings, alkali injuries accounted for 61.9% of cases, establishing them as the major indication for LSCT. The hallmark features of LSCD include corneal conjunctivalization, inflammation, neovascularization, and fibrosis.<sup>4,18</sup>

The mechanisms underlying LSCT continue to be studied. This procedure involves both the regeneration of dormant stem cells post-injury and the reimplantation of transplanted stem cells into the limbal niche. The limbus houses peripheral progenitor cells that actively proliferate and migrate toward the central cornea to restore the corneal epithelium. Upon corneal injury, these progenitor cells are triggered to differentiate into epithelial cells, a process regulated by the basement membrane and influenced by growth factors and cytokines.<sup>19</sup> While previous studies often considered improvement in visual acuity as the primary success criterion for LSCT, the main objective is the mitigation of LSCD severity and complete epithelialization of the corneal surface (anatomical restoration) rather than direct improvement of visual acuity.

The choice of surgical technique is a critical factor influencing the success of ocular injury treatments. A meta-analysis by Le et al,<sup>3</sup> reported ocular surface improvement rates of 85.7% for autologous transplants, 57.8% for allogeneic transplants, and 84.7% for cultivated transplants. In comparison, our review found cultivated LSCT to have the highest success rate (82.2%), followed by autologous (75.4%) and allogeneic (62.5%) transplants. Despite its high success rate, cultivated transplantation requires specialized laboratory equipment for ex vivo cell expansion, making it less accessible.<sup>10,17</sup> Autologous transplantation, particularly SLET, remains the most used method due to its feasibility and comparable effectiveness. SLET has emerged as an alternative to cultivated and conventional autologous transplantation. This technique involves harvesting minimal donor tissue from the healthy fellow eye, eliminating the need for specialized laboratory facilities.<sup>8</sup> A study by Arora et al,<sup>16</sup> reported that both

autologous transplants, CLAU and SLET, were equally effective in achieving a stable ocular surface and significantly improving corneal clarity. Some studies suggest that SLET may be more effective than cultivated LSCT (CLET) due to the use of fresh tissue without laboratory manipulation. However, limbal autografts have notable disadvantages, including the lack of repeatability and the risk of inducing LSCD in the contralateral eye.<sup>12,17</sup> Allogeneic transplantation offers the advantage of providing a larger number of stem cells but carries risks of rejection and necessitates long-term immunosuppression. Some studies favor allogeneic transplantation to avoid potential damage to the healthy eye and to secure a greater supply of corneal limbal cells.<sup>13,15</sup>

Inflammation plays a crucial role in the success of LSCT. In the subacute phase of chemical injury, low-level inflammation may persist, potentially affecting outcomes. Most studies perform LSCT during the chronic phase, as this timing has shown better graft survival rates. LSCT is not recommended during the acute stage.<sup>17</sup> However, studies by Agarwal et al,<sup>14</sup> and Iyer et al,<sup>9</sup> demonstrated that performing allogeneic transplants in the acute or early stages can facilitate rapid epithelialization and prevent corneal scarring or perforation due to delayed treatment. These studies reported significant visual improvements and reduced the need for subsequent surgeries in the chronic phase. Conversely, Sejjal et al,<sup>20</sup> reported high surgical failure rates in patients who underwent CLET within four months of a chemical injury.

Age does not appear to be a significant factor in LSCT outcomes. However, some studies suggest that children may have better success rates due to the greater regenerative potential of younger donor tissue.<sup>8</sup> This advantage is counterbalanced by a stronger inflammatory response to both the initial injury and the transplanted graft, necessitating careful management. Further analysis is required to determine whether the greater severity of injuries in children influences these outcomes. In paediatric populations, delays in achieving acute treatment goals and initiating visual rehabilitation increase the risk of amblyopia.<sup>9</sup>

Postoperative symblepharon significantly affects limbal transplantation outcomes. Symblepharon extending to the cornea indicates conjunctival deficiency, and addressing this condition before or during transplantation may improve surgical success.<sup>6,7,17</sup> Corneal perforation following surgery is another complication that may require additional

penetrating keratoplasty, impacting transplantation outcomes. Preoperative identification of thin corneas using optical coherence tomography (OCT) or ultrasound is advisable to mitigate this risk.<sup>8</sup> Additionally, eyelid deformities and post-injury infections are common complications that contribute to treatment failure and should be managed proactively.<sup>10,15</sup>

This review has several limitations. Success criteria and outcome definitions vary across studies, potentially leading to inconsistent conclusions. LSCD following ocular burns is a rare condition, limiting the availability of subjects for enrolment in large-scale studies. Additionally, the number of studies and subjects for each LSCT type is not equally represented. The retrospective nature of most studies also limits the strength of the conclusions drawn. We recommend a minimum follow-up period of one year, as the highest failure rates occur within the first-year post-transplantation. Future research should include larger studies with direct comparisons of LSCT techniques and comprehensive cost analyses to better understand the efficacy and feasibility of different approaches.

## CONCLUSION

LSCT is recognized as a safe and effective treatment for ocular burns with severe LSCD to restore both anatomical structure and functional vision. The choice of surgical technique should be individualized, considering factors such as the type of injury, available resources, and patient-specific conditions. Optimal timing of the procedure and effective management of complications, such as symblepharon and post-injury inflammation, are critical for improving transplantation outcomes and long-term prognosis.

**Funding:** This study was not funded by any organization.

**Patient's Consent:** Researchers followed the guidelines set forth in the Declaration of Helsinki.

**Conflict of Interest:** Authors declared no conflict of interest.

## REFERENCES

1. **Akgun Z, Selver OB.** Epidemiology, and aetiology of chemical ocular injury: A brief review. *World J Clin Cases.* 2023;**11(6)**:1245-1251. Doi: 10.12998/wjcc.v11.i6.1245.

2. **Sharma N, Kaur M, Agarwal T, Sangwan VS, Vajpayee RB.** Treatment of acute ocular chemical burns. *Surv Ophthalmol.* 2018;**63(2)**:214-235. Doi: 10.1016/j.survophthal.2017.09.005.
3. **Le Q, Chauhan T, Yung M, Tseng CH, Deng SX.** Outcomes of Limbal Stem Cell Transplant: A Meta-analysis. *JAMA Ophthalmol.* 2020;**138(6)**:660-670. Doi: 10.1001/jamaophthalmol.2020.1120.
4. **Hu JCW, Trief D.** A narrative review of limbal stem cell deficiency & severe ocular surface disease. *Ann Eye Sci* 2023;**8**:13. Doi: 10.21037/aes-22-35.
5. **Joanna Briggs Institute (JBI).** Critical Appraisal Tools [Internet]. Australia: JBI; 2017 [cited 2025 Feb 09]. Available from: <https://jbi.global/critical-appraisal-tools>.
6. **Jain R, Kanaujia V, Sahu S, Das S.** Management of unilateral limbal stem cell deficiency by simple limbal epithelial transplantation—our experience. *MOJ Surg.* 2014;**1(1)**:4-7. Doi: 10.15406/mojs.2014.01.00002.
7. **Mittal V, Jain R, Mittal R, Vashist U, Narang P.** Successful management of severe unilateral chemical burns in children using simple limbal epithelial transplantation (SLET). *Br J Ophthalmol.* 2016;**100(8)**:1102-1108. Doi: 10.1136/bjophthalmol-2015-307179.
8. **Basu S, Sureka SP, Shanbhag SS, Kethiri AR, Singh V, Sangwan VS.** Simple Limbal Epithelial Transplantation: Long-Term Clinical Outcomes in 125 Cases of Unilateral Chronic Ocular Surface Burns. *Ophthalmology.* 2016;**123(5)**:1000-1010. Doi: 10.1016/j.optha.2015.12.042.
9. **Iyer G, Srinivasan B, Agarwal S, Tarigopula A.** Outcome of allo simple limbal epithelial transplantation (alloSLET) in the early stage of ocular chemical injury. *Br J Ophthalmol.* 2017;**101(6)**:828-833. Doi: 10.1136/bjophthalmol-2016-309045.
10. **Cheng J, Zhai H, Wang J, Duan H, Zhou Q.** Long-term outcome of allogeneic cultivated limbal epithelial transplantation for symblepharon caused by severe ocular burns. *BMC Ophthalmol.* 2017;**17(1)**:8. Doi: 10.1186/s12886-017-0403-9.
11. **Gupta N, Joshi J, Farooqui JH, Mathur U.** Results of simple limbal epithelial transplantation in unilateral ocular surface burn. *Indian J Ophthalmol.* 2018;**66(1)**:45-52. Doi: 10.4103/ijo.IJO\_602\_17.
12. **Basu S, Mohan S, Bhalekar S, Singh V, Sangwan V.** Simple limbal epithelial transplantation (SLET) in failed cultivated limbal epithelial transplantation (CLET) for unilateral chronic ocular burns. *Br J Ophthalmol.* 2018;**102(12)**:1640-1645. Doi: 10.1136/bjophthalmol-2017-311506.
13. **El-Hofi AH, Helaly HA.** Evaluation of limbal transplantation in eyes with bilateral severe ocular surface damage secondary to chemical injury. *Clin Ophthalmol.* 2019;**13**:383-390. Doi: 10.2147/OPHTH.S192316.
14. **Agarwal S, Srinivasan B, Gupta R, Iyer G.** Allogeneic Simple Limbal Epithelial Transplantation Versus Amniotic Membrane Grafting in the Early Management of Severe-Grade Ocular Chemical Injuries-A Retrospective Comparative Study. *Am J Ophthalmol.* 2020;**217**:297-304. Doi: 10.1016/j.ajo.2020.05.001.
15. **Ozer MD, Altinkurt E, Yilmaz YC, Gedik AC, Alparslan N.** The Surgical Outcomes of Limbal Allograft Transplantation in Eyes Having Limbal Stem Cell Deficiency. *J Curr Ophthalmol.* 2020;**32(2)**:132-141. Doi: 10.4103/JOCO.JOCO\_91\_20.
16. **Arora R, Dokania P, Manudhane A, Goyal JL.** Preliminary results from the comparison of simple limbal epithelial transplantation with conjunctival limbal autologous transplantation in severe unilateral chronic ocular burns. *Indian J Ophthalmol.* 2017;**65(1)**:35-40. Doi: 10.4103/0301-4738.202312.
17. **Korkmaz I, Palamar M, Egrilmez S, Gurdal M, Yagci A, Barut Selver O.** Evaluation of Limbal Stem Cell Transplant Success in Ocular Chemical Injury. *Exp Clin Transplant.* 2023;**21(8)**:684-690. Doi: 10.6002/ect.2021.0393.
18. **Sprogyte L, Park M, Di Girolamo N.** Pathogenesis of Alkali Injury-Induced Limbal Stem Cell Deficiency: A Literature Survey of Animal Models. *Cells.* 2023;**12(9)**:1294. Doi: 10.3390/cells12091294.
19. **Castro-Munozledo F.** Review: Corneal epithelial stem cells, their niche and wound healing. *Mol Vis* 2013;**19**:1600-1613.
20. **Sejpal K, Ali MH, Maddileti S, Basu S, Ramappa M, Kekunnaya R, et al.** Cultivated limbal epithelial transplantation in children with ocular surface burns. *JAMA Ophthalmol.* 2013;**131(6)**:731-736. Doi: 10.1001/jamaophthalmol.2013.2308.

### Authors Designation and Contribution

Andintia Aisyah Santoso; Medical Doctor: *Concepts, Design, Literature Search, Data Acquisition, Manuscript Preparation, Manuscript Editing, Manuscript Review.*

Muhammad Rheza Hilfaziyan Lubis; Medical Doctor: *Literature Search, Data Acquisition, Manuscript Preparation, Manuscript Editing, Manuscript Review.*

Mohammad Amin Rais Perfernandi Ilham; Medical Doctor: *Literature search, Data Acquisition, Manuscript Preparation, Manuscript Editing, Manuscript Review.*