

Real-World Indications for Intravitreal Anti-VEGF Injections in Tertiary Eye Care Hospitals: A Multi-Center Study

Sidrah Riaz¹, Muhammad Tariq Khan², Qasim Lateef Chaudhry³,
Sofia Lateef Chaudhry⁴, Faraz Munir⁵
^{1,2,5}Akhtar Saeed Medical and Dental College, Lahore ^{3,4}Lahore Medicare
Eye Center

PJO – Official Journal of
Ophthalmological Society of Pakistan



This work is licensed under a Creative
Commons Attribution-Non-
Commercial 4.0 International License.

ABSTRACT

Purpose: To evaluate the spectrum of ocular conditions requiring intravitreal anti-VEGF therapy in a hospital-based setting.

Study Design: Retrospective study.

Place and Duration: Places of study were Akhtar Saeed Medical and dental college, Lahore and Lahore Medicare Eye center. Duration of study was six months, from 1st. July 2023 to 31st. December 2023.

Methods: Medical records of patients who had intravitreal anti-VEGF injections were retrieved. Patients less than 50 years of age, patients who had retinopathy of prematurity, known case of cancer or malignant disease and any other ocular disease were excluded. Name, gender, type and indication for intravitreal injection were noted for each patient.

Results: Out of 547 patients 53.2% were females and 46.8% were males. One eye of each patient was included in the study. The most used anti VEGF was Aflibercept (46.4%), followed by Ranibizumab (30.9%) and Bevacizumab (22.7%). No major difference was observed among gender distribution regarding three anti VEGF used. The most common indication was diabetic macular edema 146(26.69%) eyes, followed by wet Age-related macular degeneration in 128 (23.40%) eyes and vitreous hemorrhage due to retinal vascular diseases seen in 118 (21.60%) eyes. Other indications were proliferative diabetic retinopathy (19.74%), central retinal vein occlusion (5.48%) and branch retinal vein occlusion (1.28%). Three minor indications were central serous chorioretinopathy (1.09%), macular telangiectasia (0.36%) and posterior uveitis (0.36%).

Conclusion: Intravitreal anti-VEGF therapy was most indicated for diabetic macular edema, wet age-related macular degeneration and retinal vascular complications, with Aflibercept being the most frequently used agent in this hospital-based cohort.

Keyword: Anti-Vascular Endothelial Growth Factor, Bevacizumab, Aflibercept, Ranibizumab, macular Neovascularization (MNV), Age Related Macular Degeneration (AMD)

How to Cite this Article: Riaz S, Khan MT, Chaudhry QL, Chaudhry SL, Munir F. Real-World Indications for Intravitreal Anti-VEGF Injections in Tertiary Eye Care Hospitals: A Multi-Center Study. 2025;41(3):295-298.

Doi: 10.36351/pjo.v41i3.1994

*Correspondence: Sidrah Riaz
Akhtar Saeed Medical and Dental College
Lahore.
Email: sidrah893@yahoo.com*

*Received: November 30, 2024
Revised: April 18, 2025
Accepted: May 24, 2025*

INTRODUCTION

The first anti VEGF for intravitreal use was approved by FDA in 2004.^{1,2} Since then it has revolutionized management of retinal diseases in clinical ophthalmology. One of the roles of anti VEGF is to provide a window period by stabilizing vascular permeability, in the meantime patient can optimize systemic control which can prevent serious ocular complications.

A considerable population of Pakistan is affected by Diabetes Mellitus, and Pakistan ranks third globally in the total number of adults (ages 20–79) living with diabetes, following China and India.^{3,4} On the other hand, wet age-related macular degeneration (AMD) has no definite treatment except control of risk factors.⁵ The overall prevalence of AMD in the Pakistani population is 5.27%, with dry AMD being more common (65.7%) than wet AMD (34.3%).⁶ Out of a total 21.78 million people affected by blindness and vision impairment, AMD is responsible for visual impairment in 0.05 million people.⁷ Poor economy compounded with lower health awareness has badly affected diabetic patients from low socioeconomic strata. The situation got worse for non-affording community with recent ban on Bevacizumab (Avastin) by the Government of Pakistan, on September 2023 for an indefinite period of time, after grievous visual loss in 68 patients who suffered from Endophthalmitis after intravitreal Avastin.⁸ The Avastin was relatively cheaper and affordable as compared to Aflibercept (Eylea) and Ranibizumab (Patizra).

METHODS

The study was approved by the Institutional review board/Ethical review board (LMC/MS/42). Medical records of patients who underwent intravitreal Anti VEGF injection in Akhtar Saeed Medical and dental college, Lahore and Lahore Medicare Eye center from 1st July 2023 to 31st December 2023 were retrieved. A total of 547 patients were selected based on the inclusion criteria. Informed consent was taken before intravitreal anti VEGF injection. Name, gender, type and indication for intravitreal injection were recorded for each patient. All injections were injected by senior consultant ophthalmologists after informed and written consent in operation theater under sterilized conditions. Patients above 50 years of age with clear indication of intravitreal anti VEGF were included and pediatric patients, patients less than 50 years of age, Retinopathy of Prematurity, known case of cancer or malignant disease and anterior uveitis were excluded. The data was analyzed by SPSS-25 and presented in forms of bar chart and table.

RESULTS

Total 547 patients were included in our study. Out of these, 291(53.2%) were females and 256(46.8%) were males. Amongst elected cases, 179 (32.72%) were from

Farooq Hospital and 368(67.28%) were from Lahore Eye Medicare Hospital. The most used anti VEGF was Aflibercept (Eylea) used in 46.4%, followed by Ranibizumab (Patizra) in 30.9% and Bevacizumab (Avastin) in 22.7%. No major difference was observed among gender distribution regarding the three anti VEGF (Figure 1). The most common indication for intravitreal anti VEGF was diabetic macular edema in 146 (26.69%) patients, followed by wet AMD with Macular neovascularization (MNV) in 128(23.40%) and vitreous hemorrhage in 118(21.60%) patients. Other indications were Proliferative diabetic retinopathy (PDR), Central retinal vein occlusion (CRVO) and branch retinal vein occlusion (BRVO). Three minor indications were central serous chorio retinopathy, macular telangiectasia and posterior uveitis (Figure 2).

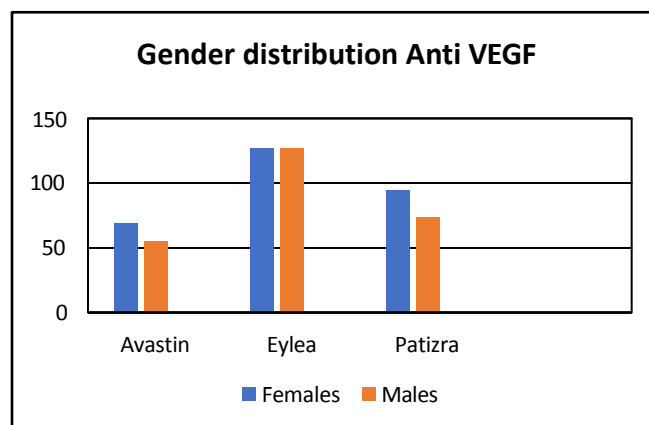


Figure1: Gender distribution of anti VEGF injections.

DISCUSSION

The systemic metabolic disorders like diabetes can cause vascular and structural damage to retina. On the other hand, hypertension and other vascular disorders of autoimmune or infective etiology can cause vascular abnormalities. In these cases, VEGF and other inflammatory mediators play a pivotal role. Retinal vessels status which are easily visible in clear media can predict extent of vascular abnormalities in other body parts like heart and kidney. With an increased incidence of diabetes mellitus, number of patients with diabetic ocular complications is on the rise.^{9,10}

In patients with diabetic retinopathy complicated with macular edema, early use of anti-VEGF drugs can significantly improve vision, with high clinical

Figure 2: Table showing details of indications for anti VEGF injection with gender distribution

Serial No.	Indications	Bevacizumab		Aflibercept		Ranibizumab		Total
		Female	Male	Female	Male	Female	Male	
1.	Diabetic macular edema	20	15	44	15	36	16	146(26.69%)
2.	MNV	13	10	31	39	11	24	128(23.40%)
3.	Vitreous hemorrhage	11	10	31	42	16	08	118(21.60%)
4.	PDR	21	17	11	21	22	16	108(19.74%)
5.	CRVO	04	02	06	06	06	06	30(5.48%)
6.	BRVO	00	00	02	00	04	01	07(1.28%)
7.	CSCR	00	00	02	03	00	02	06(1.09%)
8.	Macular telangiectasia	00	00	00	00	00	02	02(0.36%)
9.	Post. Uveitis(vasculitis)	00	01	00	01	00	00	02(0.36%)
Total No. of Patients		69(12.61%)	55 (10.05%)	127(23.22%)	127(23.22%)	95(17.37%)	74(13.53%)	547(100%)
		124(22.67%)		254(46.43%)		169(30.90%)		

efficacy.¹¹ The cost of treatment for diabetic ocular complication has put a huge economic burden on developing countries like Pakistan. The role of anti VEGF in treatment of retinal vascular diseases is evidence based and can save vision threatening complications.^{12,13} Other options that can be considered include Pan retinal photocoagulation which can result in narrowing of visual fields.^{14,15}

Our data analysis shows that common diseases needing anti VEGF seen in our study were diabetic macular edema 26.69%, vitreous hemorrhage 21.60% and proliferative retinopathy 19.74%. These indications constitute two thirds of the total patients highlighting the magnitude of the problem. Our results are consistent with the results of a study conducted in Africa where top three indications for intravitreal anti VEGF were Diabetic macular edema, vein occlusion and vitreous hemorrhage.¹⁶ Study from Europe showed MNV associated with wet type AMD as the major indication for Anti VEGF.¹⁷ However, a study from China has shown similar trend as ours.¹⁸

The incidence of AMD is on the rise in Pakistan.¹⁹ In our study 128 cases of MNV were treated with anti VEGF, with Aflibercept as the most common anti VEGF. Studies have shown promising results of anti VEGF in cases of wet AMD.²⁰

Before the ban by the Government in 2023, Avastin was used as the most common anti VEGF injection in retinal disorders but now Eylea has shown a significant rise. The ban on Avastin injection has resulted in serious issues in treating non-affording community. Since October 2024, the use of Avastin for intravitreal use has been approved under strict SOPs which are being followed in selective centers only benefiting poor community.²¹

Strength of study is the real-world data from two tertiary care centers of Pakistan where patients are referred from other localities. The limitations of study are small sample size and its retrospective design. The study should be conducted on a wider scale and in a prospective manner to get a bigger picture for practical implementations.

CONCLUSION

Intravitreal anti-VEGF therapy was most commonly indicated for diabetic macular edema, wet age-related macular degeneration, and retinal vascular complications, with Aflibercept being the most frequently used agent in this hospital-based cohort.

Funding: This study was not funded by any organization.

Patient's Consent: Researchers followed the guide lines set forth in the Declaration of Helsinki.

Conflict of Interest: Authors declared no conflict of interest.

Ethical Approval: The study was approved by the Institutional review board/Ethical review board (LMC/MS/42).

REFERENCES

1. Chopra R, Preston GC, Keenan TDL, Mulholland P, Patel PJ, Balaskas K, et al. Intra vitreal injections: past trends and future projections within a UK tertiary hospital. *Eye (Lond)*. 2022;**36**(7):1373-1378. Doi:10.1038/s41433-021-01646-3.

2. **Nikkhah H, Karimi S, Ahmadi H, Azarmina M, Abrishami M, Ahoor H, et al.** Intravitreal Injection of Anti-vascular Endothelial Growth Factor Agents for Ocular Vascular Diseases: Clinical Practice Guideline. *J Ophthalmic Vis Res.* 2018;**13**(2):158-169. Doi:10.4103/jovr.jovr_50_18.
3. **Bhutta ZA, Ul Haq Z, Basit A.** Diabetes in Pakistan: addressing the crisis. *Lancet Diabetes Endocrinol.* 2022;**10**(5):309-310. Doi:10.1016/S2213-8587(22)00102-4.
4. **Sabiha B, Bhatti A, Fan KH, John P, Aslam MM, Ali J, et al.** Assessment of genetic risk of type 2 diabetes among Pakistanis based on GWAS-implicated loci. *Gene.* 2021;**783**:145563. Doi:10.1016/j.gene.2021.145563.
5. **Fleckenstein M, Keenan TDL, Guymer RH, Chakravarthy U, Schmitz-Valckenberg S, Klaver CC, et al.** Age-related macular degeneration. *Nat Rev Dis Primers.* 2021;**7**(1):31. Doi:10.1038/s41572-021-00265-2.
6. **Tariq M, Iqbal K, Zaheer W.** Prevalence of Age-Related Macular Degeneration at a Tertiary Care Hospital in Pakistan. *Ann. King Edw. Med. Univ.* 2022;**27**(4):551-556.
7. **Hassan B, Ahmed R, Li B, Noor A, Hassan ZU.** A comprehensive study capturing vision loss burden in Pakistan (1990-2025): Findings from the Global Burden of Disease (GBD) 2017 study. *PLoS One.* 2019;**14**(5):e0216492. Doi:10.1371/journal.pone.0216492.
8. **Shaheen F, Farooq H, Amjad M.** Impact of the Nationwide Avastin Ban at a Tertiary Eye Care Hospital in Pakistan. *Cureus.* 2024;**16**(7):e65199. Doi:10.7759/cureus.65199.
9. **Feldman- Billard S, Dupas B.** Eye disorders other than diabetic retinopathy in patients with diabetes. *Diabetes Metab.* 2021;**47**(6):101279. Doi:10.1016/j.diabet.2021.101279.
10. **Burton MJ, Ramke J, Marques AP, Bourne RRA, Congdon N, Jones I, et al.** The Lancet Global Health Commission on Global Eye Health: vision beyond 2020. *Lancet Glob Health.* 2021;**9**(4):e489-e551. Doi:10.1016/S2214-109X(20)30488-5.
11. **Li T, Gu Z, Zhang Y, Li J, Du J, Fu Y.** Effect of Anti-VEGF drugs on diabetic Retinopathy- Microaneurysms: A correlation study. *Pak J Med Sci.* 2024;**40**(11):2648-2652. Doi:10.12669/pjms.40.11.9439.
12. **Maturi RK, Glassman AR, Josic K, Antoszy k AN, Blodi BA, Jampol LM, et al.** DRCR Retina Network. Effect of Intravitreal Anti-Vascular Endothelial Growth Factor vs Sham Treatment for Prevention of Vision-Threatening Complications of Diabetic Retinopathy: The Protocol W Randomized Clinical Trial. *JAMA Ophthalmol.* 2021;**139**(7):701-712. Doi:10.1001/jamaophthalmol.2021.0606.
13. **Chatziralli I, Loewenstein A.** Intravitreal Anti-Vascular Endothelial Growth Factor Agents for the Treatment of Diabetic Retinopathy: A Review of the Literature. *Pharmaceutics.* 2021;**13**(8):1137. Doi:10.3390/pharmaceutics13081137.
14. **Tatsumi T.** Current Treatments for Diabetic Macular Edema. *Int J Mol Sci.* 2023;**24**(11):9591. Doi:10.3390/ijms24119591.
15. **Chatziralli I.** Ranibizumab for the treatment of diabetic retinopathy. *Expert Opin Biol Ther.* 2021;**21**(8):991-997. Doi: 10.1080/14712598.2021.1928629.
16. **Shuaib A, Hassan S.** Indications for intravitreal anti vascular endothelial growth factor in Kano, Northwestern, Nigeria. *Int J Res Med Sci.* 2016;**4**:2533-2535. Doi: 10.18203/2320-6012.ijrms20161891
17. **Cornel S, Adriana ID, Mihaela TC, Speranta S, Algerino S, Mehdi B, et al.** Anti-vascular endothelial growth factor indications in ocular disease. *Rom J Ophthalmol.* 2015;**59**(4):235-242. PMID: 29450313; PMCID: PMC5712945.
18. **Xu M, Fan R, Fan X, Shao Y, Li X.** Progress and Challenges of Anti-VEGF Agents and Their Sustained-Release Strategies for Retinal Angiogenesis. *Drug Des Devel Ther.* 2022;**16**:3241-3262. Doi:10.2147/DDDT.S383101.
19. **Tariq M, Iqbal K, Zaheer W.** Prevalence of Age-Related Macular Degeneration at a Tertiary Care Hospital in Pakistan. *Ann. King Edw. Med. Univ.* 2021;**27**(4). Doi: 10.21649/akemu.v27i4.4889
20. **Fabre M, Mateo L, Lamaa D, Baillif S, Pagès G, Demange L, et al.** Recent Advances in Age-Related Macular Degeneration Therapies. *Molecules.* 2022;**27**(16):5089. Doi: 10.3390/molecules27165089.
21. **Shaheen F, Farooq H, Amjad M.** Impact of the Nationwide Avastin Ban at a Tertiary Eye Care Hospital in Pakistan. *Cureus.* 2024;**16**(7):e65199. Doi:10.7759/cureus.65199.

Authors Designation and Contribution

Sidrah Riaz; Professor: *Design, Literature Search, Data Acquisition, Data Analysis, Statistical Analysis, Manuscript Preparation, Manuscript Editing, Manuscript Review.*

Muhammad Tariq Khan; Professor: *Concepts, Data Acquisition, Manuscript Editing.*

Qasim Lateef Chaudhry; Consultant Ophthalmologist: *Concepts, Data Acquisition, Manuscript Editing.*

Sofia Lateef Chaudhry; Consultant Ophthalmologist: *Literature Search, Data Acquisition, Manuscript Editing.*

Faraz Munir; Senior Registrar: *Literature Search, Statistical Analysis, Manuscript Editing, Manuscript Review.*