

# Anatomical and Visual Outcomes of Macular Hole Surgeries



Syed Ali Afsar Rizvi<sup>1</sup>, Saliha Naz<sup>2</sup>, Syed Fawad Rizvi<sup>3</sup>, Fatima Tariq<sup>4</sup>, Muhammad Kaunain Ghoghari<sup>5</sup>  
<sup>1-5</sup>LRBT Tertiary Teaching Eye Hospital, Korangi, Karachi

## ABSTRACT

**Purpose:** To determine the anatomical and visual outcomes of macular hole surgeries in patients with full thickness macular holes in a tertiary care center of Pakistan.

**Study Design:** Interventional case series.

**Place and Duration of Study:** LRBT tertiary teaching eye hospital Korangi, Karachi, from January 2023 to July 2023.

**Methods:** Twenty-four eyes of 24 patients were included by convenient sampling. Patients with Gass stage 2,3 and 4 were included in the study after an informed consent. The study omitted holes with stage 1, macular cysts, and secondary macular holes. Visual acuity of the patients was recorded in decimal notations based on Snellen's chart. OCT was done in all patients. After peri-bulbar anesthesia, 25G pars plana vitrectomy was performed with C3F8 gas as internal tamponade. All individuals were followed up on day 1, week 1, 6, 12 and 24. OCT images were taken to see hole closure. The paired sample t-test was used to compare the difference of pre and post operative VA. P-values less than 0.05 were considered statistically significant.

**Results:** Out of 24 eyes, 62.5% were males and 37.5% were females. The mean age of the patients was 65.3±9.1 years. Visual acuity significantly improved after surgery with p-value of <0.05.

**Conclusion:** Macular hole surgery using 25G pars plana vitrectomy with C3F8 gas tamponade yielded favorable anatomical and visual outcomes in patients with full-thickness macular holes.

**Keywords:** Idiopathic Macular Hole, Pars Plana Vitrectomy, Optical Coherence Tomography.

**How to Cite this Article:** Rizvi SAA, Naz S, Rizvi SF, Tariq F, Ghoghari MK. Anatomical and Visual Outcomes of Macular Hole Surgeries. A Hospital – Based Case Series. 2025;41(2):121-124. Doi: 10.36351/pjo.v41i2.1872

---

*Correspondence: Syed Ali Afsar Rizvi  
LRBT Tertiary Teaching Eye Hospital, Korangi, Karachi  
Email: aliafsar.super.go@hotmail.com*

---

*Received: June 08, 2024  
Revised: January 01, 2025  
Accepted: January 29, 2025*

## INTRODUCTION

Knapp in 1869 was the first individual to describe a macular hole with traumatic origin.<sup>1</sup> Terminology “hole in the macula” was coined by Ogilvie in nineteenth centuries. Macular holes can be idiopathic macular holes (IMH), initiated by traction on the vitreous at the foveal center or caused by trauma referred to as traumatic macular holes.<sup>2</sup> High myopia with posterior staphyloma can also result in macular

hole formation.<sup>3</sup> Macular holes can settle, remain stable, or advance to full thickness macular holes as explained by Gass.<sup>4</sup>

Prior to 1991, macular holes were regarded as an irreversible condition. However, over the past two decades, advancements in surgical techniques have established macular hole repair as a standard procedure, significantly enhancing visual outcomes. The conventional approach involves performing a pars plana vitrectomy, inducing a posterior vitreous detachment, and injecting a long-acting gas tamponade, with patients advised to maintain prone positioning for a minimum of two weeks. However, recent evidence suggests that prone positioning may not be necessary, and shorter-duration tamponading agents can be effectively utilized, potentially simplifying postoperative care.<sup>5</sup>

This study reports the outcomes of macular hole surgeries conducted at a single center over a 6-month period. The objective was to evaluate the results of a multi-surgeon series of procedures. Anatomical outcomes were assessed using optical coherence tomography (OCT), while visual outcomes were measured using Snellen's chart.

## METHODS

The study was conducted at LRBT Free Base Eye Hospital Karachi from January 2023 to July 2023. Institutional Ethical Review Committee approved the study (**LRBT/TTEH/ERC/4407/01**). Twenty four eyes of 24 patients were treated for macular holes after informed consent. Senior vitreoretinal surgeons performed all the surgeries. Individuals with a Gass stage 2, 3 and 4 were included and stage 1 macular holes, macular cysts and holes that were secondary in origin were excluded. A complete history and clinical examination was performed including slit lamp biomicroscopy and dilated funduscopy using 20D lens. Visual acuity of the patients were recorded in decimal notations based on Snellen's chart. Macular hole staging was evaluated by a SD-OCT. For local anesthesia 2-3ml of lidocaine 2% and Bupivacaine 0.7% was injected in the peribulbar area under aseptic measures. A 25G microincision pars plana vitrectomy was done with an internal tamponade using C3F8 gas. Two weeks of strict face down positioning was instructed. All individuals were followed at 1st day, 1st week, 6th, 12th and 24th week and OCT images were acquired to document hole closure (Figure 1 & 2).

Data were stored and analyzed using IBM-SPSS version 23. Counts with percentages were reported for gender, age group and hole closure. Mean and Standard deviation were given on pre and post

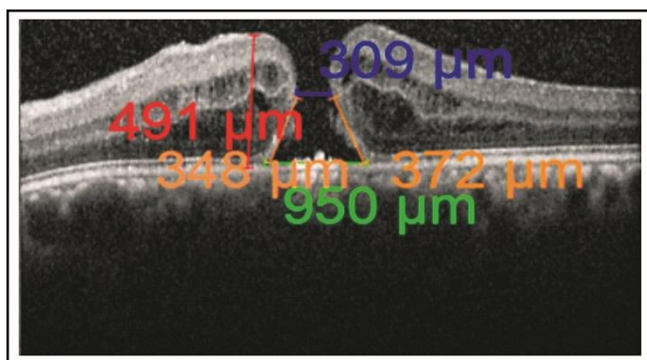


Figure 1: Pre-operative OCT.

operative Visual acuity (VA). Paired sample t-test was used to compare the difference of pre and post operative VA. P-values of less than 0.05 was considered statistically significant. Bar diagrams were also used to give graphical presentation of study findings.

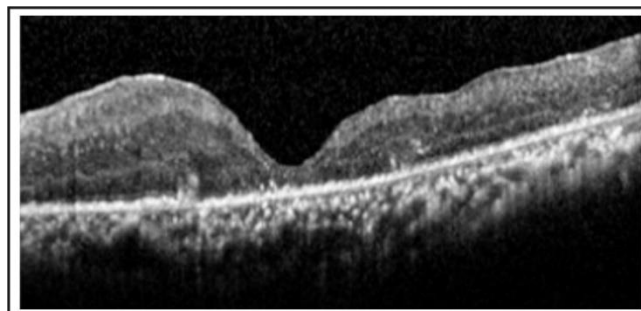


Figure 2: Post-operative OCT.

## RESULTS

Twenty four cases of idiopathic macular hole underwent surgeries at LRBT free base eye hospital from January 2024 to July 2024. The baseline characteristics were noted. Mean age of the patients was 65.3±9.1 years. There were 62.5% (n=15) males and 37.5% (n=9) females.

Anatomical hole closure was achieved in 83.3% (20 of 24) eyes and 18 individuals had improved postoperative visual acuity (75%). There was a

Table 1: Baseline Characteristics of Studied Samples (n=24).

Characteristics	n	%	
Gender	Male	15	62.5
	Female	9	37.5
Age Group	≤65 years	12	50.0
	>65 years	12	50.0
	Mean ±SD	65.3	±9.1
Hole Closure	Yes	20	83.3
	No	4	16.7

Table 2: Comparison of Pre and post Operative Visual acuity.

Parameters	Pre-operative Mean±SD	Post-operative Mean±SD	p-value
Total (n=24)	0.08±0.05	0.24±0.16	<0.001*
Male (n=15)	0.09±0.07	0.27±0.18	0.002*
Female (n=9)	0.08±0.03	0.27±0.18	0.044*
Age ≤65 years (n=12)	0.08±0.04	0.22±0.19	0.023*
Age >65 years (n=12)	0.09±0.07	0.22±0.19	0.003*
Hole Closure (n=20)	0.08±0.05	0.27±0.16	<0.001*
Failure of Hole Closure (n=4)	0.10±0.10	0.11±0.06	0.82

statistically significant improvement in visual acuity and also in the number of hole closures ( $p < 0.05$ ).

## DISCUSSION

Our results show that there was a significant improvement in visual acuity stratified by various parameters. Similarly there were significant number of eyes which had successful hole closure. This data highlights that macular hole surgeries result in significant visual improvement, particularly in cases with successful anatomical closure.

Recently macular hole surgeries have shown an increased rate of success when combined with internal limiting membrane (ILM) peeling.<sup>6</sup> Indocyanine green (ICG) dye can further facilitate this process by giving a better visualization of the ILM.<sup>7,8</sup> Nevertheless, there are reports indicating adverse effects with the use of this dye due to the toxic effects of ICG on the retinal pigment epithelium as demonstrated by Haritoglou C et al.<sup>9</sup>

Following successful peeling of the ILM, it is removed, and vitreous substitutes are injected to create a tamponade effect. A notable advancement in this field is the inverted ILM flap technique, first introduced by Michalewska and colleagues.<sup>10,11</sup> In this technique, instead of removing the parafoveal ILM after peeling, it is folded and inverted into the full-thickness macular hole (FTMH) to act as a scaffold for tissue regeneration.

Another side effect of macular hole surgery is cataract which in some cases is removed at the time of macular hole surgery.

The formation of a macular hole typically begins with the detachment of the posterior hyaloid around the macular region. Initially, the hyaloid remains adhered to the center of the fovea, leading to the development of a cystic space accompanied by intraretinal splitting. This process subsequently disrupts the outer retinal layers and results in the opening of the foveolar floor, ultimately culminating in the formation of a full-thickness macular hole.<sup>12</sup> This foveal pseudocyst formation is also been described and visualized on the basis of an OCT.<sup>13</sup>

Surgical closure of macular holes via different techniques aims at restoring vision by re-establishing normal retinal architecture and retinal cell functions. However, it remains a challenge in some cases.<sup>14</sup>

According to one study, visual acuity

improvement following macular hole surgery continued throughout the first three years after pars plana vitrectomy (PPV) and remained stable in a significant proportion of patients thereafter. Final best-corrected visual acuity (BCVA) was found to be positively correlated with better preoperative BCVA and more favorable postoperative optical coherence tomography (OCT) parameters.<sup>15</sup>

The duration of onset of symptoms is a direct predictive factor for the macular hole size which tend to be smaller with shorter symptom duration and associated with complete hole closure without bare RPE resulting in a better visual acuity and lower recurrence rate after surgery.<sup>16</sup> The anatomical success rate reported in this study was 83.3%, this rate is consistent with earlier studies.<sup>17,18</sup> The rate of macular hole closure and its visual outcome over the last decade have considerably improved with newer techniques.<sup>19,20</sup>

Small sample size, short follow-up duration, single-center design, lack of randomization and inclusion of multi-surgeon data are the limitations of this study.

Future prospects include conducting studies with larger sample sizes and longer follow-up periods to assess long-term outcomes. Comparing different surgical techniques, refining postoperative management, and exploring preoperative factors that predict success could further improve patient outcomes. Additionally, the use of advanced imaging technologies and collaboration across multicenter studies may enhance the understanding of macular hole surgery and lead to optimized treatment protocols.

## CONCLUSION

Microincision vitreoretinal surgery with the use of internal tamponade have shown great success in terms of its visual and anatomical outcome. Nevertheless in order to consolidate the long term effect of this procedure further studies with a larger group and a longer follow up are required.

**Funding:** None.

**Patient's Consent:** Researchers followed the guidelines set forth in the Declaration of Helsinki.

**Conflict of Interest:** Authors declared no conflict of interest.

**Ethical Approval:** The study was approved by the Institutional review board/Ethical review board (LRBT/TTEH/ERC/4407/01).

## REFERENCES

1. **Budoff G, Bhagat N, Zarbin MA.** Traumatic Macular Hole: Diagnosis, Natural History, and Management. *J Ophthalmol.* 2019;**2019**:5837832. Doi: 10.1155/2019/5837832.
2. **Liu W, Grzybowski A.** Current Management of Traumatic Macular Holes. *J Ophthalmol.* 2017;**2017**:1748135. Doi: 10.1155/2017/1748135.
3. **Ikuno Y.** Overview of the complications of high myopia. *Retina.* 2017;**37**(12):2347-2351. Doi: 10.1097/IAE.0000000000001489
4. **Ezra E.** Idiopathic full thickness macular hole: natural history and pathogenesis. *Br J Ophthalmol.* 2001;**85**(1):102-108. Doi: 10.1136/bjo.85.1.102
5. **Grewal DS.** Is Facedown Positioning Necessary after Routine Macular Hole Surgery? *Ophthalmol Retina.* 2019;**3**(5):385-387. Doi:10.1016/j.oret.2019.02.003
6. **Rezende FA, Ferreira BG, Rampakakis E, Steel DH, Koss MJ, Nawrocka ZA, et al.** Surgical classification for large macular hole: based on different surgical techniques results: the CLOSE study group. *Int J Retina Vitreous.* 2023;**9**(1):4. Doi: 10.1186/s40942-022-00439-4.
7. **Jun SY, Kong M.** Microperimetric analysis of eyes after macular hole surgery with indocyanine green staining: a retrospective study. *BMC Ophthalmol.* 2023;**23**(1):430. Doi: 10.1186/s12886-023-03161-3.
8. **Ando F, Sasano K, Ohba N, Hirose H, Yasui O.** Anatomic and visual outcomes after indocyanine green-assisted peeling of the retinal internal limiting membrane in idiopathic macular hole surgery. *Am J Ophthalmol* 2004;**137**:609–614. Doi: 10.1016/j.ajo.2004.06.044
9. **Haritoglou C, Gandorfer A, Gass CA, Kampik A.** Histology of the vitreoretinal interface after staining of the internal limiting membrane using glucose 5% diluted indocyanine and infracyanine green. *Am J Ophthalmol* 2004;**137**:345–348. Doi: 10.1016/S0002-9394(03)00845-6
10. **Michalewska Z, Michalewski J, Adelman RA, Nawrocki J.** Inverted internal limiting membrane flap technique for large macular holes. *Ophthalmology.* 2010;**117**(10):2018-2025. Doi: 10.1016/j.ophtha.2010.02.011.
11. **Michalewska Z, Nawrocki J.** Vitrectomy with the inverted internal limiting membrane flap technique in eyes with full-thickness macular hole and dry age-related macular degeneration. *Eur J Ophthalmol.* 2021;**31**(3):1320-1325. Doi: 10.1177/1120672120921376.
12. **Gaudric A, Haouchine B, Massin P, Paques M, Blain P, Erginay A.** Macular hole formation: new data provided by optical coherence tomography. *Arch Ophthalmol.* 1999;**117**(6):744-751. Doi: 10.1001/archophth.117.6.744.
13. **Rossi T, Bacherini D, Caporossi T, Telani S, Iannetta D, Rizzo S, et al.** Macular hole closure patterns: an updated classification. *Graefes Arch Clin Exp Ophthalmol.* 2020;**258**(12):2629-2638. Doi: 10.1007/s00417-020-04920-4.
14. **Abdul-Kadir MA, Lim LT.** Update on surgical management of complex macular holes: a review. *Int J Retina Vitreous.* 2021;**7**(1):75. Doi: 10.1186/s40942-021-00350-4.
15. **Elhusseiny AM, Schwartz SG, Flynn HW Jr, Smiddy WE.** Long-Term Outcomes after Macular Hole Surgery. *Ophthalmol Retina.* 2020;**4**(4):369-376. Doi: 10.1016/j.oret.2019.09.015.
16. **Kumar A, Gogia V, Kumar P, Sehra S, Gupta S.** Evaluation of predictors for anatomical success in macular hole surgery in Indian population. *Indian J Ophthalmol.* 2014;**62**(12):1141-1145. Doi: 10.4103/0301-4738.149135.
17. **Mahmoud TH.** Insight into Long-Term Outcomes after Macular Hole Surgery. *Ophthalmol Retina.* 2020;**4**(4):377. Doi:10.1016/j.oret.2019.11.012
18. **Zgolli H, Abdelhedi C, Mabrouk S, Fekih O, Zghal I, Malek I, et al.** Prognostic factors for visual recovery after successful large macular hole surgery using the inverted flap technique. *J Fr Ophtalmol.* 2023;**46**(9):1069-1078. Doi: 10.1016/j.jfo.2023.02.019.
19. **Zhao PP, Wang S, Liu N, Shu ZM, Zhao JS.** A Review of Surgical Outcomes and Advances for Macular Holes. *J Ophthalmol.* 2018;**2018**:7389412. Doi: 10.1155/2018/7389412.
20. **Chaudhary V, Sarohia GS, Phillips MR, Zeraatkar D, Xie JS, Nanji K, et al.** Role of Positioning after Full-Thickness Macular Hole Surgery: A Systematic Review and Meta-Analysis. *Ophthalmol Retina.* 2023;**7**(1):33-43. Doi: 10.1016/j.oret.2022.06.015.

## Authors Designation and Contribution

Syed Ali Afsar Rizvi; Resident: *Concepts, Design, Literature search, Data acquisition, Manuscript preparation, Manuscript editing.*

Saliha Naz; Senior Consultant Ophthalmologist: *Concepts, Manuscript review.*

Syed Fawad Rizvi; Consultant Ophthalmologist: *Concepts, Design, Manuscript review.*

Fatima Tariq; Resident: *Data analysis, Statistical analysis.*

Muhammad Kaunain Ghoghari; Resident: *Literature search, Data acquisition, Data analysis, Statistical analysis.*