

A Unique Case of Optic Disc Pit in One Eye with CSC in Other Eye

Haroon Tayyab, Akhwand Abdul Majeed Jawad

Pak J Ophthalmol 2015, Vol. 31 No. 3

See end of article for authors affiliations

Correspondence to:
Haroon Tayyab
Sharif Medical & Dental College,
Lahore
Email: haroontayyab79@google
mail.com

A 41 year old male patient presented in eye OPD of Sharif Medical City Hospital in January 2015 with complaints of recent onset subacute painless decrease in vision along with metamorphopsia in his right eye. On detailed ophthalmic examination, he was found to have Central Serous Chorioretinopathy (CSC) in his right eye and optic disc pit in the left eye. He was investigated with FFA and OCT and treated with focal argon laser in his right eye and systemic rifampicin 300mg for 3 months. His symptoms recovered after one month of laser and systemic therapy.

We report this unique case of CSC in one eye and optic disc pit without maculopathy in other eye. Despite successful treatment of CSC, this patient stands at risk of developing more severe maculopathy in the left eye which may warrant surgical treatment in future.

Keywords: Central serous chorioretinopathy, Optic disc pit, Optical coherence tomography.

Von Graefe was the first ophthalmologist to originally describe Central Serous Chorioretinopathy (CSC) in 1866 and used the term "récurantcentral retinitis" for CSC at that time.¹ It was Gass who later described CSC in further detail through fundus fluorescein angiography (FFA) and coined the term "Central Serous Chorioretinopathy".²

Current evidence from research shows that primary culprit in the pathogenesis of CSC is choroidal hyper-permeability, stasis and ischemia.^{3,4} This concept has been further strengthened by recent reports of choroidal thickening shown by Enhanced Depth Imaging Optical Coherence Tomography (EDI-OCT).⁵

The role played by Retinal Pigment Epithelium (RPE) still remains elusive although older research pointed out that malfunctioning RPE is the prime responsible for CSC.^{6,7} Perhaps the most authentic theory about role of RPE in pathogenesis of CSC includes compromised RPE function due to increased choroidal hydrostatic pressure; this may also be evidenced by the presence of Pigment Epithelial Detachments (PED) that often accompanies CSC.

Other possible mechanisms promoting CSC (through which CSC happens) include hormones like glucocorticoids and catecholamines, H. pylori infection and newly discovered role of genetics in CSC.⁸⁻¹¹

Optic disc pit is another pathology that may result in morphologically similar elevation of neurosensory retina as seen in CSC.¹² The origin of subretinal fluid in cases of optic disc pit is still being debated. Recent advances in imaging modalities like high resolution optical coherence tomography (OCT) have hinted on the origin of the subretinal fluid from cerebrospinal fluid. One such study showed a communication between gap in lamina cribrosa present in optic pit and macular schisis associated with optic disc pit.¹³ Other most plausible source of subretinal fluid is vitreous.

CASE REPORT

A 41 year old male, goldsmith by profession, presented in the out-patient's department (OPD) of Sharif Medical City Hospital on 10th January, 2015

with primary complaints of mildly decreased vision in his right eye for last 2 months. His other complaints included metamorphopsia and micropsia. His only other significant information in history was multiple pet cats in his house. This was his first visit to an ophthalmologist in his life and his apprehension was clearly visible and he was very much concerned about his declining vision.

On detailed examination of his eyes, his best corrected visual acuity (BCVA) in right eye was 20/30 and 20/20 unaided in left eye. He documented metamorphopsia on Amsler chart testing. Both eyes had unremarkable anterior segment and vitreal examination. On retinal examination, a dome shaped elevation of neurosensory retina at posterior pole was noted in right eye and a temporally placed optic disc pit was noted in left eye. Rest of retinal examination was unremarkable. After a strong clinical suspicion of CSC in right eye, patient was advised FFA and Spectral Domain OCT of macula in both eyes. Also, His H.pyloranti body titer was (carried out which returned to be) normal.

His pre intervention OCT and FFA pictures are shown in Fig. 1, 2 and 3, OCT which showed neurosensory retina in the right eye with serous fluid underneath retina; FFA showed an extrafoveal ink blot focal leaking point more than 1500 μ m away from the centre of fovea (Fig. 4). OCT and FFA of macula in left eye were within normal limits. Based on these findings, a clinical diagnosis of CSC in the right eye and optic disc pit (without pit maculopathy) was made in the left eye.

Since the nature of his job demanded a healthy binocular vision and also considering his apprehension, (we started exploring treatment options for this gentleman. After discussing various treatment options with the patients) we decided to opt for focal argon laser in the right eye along with tablet Rifampicin 300 mg twice a day for 3 months.

After one month of focal laser and systemic therapy, his BCVA improved to 20/20 in the right eye with significant resolution of metamorphopsia. OCT was repeated at one month and 2 months post treatment as shown in Fig. 5.

On further follow-up, he was maintaining the BCVA and OCT findings recorded at 2 months without any significant complaints. Systemic Rifampicin was discontinued after 3 months of its commencement.

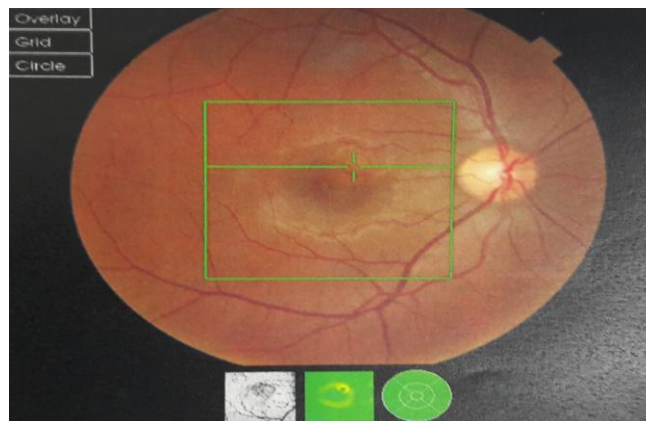


Fig. 1: CSC in posterior pole of right eye.

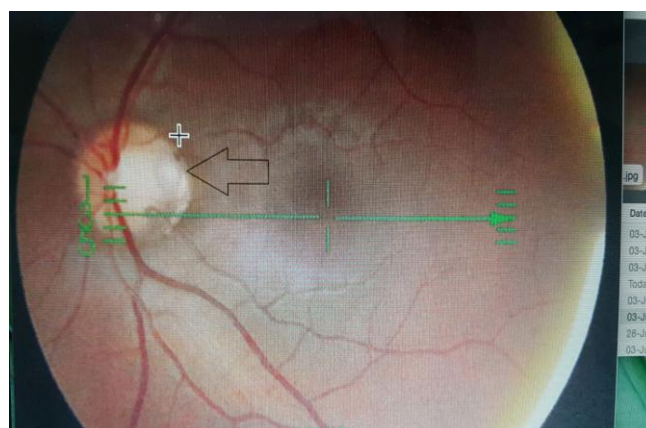


Fig. 2: Optic disc pit in left eye




Fig. 3: Sub retinal fluid seen on OCT

DISCUSSION

CSC is a well - documented ophthalmological entity that presents more commonly in middle age males.¹⁴ Over the years, diagnosis of CSC has been simplified

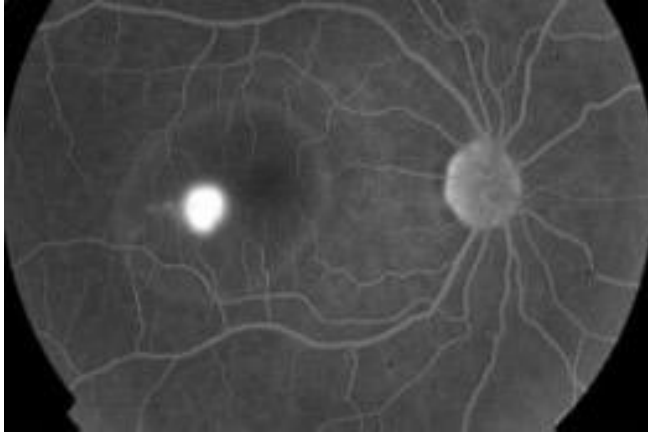


Fig. 4: Focal hotspot temporal to fovea.

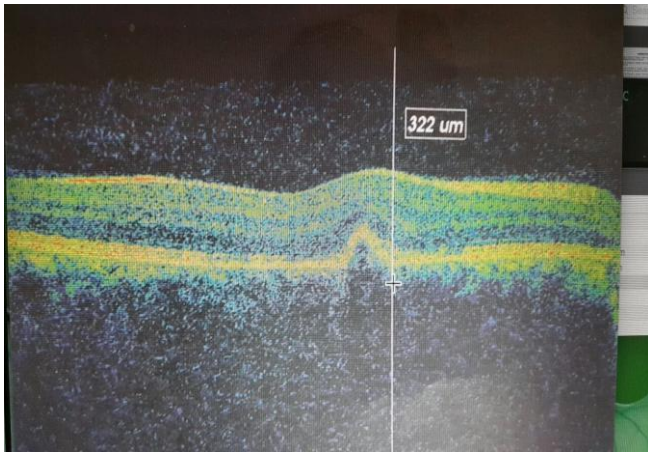


Fig. 5: Resolved subretinal fluid

with the help of FFA and OCT^{15,16}. There are various infective, inflammatory and neoplastic conditions that can lead to serous macular elevation (and thus) which may mimic the morphological appearance of CSC. These entities include Vogt Kayonagi Harada (VKH) disease, Presumed Ocular Histoplasmosis syndrome (POHS), white dot syndromes and granulomas of posterior pole due to infective or neoplastic infiltration of choroid. All these entities can be differentiated from typical CSC on the basis of history, examination and ophthalmic investigations. Optic disc pit is another pathology that can lead to central macular elevation and may cause similar symptoms like that of CSC. Despite morphological resemblance, optic pit maculopathy can be readily differentiated from typical CSC on clinical examination alone. When examining optic disc maculopathy on OCT, (one finds) the presence of retinoschisis that may precede the development of serous macular elevation.¹⁷

We report this unique case with optic disc pit in one eye with typical CSC in the contralateral eye of a young healthy man. Although, we were able to successfully treat CSC in this patient, he still remains at a risk of recurrence in that eye which is known to occur after successful focal argon laser treatment of CSC. The patient shall remain on alert of developing any visual symptoms (decreased BVCA, metamorphosis and change in refraction) in his eye with optic disc pit since the management may not be laser and rifampicin and he may have to succumb to surgery for definitive treatment of optic disc maculopathy.

Author's Affiliation

Dr. Haroon Tayyab
Assistant Professor
Sharif Medical and Dental College
Lahore

Dr. Akhwand Abdul Majeed Jawad
Consultant Ophthalmologist
Sharif Medical and Dental College
Lahore

Role of Authors

Dr. Haroon Tayyab
Case diagnosis, documentation and treatment,
literature search and discussion writing.

Dr. Akhwand Abdul Majeed Jawad
Retrieval of pictorial evidence, write up of
introduction and abstract.

REFERENCES

1. **VonGraefe A.** Uebercentralerecidivierende retinitis. Graefes Arch Clin Exp Ophthalmol. 1866; 12: 211-5.
2. **Gass JD.** Pathogenesis of disciform detachment of the neuroepithelium. Am J Ophthalmol. 1967; 63: 1-139.
3. **Yannuzzi LA.** Central serous chorioretinopathy: a personal perspective. Am J Ophthalmol. 2010; 149: 361-3.
4. **Prünte C, Flammer J.** Choroidal capillary and venous congestion in central serous chorioretinopathy. Am J Ophthalmol. 1996; 121: 26-34.
5. **Spaide RF, Koizumi H, Pozzoni MC.** Enhanced depth imaging spectral - domain optical coherence tomography. Am J Ophthalmol. 2008; 146: 496-500.
6. **Mudvari SS, Goff MJ, Fu AD, McDonald HR, Johnson RN, Ai E, Jumper JM.** The natural history of pigment epithelial detachment associated with central serous chorioretinopathy. Retina. 2007; 27: 1168-73.
7. **Spitznas M.** Pathogenesis of central serous retinopathy:

- A new working hypothesis. *Graefes Arch ClinExp Ophthalmol.* 1986; 224: 321-4.
8. **Barnes PJ.** Corticosteroid effects on cell signalling. *Eur Respir J.* 2006; 27: 413-26.
 9. **Byrne MF, Kerrigan SW, Corcoran PA, Atherton JC, Murray FE, Fitzgerald DJ, Cox DM.** Helicobacter pylori binds von Willebrand factor and interacts with GPIb to induce platelet aggregation. *Gastroenterology.* 2003; 124: 1846-54.
 10. **Giusti C.** Association of Helicobacter pylori with central serous chorioretinopathy: Hypotheses regarding pathogenesis. *Med Hypotheses.* 2004; 63: 524-7.
 11. **Weenink AC, Borsje RA, Oosterhuis JA.** Familial chronic central serous chorioretinopathy. *Ophthalmologica.* 2001; 215: 183-7.
 12. **Haruta M, Kamada R, Umeno Y, Yamakawa R.** Vitrectomy for optic disc pit-associated maculopathy with or without preoperative posterior vitreous detachment. *Clin Ophthalmol.* 2012; 6: 1361-4.
 13. **Gowdar JP, Rajesh B, Giridhar A, Gopalakrishnan M, Hussain R, Thachil T.** An insight into the pathogenesis of optic disc pit-associated maculopathy with enhanced depth imaging. *JAMA Ophthalmol.* 2015; 133: 466-9.
 14. **Haimovici R, Koh S, Gagnon DR, Lehrfeld T, Wellik S.** Central Serous Chorioretinopathy Case - Control Study Group. Risk factors for central serous chorioretinopathy: A case-control study. *Ophthalmology.* 2004; 111: 244-9.
 15. **Li L, Li DH, Yang ZK, Bian AL, Chen YX, Dong FT.** Analysis of fundus fluorescein angiography, indocyanine green angiography and choroidal thickness in central serous chorioretinopathy. *Zhonghua Yan KeZaZhi.* 2012; 48: 878-82.
 16. **Lin D, Chen W, Zhang G, Huang H, Zhou Z, Cen L, Chen H.** Comparison of the optical coherence tomographic characters between acute Vogt-Koyanagi-Harada disease and acute central serous chorioretinopathy. *BMC Ophthalmol.* 2014; 14: 87.
 17. **Michalewski J, Michalewski Z, Nawrocki J.** Spectral domain optical coherence tomography morphology in optic disc pit associated maculopathy. *Indian J Ophthalmol.* 2014; 62: 777-81.