

# Immediate Effect of Intravitreal Bevacizumab Injection on Intraocular Pressure



Kanwal Zareen Abbasi<sup>1</sup>, Ameera Jameel<sup>2</sup>  
Wajeeha Rasool<sup>3</sup>, Bilal Humayun Mirza<sup>4</sup>, Misbah Munshi<sup>5</sup>  
<sup>1</sup>HBS Medical and Dental College, Islamabad, <sup>2,3,4,5</sup>Rawalpindi Medical University and Allied Hospital

## ABSTRACT

**Purpose:** Raised intra ocular pressure following intravitreal Bevacizumab is a potential side effect which can be clinically significant. The aim of the study was to evaluate short term changes in intraocular pressure after intravitreal Bevacizumab injection.

**Study Design:** Quasi experimental study.

**Place and Duration of Study:** Benazir Bhutto Hospital, Rawalpindi from January 2021 to July 2021.

**Methods:** This study includes 88 eyes of 88 patients who received intravitreal Bevacizumab injection. Both females and males between the ages of 10 and 80 years, with any indication for intravitreal Bevacizumab, were included. Intraocular pressure (IOP) was measured before injection, immediately after injection at 0 minutes, at 30 minutes and at 60 minutes. Paired t test was used to compare post injection changes in IOP from baseline.

**Results:** All except one eye recoded increase in IOP immediately after injection. It returned to normal range in 35 (39.8%) eyes at 30 minutes and at 60 minutes 78 (88.6%) eyes had normal IOP. Highest mean IOP was recorded immediately after injection which was 30.89+5.648 and that reduced to 23.08+4.516 at 30 minutes and 18.14+2.623 at 60 minutes. Paired t test showed that the changes were significantly higher from baseline 13.30+2.78 at these intervals after injection.

**Conclusion:** An increase in intraocular pressure after intravitreal Bevacizumab injection is a frequent occurrence; however, for the majority of patients, it is transient and returns to normal levels within one hour.

**Key Words:** Bevacizumab, Intraocular pressure, Anti-Vascular endothelial growth factor.

**How to Cite this Article:** Abbasi KZ, Jameel A, Rasool W, Mirza BH, Munshi M. Immediate Effect of Intravitreal Bevacizumab Injection on Intraocular Pressure. 2024;40(2):197-202. **Doi: 10.36351/pjo.v40i2.1710**

---

*Correspondence: Kanwal Zareen Abbasi  
HBS Medical and Dental College, Islamabad  
Email: dr\_maninoor\_abbasi@yahoo.com*

---

*Received: August 06, 2023  
Accepted: February 20, 2024*

## INTRODUCTION

Intravitreal injections are common in ophthalmology practice and indications for these injections are rapidly increasing. However, a transient rise in intraocular pressure (IOP) is a common finding.<sup>1</sup> Raised IOP occurs as a result of increase in vitreous volume. The raised IOP compromises the retinal and optic nerve

blood supply and in the long run, decrease the retinal nerve fiber layer thickness.<sup>2</sup>

Intravitreal injection of anti-vascular endothelial growth factor (Anti -EGF) has an important role in the treatment of various posterior segment diseases. Commonly used Anti-VEGF agents are Ranibizumab, Aflibercept and Bevacizumab.<sup>3</sup> However, FDA has approved Ranibizumab and Aflibercept for ocular use and Bevacizumab is used off label because of its cost effectiveness.<sup>4,5</sup>

Rise in the intraocular pressure can block the juxtapupillary retinal and optic nerve head blood flow proportional to its quantitative rise. It can also cause damage to retinal ganglion cell layer.<sup>6</sup>

Aim of this study was to identify the acute rise in the intraocular pressure following administration of intravitreal injection of Bevacizumab as even a transient acute significant IOP elevation can be harmful for the already compromised optic nerve.

### METHODS

It was a quasi-experimental study in which sample was collected by non-probability, consecutive technique. Sample size was calculated using WHO formula and 88 eyes of 88 patients were included in the study. The study was conducted from 13-01-2021 to 12-07-2021 at department of ophthalmology Benazir Bhutto Hospital, Rawalpindi which is a teaching hospital affiliated with Rawalpindi medical university. Both females and males of age group 10 to 80 years with any indication for intravitreal Bevacizumab were included in the study. We excluded patients who were pseudophakic for less than three months, patients who received intravitreal steroid during last 3 months, those who were injected intravitreal antibiotic during last one month, patients who were already diagnosed with glaucoma and patients who did not give consent to be part of study.

The study was approved by ethical committee of Rawalpindi Medical University. Before injection, IOP was measured with Perkins tonometer. Injection was given in the inferotemporal quadrant 3.5-4mm from limbus in the dose of 1.25mg in 0.05ml. Moxifloxacin 0.5% was instilled in the conjunctival sac. IOP was measured immediately post-injection (at zero minute) and repeated at 30 and 60 minutes.

Written informed consent was taken from the patients for participation in the study. Statistical analysis was performed with SPSS version 25. Descriptive statistics were used to describe data. Qualitative variables were presented as frequency and percentage while quantitative data was presented as mean and standard deviations. Paired t test was used to compare mean changes in intraocular pressure from baseline. Independent t test was used to compare mean IOP between males and females. P value of <0.05 was taken significant.

### RESULTS

A total of 88 eyes from 88 patients received intravitreal Bevacizumab injection. The mean age was 58.30+8.62 years. There were 50(56.8%) females and 38(43.2%) males. At baseline IOP was normal in 87 eyes (98.9%). One eye had higher IOP of 22mmHg but no glaucoma. Immediately after receiving intravitreal Bevacizumab injection, rise in IOP was seen in all eyes except one. Highest IOP was 46mmHg which was recorded in two eyes. In 35 eyes (39.8%) IOP returned to normal range at 30 minutes. Highest recorded IOP was 36mmHg which was recorded in 3 eyes. After one hour 10 (11.8%) patients continued to have high IOP. Highest IOP recorded at 60 minutes was 26mmHg which was seen in one eye (Table 1).

The statistical analysis for comparing mean changes in IOP from baseline showed mean IOP before intravitreal injection was 13.30+2.78 mmHg which significantly increased to 30.89+5.65 mmHg (p value 0.0001) immediately after injection (at 0 minutes). Measurement at 30 minutes and 60 minutes interval showed decline in mean IOP though it was significantly higher from baseline. At 30 minutes, it reduced to 23.08+4.52 mmHg (p value 0.0001), which further reduced to 18.14+2.62mmHg (p value 0.001) Figure 1.

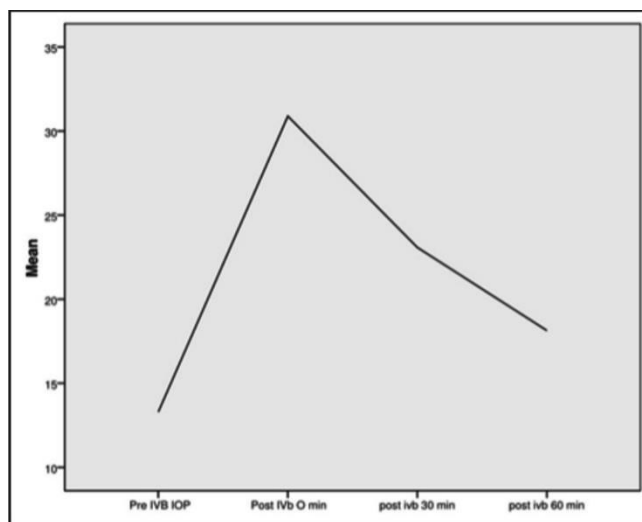


Figure 1: Mean change in IOP following intravitreal injection of Bevacizumab.

Table 1: Intraocular pressure recorded at baseline and following intravitreal Bevacizumab injection.

IOP	Baseline	Immediately after Injection	30 Minutes after Injection	60 Minutes after Injection
Normal (up to 21mmHg)	87 (98.9%)	1 (1.1%)	35 (39.8%)	78 (88.6%)
22-32mmHg	1 (1.1%)	61 (69.3%)	49 (55.7%)	10 (11.4%)
Above 32 mmHg	----	26 (29.5%)	4(4.5%)	-----
Total	88	88	88	88

Data stratified for gender showed higher IOP in male patients at baseline and subsequent post injection intervals. Significant difference was seen at 60 minutes post injection, where males had significantly higher mean IOP than females ( $18.84 \pm 2.73$  versus  $17.60 \pm 2.42$ ) with p value of 0.27 (Table 2).

**Table 2:** Relationship between gender of patients and mean changes in IOP.

IOP Measured in mmHg	Malen=38	Female n= 50	P value
Baseline	12.68 $\pm$ 2.13	13.76 $\pm$ 3.12	0.58
Immediately (0 minutes)	31.42 $\pm$ 5.82	30.48 $\pm$ 5.53	0.442
30 minutes	23.65 $\pm$ 4.59	22.64 $\pm$ 4.45	0.298
60 minutes	18.84 $\pm$ 2.73	17.60 $\pm$ 2.42	0.027*

Independent t test used for statistical analysis.

## DISCUSSION

The intravitreal injections of anti-VEGF agents are now a common procedure performed by ophthalmologists for various vitreoretinal diseases such as diabetic macular edema, age related macular disease, choroidal neovascularization and some other retinal pathologies. Our results showed a rise in IOP immediately after injection which was decreased at 30 and 60 minutes but remained higher than the baseline values. Mechanism of raised IOP include increase in vitreous volume, direct toxic effect of anti VEGF on trabecular meshwork, an inflammatory response to Anti VEGF and mechanical blockage of trabecular meshwork by protein aggregates.<sup>7</sup> Therefore, it remains an important clinical question about the relationship between Anti VEGF and Increase IOP after its use, so that timely recognition may postpone the onset or progression of Glaucoma, which results in visual loss.<sup>7</sup>

In a study of Ariana M. et al, it was noted that intravitreal injection caused a significant but transient rise in IOP that started to decrease within 5 minutes which is in accordance with results of our study. According to them, this becomes significant in patients of ocular hypertension and glaucoma, specifically those who have disc damage and visual field defects.<sup>7</sup> They noted that prophylactic Apraclonidine 1% appears to have some role in lowering IOP plus they have also discussed the role of anterior chamber paracentesis in patients with ocular hypertension and glaucoma who received the intravitreal injections<sup>7</sup>.

Similar results were recorded by other authors irrespective of presence of glaucomatous or non-glaucomatous eyes.<sup>8,9</sup> Zafar A et al, showed that IOP was increased during initial 5 minutes and normalized at the end of one-hour post-injection.<sup>10</sup>

Qureshi et al, studied the effect of ocular decompression at injection site just before intravitreal injection. They divided 100 eyes into 2 groups, decompression followed by IVB and IVB without decompression.<sup>11</sup> They noted that there was a significant IOP rise in both groups but this rise was comparatively less in decompression group. This proved that decompression just before intravitreal injection is quite useful in limiting IOP rise in early post injection period.

Lobue SA, et al, noted that IOP spikes occurred in the first 10 minutes and resolved at the end of first hour. They concluded that IOP spikes were high and prolonged only when small needles of 31 gauge were used in patients who had history of glaucoma plus those who had pre-injection IOP  $>25$  mmHg.<sup>12</sup> Similarly, Luqman F. et al, concluded that immediate post intravitreal acute rise in IOP was not detrimental except in patients who had higher baseline IOP ( $>15$  mmHg) and such patients definitely need some prophylactic measures to decrease these spikes.<sup>13</sup>

One of the prophylactic measures is anterior chamber paracentesis. Khodabande A. et al, used this measure in their study and concluded that this measure is quite effective in reducing the post injection IOP spikes. Effect of post injection IOP spike on peripapillary RNFL thickness was statistically insignificant.<sup>14</sup> Soheilian M, et al, had contradictory results to that of Khodabande A, et al. They noticed acute IOP rise and significant RNFL loss 3 months after injection, but as far as anterior chamber paracentesis is concerned both groups of authors had same opinion that this prophylactic measure prevents acute IOP elevation.<sup>14,15</sup>

In another study, topographical sub-analysis of RNFL showed nasal region was more prone to damage. This nasal RNFL damage is probably responsible for sudden change in visual acuity immediately after intravitreal injection and there are chances that it may cause permanent injuries to optic nerve head which can result in glaucomatous damage.<sup>15,16</sup>

Association of needle size with acute IOP rise after intravitreal injections showed that IOP rise was

more with thinner needles which was most likely because of no or less conjunctival vitreous reflux with these needles.<sup>17,18</sup>

Gomez-Mariscal M. et al, conducted a study to evaluate the effect of intravitreal anti-VEGF injections on IOP and optic nerve head. They evaluated the acute and chronic changes in these parameters. They concluded by saying that repeated intravitreal injections could cause the irreversible changes in optic nerve head structures. They recommended to carry out further studies on large scale so that the long-term effects of these injections on optic nerve head structures can be determined.<sup>19</sup> In patients of retinopathy of prematurity, post injection IOP rise returned to normal within 15 minutes of injecting anti-VEGF agents.<sup>20</sup>

Nuzzi et al, have found the ocular decompression technique as a useful measure to prevent the post injection IOP rise.<sup>21</sup> On the other hand, Mehanna MM, et al, and Pokrosvkaya O, et al, provided the evidence of topical pressure lowering drops (brimonidine and apraclonidine dorzolamide combination respectively) as the effective prophylactic measure to prevent post injection IOP rise.<sup>22,23</sup>

Limitations of our study were small sample size and lack of analysis of irreversible effect of intraocular pressure on optic nerve head whether short term or long term.

## CONCLUSION

After analyzing all the research work done in past and comparing it with our results, it is very much clear that intravitreal injections of anti-VEGF agents cause an acute rise in intraocular pressure which can cause optic nerve damage. So, the need of the hour is to take preventive measures. Different preventive measures are anterior chamber paracentesis, ocular decompression, choice of needle size, technique of injection and prophylactic topical IOP lowering medications. New researches should be done to choose the best possible measure.

## ACKNOWLEDGEMENTS

We like to thank our colleagues who helped us during the research process and to our patients who participated in this research work.

**Conflict of Interest:** Authors declared no conflict of interest.

**Ethical Approval:** The study was approved by the Institutional review board/Ethical review board (R-72/RMU).

## REFERENCES

1. **Gumus G, Berhuni M, Ozturkman C.** The short term effects of intravitreal Bevacizumab injection on intraocular pressure, cornea, iridocorneal angle and anterior chamber. *Ther Adv Ophthalmol.* 2022;14. Doi: 10.1177/25158414221133772
2. **de Vries VA, Bassil FL, Ramdas WD.** The effects of intravitreal injections on intraocular pressure and retinal nerve fiber layer: a systematic review and meta-analysis. *Sci Rep.* 2020;10(1):13248. Doi: 10.1038/s41598-020-70269-7.
3. **Hoguet A, Chen PP, Junk AK, Mruthyunjaya P, Nouri-Mahdavi K, Radhakrishnan S, et al.** The Effect of Anti-Vascular Endothelial Growth Factor Agents on Intraocular Pressure and Glaucoma. A report by American Academy of Ophthalmology. *Ophthalmology.* 2019;126(4):611-622. Doi: 10.1016/j.ophtha.2018.11.019
4. **Levin AM, Chaya CJ, Kahook MY, Wirostko BM.** Intraocular pressure elevation following intravitreal anti-VEGF injections: short and long term considerations. *JGlucoma.* 2021;30(12):1019-1026. Doi: 10.1097/IJG.0000000000001894
5. **Kahkonen M, Tuuminen R, Aaltonen V.** Longterm effects of intravitreal Bevacizumab and aflibercept on intraocular pressure in wet age-related macular degeneration. *BMC Ophthalmology.* 2021;21:312. Doi: 10.1186/s12886-021-02076-1
6. **Rathi R, Patel S, Jain A, Jaiswal K Nema N.** Intraocular pressure Elevation following intravitreal injection of Bevacizumab, Ranibizumab and Triamcinolone Acetonide. *Pak J Ophthalmol.* 2023;39(3):190-195. Doi: 10.36351/pjo.v39i3.1626
7. **Ariana ML, Craig JC, Malik YK, Barbara MW.** Intraocular pressure elevation following intravitreal antiVEGF Injections: Short and long term considerations. *Glaucoma.* 2021;30(12):1019-1026.
8. **Felfeli T, Hostovsky A, Trussart R, Yan P, Brent MH, Mandelcorn ED.** Hypotensive efficacy of topical brimonidine for intraocular pressure spikes following intravitreal injections of antivascular endothelial growth factor agents: a randomised crossover trial. *Br J Ophthalmol.* 2019;103(10):1388-1394. Doi: 10.1136/bjophthalmol-2018-312603.

9. **Ansari EA and Huraira H.** Intravitreal Ranibizumab/Lucentis (IVTL) injections in Glaucoma Patients-Intraocular pressure elevation and the use of anterior chamber paracentesis. *Int J Clin Exp Ophthalmol.* 2017;**1**:033-041. Doi:10.29328/journal.hceo.1001005
10. **Zafar R, Rizwan A, Naem BA, Asghar A, Obaid N.** Immediate effect of intravitreal Bevacizumab injection on intraocular pressure. *Pak J Ophthalmol.* 2020;**36**(4):412-417. Doi:10.36351/pjo.v36i4.1109
11. **Qureshi NA, Mansoor H, Ahmed S, Zafar S, Asif M.** Reducing intraocular-pressure spike after intravitreal Bevacizumab injection with ocular decompression using a sterile cotton swab soaked in proparacaine 0.5%: A Quasi-Experimental study. *Taiwan J Ophthalmol.* 2016;**6**(2):75–78. Doi:10.1016/j.tjo.2015.12.003
12. **Lobue SA, Gindina S, Saba NJ, Chang T, Davis MJ, Fish S.** Clinical Features Associated with Acute Elevated Intraocular Pressure After Intravitreal Anti-VEGF Injections. *Clin Ophthalmol.* 2023;**13**(17):1683-1690. Doi:10.2147/OPTH.S414212
13. **Luqman F, Bibi H, Mukhtar M, Zafar F, Ahmed H, Khizer MA, et al.** Transient Intraocular Pressure Fluctuations After Intravitreal Bevacizumab Injection in Proliferative Diabetic Retinopathy Patients: A Prospective Study. *Cureus.* **15**(9):e45371. Doi:10.7759/cureus.45371
14. **Khodabande A, Zarei M, Khojasteh H, Mohammadi M, Khameneh EA, Torkashvand A.** The effect of acute rises in intraocular pressure after intravitreal Bevacizumab injection on the peripapillary retinal nerve fiber layer thickness and the role of anterior chamber paracentesis. *J Curr Ophthalmol.* 2021;**33**(1):12-16. Doi: 10.4103/JOCO.JOCO\_214\_20.
15. **Soheilian M, Karimi S, Mosavi S.** Effects of intravitreal injection of Bevacizumab with or without anterior chamber paracentesis on intraocular pressure and peripapillary retinal nerve fibre layer thickness: a prospective study. *Graefes Arch Clin Exp Ophthalmol.* 2017;**255**(9):1705-1712. Doi: 10.1007/s00417-017-3702-1.
16. **Buonamassa R, Viggiano P, Boscia F.** Immediate effect of anti-VEGF injections on optic nerve head: Correlation between intraocular pressure and anatomical peripapillary changes. *European J Ophthalmol.* 2023;11206721231210749. Doi:10.1177/11206721231210749
17. **Ersan I, Yildiz A.** Reflux after intravitreal injection: an anterior segment optical coherence tomography study. *Adv Ophthalmol Vis Syst.* 2020;**10**(1):18–21. Doi:10.15406/aovs.2020.10.00376
18. **Hamidil NA, Gunes IB, Baykara M.** Evaluation of intraocular pressure change and anterior segment parameters after intravitreal Bevacizumab Injection-Cannula size matters. *Saudi J Ophthalmol.* 2021;**34**(4):247-250. Doi: 10.4103/1319-4534.322606
19. **Gómez-Mariscal M, Puerto B, Muñoz-Negrete FJ, de Juan V, Rebolleda G.** Acute and chronic optic nerve head biomechanics and intraocular pressure changes in patients receiving multiple intravitreal injections of anti-VEGF. *Graefes Arch Clin Exp Ophthalmol.* 2019;**257**(10):2221-2231. Doi: 10.1007/s00417-019-04354-7.
20. **Kato A, Okamoto Y, Oshika T.** Short term intraocular pressure changes after intravitreal injection of Bevacizumab for retinopathy of prematurity. *JPN J Ophthalmol.* 2019;**63**:262-268. Doi: 10.1007/s10384-019-00661-y
21. **Nuzzi R, Scalabrin S, Becco A.** Reduction of Intraocular Pressure Spikes Due to Intravitreal Bevacizumab Injections by Scleral Indentation with Cotton Swab or Digital Ocular Massage: Innovative Techniques Compared. *Clin Ophthalmol.* 2020;**14**:2533–2541. Doi: 10.2147/OPTH.S263474
22. **Hypotensive Effect of Topical Brimonidine Tartarate on Intra-Ocular Pressure Spikes Following Intravitreal Injection of Ranibizumab** Mahmoud Mohamed Mehanna, Tarek Hussein Ali, Amir Aly El Din Abousamra, Amr Ahmed Said,\*.*Egyptian J Cataract Refract Surg.* 2021;**27**:23-27.
23. **Pokrosvkaya O, Dooley I, Babiker S, Croghan C, Hartnett C.** Cullinane Anthony. The effect of intraocular pressure lowering medications on pressure spike associated with intravitreal injection. *Eye Rep.* 2018;**4**(1):1-6. Doi: 10.16964/er.v4i1.57

### Authors Designation and Contribution

Kanwal Zareen Abbasi; Associate Professor: *Concepts, Design, Literature search, Data acquisition, Data analysis, Statistical analysis, Manuscript preparation, Manuscript editing, Manuscript review.*

Ameera Jameel; Postgraduate Trainee: *Concepts, Design, Literature search, Data acquisition, Data analysis, Statistical analysis, Manuscript preparation, Manuscript editing, Manuscript review.*

Wajeeha Rasool; Senior Registrar: *Concepts, Design, Literature search, Data acquisition, Data analysis, Statistical analysis, Manuscript preparation, Manuscript editing, Manuscript review.*

Bilal Humayun Mirza; Senior Registrar: *Concepts, Design, Literature search, Data acquisition, Data analysis, Statistical analysis, Manuscript preparation, Manuscript editing, Manuscript review.*

Misbah Munshi; Senior Registrar: *Concepts, Design, Literature search, Data acquisition, Statistical analysis, Manuscript preparation, Manuscript review.*

