

# Pilot Study of Seamless Diplen Membrane for Pterygium Excision

Maria Cervatiuc<sup>1</sup>, Anait B. Azibekyan<sup>2</sup>, Eldor Jonnazarov<sup>3</sup>, Nodirbek U. Dzhapiev<sup>4</sup>, Bashirkhon A. Tursunov<sup>5</sup>

<sup>1,3</sup>Sechenov First Moscow State Medical University (Sechenov University), Moscow, Russia,

<sup>2</sup>Moscow City Clinical Hospital No. 12 after V.M. Buyanov, Moscow, Russia,

<sup>4</sup>Peoples' Friendship University of Russia, Moscow, Russia.

<sup>5</sup>Tajik National University (TNU), Dushanbe, Tajikistan

PJO – Official Journal of Ophthalmological Society of Pakistan

Volume 2023;39(4):349-353.

Doi: 10.36351/pjo.v39i4.1667



This work is licensed under a Creative Commons Attribution-Non-Commercial 4.0 International License

## ABSTRACT

We report a technique of fixation of rotational flap of the conjunctiva in primary surgical treatment of pterygium using a biodegradable adhesive Diplen membrane. A 78 years old patient was referred to ophthalmology department in September 2022 for treatment of pterygium of right eye. Primary pterygium surgery was performed using fixed rotational flap of the conjunctiva. In this method, the conjunctival flap is rotated to close the open sclera and fixed with a biodegradable adhesive Diplen membrane. The flap did not undergo ischemic changes, retained its original position and fully took root. Inflammatory and allergic reactions to the components of the membrane were not observed. Seamless fixation of conjunctival flap using an adhesive Diplen membrane is a safe, cost-effective and reliable method of treating pterygium.

**Key Words:** Pterygium, Diplen membrane, Rotational flap.

**How to Cite this Article:** Author. Pilot Study of Seamless Diplen Membrane for Pterygium Excision.

---

*Correspondence: Maria Cervatiuc  
Department of Oncology, Radiotherapy and Plastic Surgery, I.M. Sechenov First Moscow State Medical University (Sechenov University), Moscow, Russia  
Email: dr.maria.cervatiuc@gmail.com*

---

*Received: March 07, 2023*

*Accepted: September 08, 2023*

## INTRODUCTION

Pterygium is a degenerative disease characterized by hypertrophied subconjunctival tissue that takes on a triangular shape, extending from the medial canthus of the eye to the border of cornea or beyond, with the vertex directed towards pupil.<sup>1</sup> There are numerous theories to explain pathogenesis of this disease. However, it is generally believed to be multifactorial, with ultraviolet radiation considered as the main trigger. Other factors include changes in the tear film, imbalances of cytokines and growth factors, genetic mutations, viral infections and immunological disorders. Modern classification also takes into

account the rate of fibrovascular growth, progressive, potential and histological features.<sup>2</sup>

Initially, pterygium is asymptomatic but patients may experience complaints of dry eyes, burning, itching, and tearing. As the pterygium grows towards the optical zone, visual acuity decreases, often necessitating surgical treatment.<sup>2,3</sup> Despite the availability of various surgical methods, such as pterygium removal alone or in combination with beta-irradiation, conjunctival transplants, amniotic membrane transplantation and multilayer keratoplasty, pterygium recurrence remains a significant problem in ophthalmology.

There are chances of potential relapses and repeated operations. Therefore, surgical intervention for pterygium should aim not only to eliminate the lesion but also to prevent relapses. It is necessary to apply modified methods to cover exposed sclera with subsequent transposition of the conjunctival flap, auto-transplantation of the conjunctiva, transplantation of the amniotic membrane, peripheral layered keratoplasty (with significant in growth).<sup>4</sup>

Extensive research has demonstrated safety and effectiveness of the gold standard treatment for pterygium, which involves excision of pterygium and conjunctival plasty. The risk of pain and inflammatory syndromes is significantly reduced when the open sclera is covered with autologous conjunctival tissue. However, the standard procedure of suturing conjunctival grafts has certain disadvantages, such as inadequate attachment of large conjunctival grafts within the graft itself, jagged edges of the graft, the development of retraction between the sutures, and prolonged suturing time compared to the actual excision of pterygium and graft dissection.<sup>5</sup>

However, it is worth noting that the standard procedure for fixing conjunctival grafts with sutures has certain disadvantages: inadequate attachment of large conjunctival grafts placed inside the graft itself; uneven (jagged) edges of the graft, retraction between

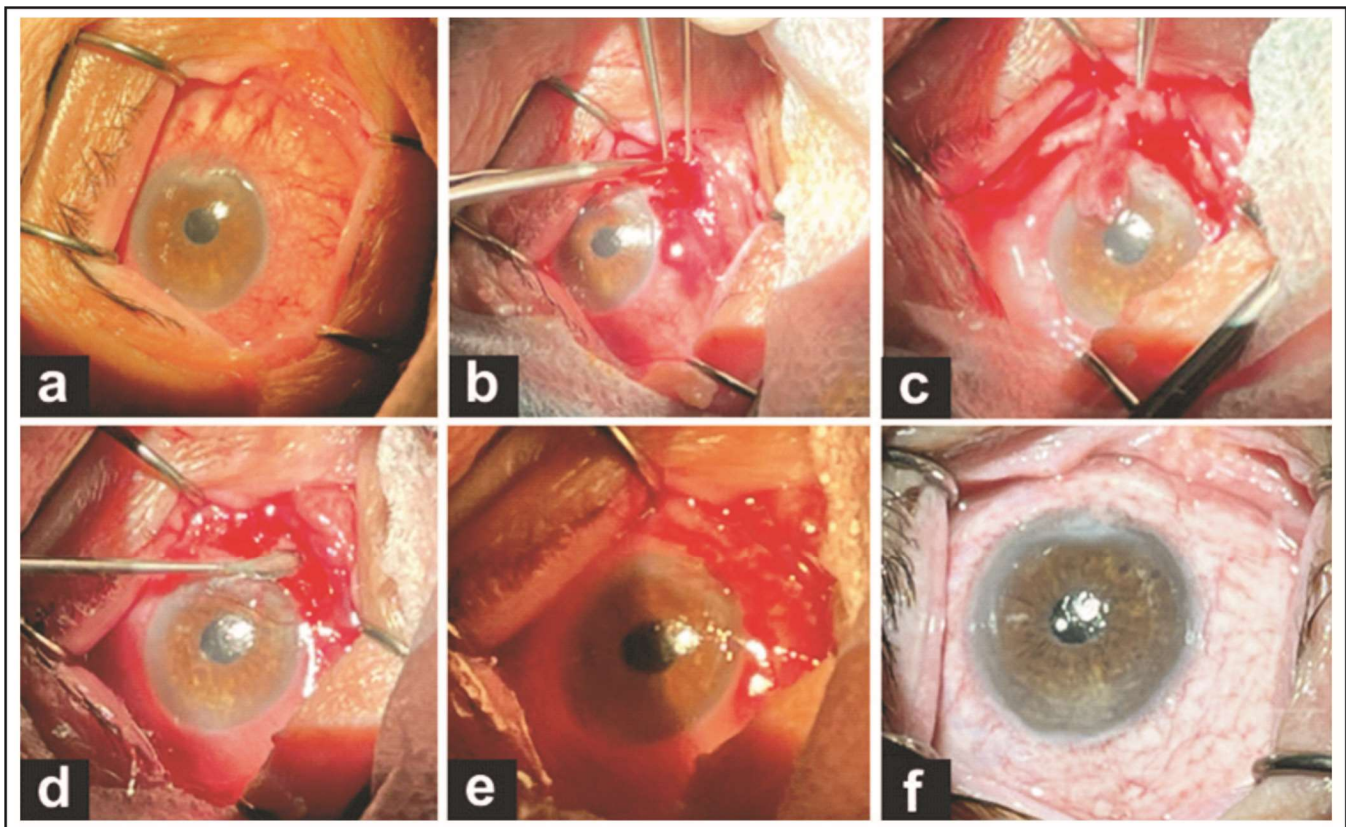
the sutures; sometimes time of suturing exceeds the actual excision of the graft.<sup>6</sup>

Thus, search for an optimal method of treating pterygium, one that minimizes risk of relapses and complications and ensures cosmetic safety, remains a subject of interest, controversy and discussion in modern ophthalmology.

In the present study, we performed removal of pterygium using rotational flap method with flap fixation using a biodegradable Diplén membrane.

### Case Presentation

A 78-year-old individual, was referred to the ophthalmology department in September 2022 for treatment of pterygium in right eye (Figure 1a). This case reporting is in accordance



**Figure 1:** (a) Pterygium in a 78-year-old patient. (b) Excision of the pterygium. (c) Prepared rotated conjunctival flap. (d) Modeling of a Diplén membrane by the size of the wound surface. The membrane is placed on the wound surface. (e) Suture less fixation of the flap on the adhesive surface of the membrane. (f) Observation 6 months after the last treatment session.

with the principles of Helsinki Declaration (revised in 2013). The study protocol was approved by the Local Ethics Committee. Prior to publishing this report and the accompanying images, we obtained written informed consent from the patient. A copy of the written consent is available for review by the editorial board of this journal upon request. The results were assessed at multiple time points: 1 – 2 weeks, 4 – 8 weeks, 12-16 weeks, and the final follow-up at 6 months.

The patient underwent regular examinations on the first day after surgery and at subsequent intervals of 1, 2, 4, 8, 12, 16 and 24 weeks (Figure 1f). During each visit, various assessments were conducted, including visual acuity testing, tonometry, and biomicroscopy using a slit lamp. The position and viability of the flap, as well as the condition of the surrounding conjunctiva, were evaluated at each visit.

Before and after the operation, a comprehensive ophthalmological examination was performed, which involved determining visual acuity, conducting a slit lamp examination, examining the fundus and performing pneumotometry. Biomicroscopy using slit lamp revealed a fleshy and vascularized pterygium extending from limbus to cornea on the nasal side of the patient's right eye, spanning from 6 to 10 clock hours. The growth did not obstruct the pupil area. The patient was admitted to hospital for planned excision of the pterygium with conjunctival plasty using a conjunctival flap in combination with an adhesive polymer membrane.

The operation was carried out following administration of sub-conjunctival anesthesia using 2% lidocaine solution. This was done to separate conjunctiva from fibrovascular tissue beneath it. Additionally, the same solution was injected subconjunctivally in the upper region to separate conjunctiva from tenon capsule, where a rotational flap was to be prepared. The pterygium was cut at the edge using Wescott scissors. Pterygium head was separated from surface of the cornea, and subconjunctival fibrous tissue was completely removed (Figure 1b). Any excessive pathological fibrous tissues on the corneal surface were eliminated using blade No. 15. A rotational flap was created through a vertical peritomy from the upper bulbar conjunctiva, positioned 12 hours in the upper arch. The conjunctiva was dissected toward the surgical wound. The flap was separated from the limb and upper arch, leaving a narrow leg only in the upper

nasal corner of the surgical wound (Figure 1c). The size of the rotational flap was made 30% larger than the recipient area. After the flap was positioned in its final location, the wound was thoroughly dried. The Diplene membrane was customized to match the shape and size of the rotated flap. The membrane was then applied to the exposed sclera, with the rotated flap placed on top of it (Figure 1d, e).

After 60 seconds, the stability of the flap was checked by gently pulling it with forceps. The eyelid retractors were removed and the eye was tightly patched with Dexa-Gentamicin ointment (URSAPHARM Arzneimittel, GmbH, Germany).

In the postoperative period, the patient was prescribed local eye drops "Tobradex" (Tobramycin and Dexamethasone, Alcon Laboratories Ltd, Fort Worth, Texas, USA) four times a day for 1 week.

On the first postoperative day, the patient experienced slight sensation of foreign body and during biomicroscopy with slit lamp, hyperemia was noted, the graft had the correct position.

## DISCUSSION

The most frequent indicator of successful pterygium surgery used in studies is the recurrence rate observed after 6 – 12 months. Since this study gives results in 6 months, more distant indicators have yet to be studied. When using a Diplene membrane, it should be taken into account that its resorption time was 7 days. This time is enough to create a strong connection between the conjunctival flap and the sclera.

Diplene membrane is a colorless or slightly opaque structure that consists of two combined layers - a hydrophilic layer and a hydrophobic layer.<sup>7</sup> It is soft and elastic and is manufactured with a length of  $100 \pm 5$  mm, a width of  $50 \pm 2.5$  mm, and a thickness of 10-30 mm. The membrane is hermetically packed in a plastic bag and sterilized by irradiation with a dose of 2.5 Mrad. It has a sorption capacity of 3-5g/g for water and blood. The degree of adhesion to intact skin is 23 N/m, with a tensile strength of at least 10 Kgf/cm<sup>2</sup> and an elongation at break of at least 150 Kgf. The membrane is vapor permeable (4.0 mg/cm<sup>2</sup>/hour) and micro-permeable. The main components of the membrane are water-soluble natural and synthetic polymers, copolymers, and their derivatives. Both membrane surfaces, the hydrophilic and hydrophobic layers, are tightly fused together as a single unit. There is no separation between the two layers. This is

achieved through the presence of a specific plasticizer. The hydrophilic surface of the membrane forms a strong bond with wet surfaces of organs and tissues, even those that are bleeding. The structure of the membrane consists of alternating layers of plasticizer molecules and water, creating a liquid crystal structure with monomolecular thickness.

Since long, search for an optimal method of treating pterygium, that minimizes risk of relapses and complications and ensures cosmetic safety, has remained a subject of interest, controversy and discussion. In 2010, Virendra K Malik, Sandeep Kumar reported a technique to assess whether the use of fibrin glue instead of sutures reduced repeatability of treatment of pterygium recurrence using conjunctival autograft (CAG). It was noted that the operation time was significantly reduced and postoperative inflammation and complications were less in the group where the seamless fixation technique was used.<sup>8</sup> Ezan A Kothari, et al, described the results of pterygium restoration using a self-adhesive amniotic membrane that did not require glue or sutures for fixation.<sup>9</sup> It was found that the effectiveness of using self-adhesive amniotic membranes is not inferior to the more widely used methods of excision of pterygium, namely the use of amniotic membranes and conjunctival autograft with glue or sutures. However, the self-adhesive grafts are associated with substantially more pyogenic granuloma formation.<sup>9</sup> Nganga Ngabou et al, described pterygium surgery by conjunctival autograft with autologous blood fixation.<sup>10</sup> Pterygium surgery, during which a conjunctival graft was fixed with autologous blood proved a safe method, the results of which were equal to other methods of pterygium surgery using a conjunctival autograft. This technique has the advantage of less irritation, no risk of transmitting infection and lower cost. In our case report, use of a Diplen adhesive membrane is a promising method in pterygium surgery. In this study, fixation of rotational flap resulted in excellent postoperative results.

## CONCLUSION

The seamless fixation of the conjunctival flap with Diplen membrane seems to be a safe, effective and reliable method for treating pterygium. During the 6 months of follow-up, we did not observe any of following complications: displacement of the conjunctival flap, necrosis at the site or development

of granuloma. We recommend long-term follow-up for 1 year.

**Conflict of Interest:** Authors declared no conflict of interest.

## REFERENCES

1. **Ozsutcu M, Ayintap E, Akkan JCU, Koytak A, Cengiz A.** Repeated bevacizumab injections versus mitomycin C in rotational conjunctival flap for prevention of pterygium recurrence. *Indian J Ophthalmology*, 2014;**62(4)**:407-411. Doi: 10.4103/0301-4738.120220.
2. **Malozhen SA, Trufanov SV, Krakhmaleva DA.** Pterygium: etiology, pathogenesis, treatment. *Vestn Oftalmol.* 2017;**133(5)**:76-83. [Article in Russian] Doi: 10.17116/oftalma2017133576-83.
3. **Benyamini OG, Barkana Y, Hartstein M, Attas L, Avni I, Zadok D.** Biological Glue in Pterygium Surgery With a Rotational Flap or Sliding Flaps. *Cornea*. 2008;**27(8)**:911–915. Doi: 10.1097/ico.0b013e318167810f.
4. **Chu WK, Choi HL, Bhat AK, Jhanji V.** Pterygium: new insights. *Eye (Lond)*. 2020;**34(6)**:1047-1050. Doi: 10.1038/s41433-020-0786-3.
5. **Akbari M.** Update on overview of pterygium and its surgical management. *J Popul Ther Clin Pharmacol*. 2022;**29(4)**:30-45. Doi:10.47750/jptcp.2022.968.
6. **Kim DJ, Lee JK, Chuck RS, Park CY.** Low recurrence rate of anchored conjunctival rotation flap technique in pterygium surgery. *BMC Ophthalmol*. 2017;**17(1)**:187. Doi: 10.1186/s12886-017-0587-z.
7. **Abakarova DS.** [Two-layer adhesive film Diplen-denta C--a new compound containing polymer base and active component Solcoseryl]. *Stomatologija (Mosk)*. 2007;**86(1)**:70-71. Russian. PMID: 17495814.
8. **Malik VK, Kumar S.** Use of fibrin glue in the management of recurrent pterygium by conjunctival autograft. *Saudi Med J*. 2010;**31(12)**:1326-1330. PMID: 21135995.
9. **Kothari EA, Tenewitz JE, Jayman JR, Cartwright MJ.** Pilot study of a glue-less, suture-less amniotic membrane for pterygium excision. *Int Ophthalmol*. 2022;**42(9)**:2933-2938. Doi: 10.1007/s10792-022-02281-x.
10. **Nganga Ngabou CGF, Makita C, Ndalla SS, Nkokolo F, Ambia Koulimaya RM, Diatewa B.** Chirurgie du ptérygion avec greffe de conjonctive fixée par du sang autologue [Pterygium surgery by conjunctiva autograft with autologous blood fixation]. *J Fr Ophtalmol*. 2018;**41(5)**:425-432. Doi: 10.1016/j.jfo.2017.10.007.

### **Authors' Designation and Contribution**

Maria Cervatiuc; MD, PhD-student: *Concepts, Design, Literature Search, Data Acquisition, Data Analysis, Manuscript Preparation, Manuscript Editing, Manuscript Review.*

Anait B. Azibekyan; MD, Candidate of Medical Sciences (Equivalent -PhD): *Concepts, Design, Literature search, Data acquisition, Data analysis, Manuscript preparation, Manuscript editing, Manuscript review.*

Eldor Jonnazarov; MD, PhD-student: *Concepts, Design, Literature Search, Data Acquisition, Data Analysis, Manuscript Preparation, Manuscript Editing, Manuscript Review.*

Nodirbek U. Dzhapiev; Ophthalmology Residency Program Student: *Concepts Design, Literature Search, Data Acquisition, Data Analysis.*

Bashirxon A. Tursunov; Assistant Professor Student: *Concepts, Design, Literature Search, Data Acquisition, Data Analysis.*

