

# Clinical and Neuro-imaging Patterns of Meningiomas of Visual Pathway

Tayyaba Gul Malik, Khalid Farooq, Muhammad Khalil

*Pak J Ophthalmol 2015, Vol. 31 No. 2*

See end of article for authors affiliations

**Purpose:** To highlight the clinical and neuro-imaging patterns of Meningiomas of visual pathway.

Correspondence to:  
Dr. Tayyaba Gul Malik  
Ophthalmology Department  
Lahore Medical and Dental  
College Lahore  
E.mail: tayyabam@yahoo.com

**Materials and Methods:** It was a descriptive retrospective study conducted during 2007 to 2013. 94 patients with intra cranial Meningiomas affecting the visual pathway were selected for study. Clinical data included history, ocular and systemic examinations and neuro-imaging reports. Special attention was given to the neurological data, which was the only source available to us for diagnosing Meningiomas. Histological confirmation of Meningioma was available in 9.6% cases (n = 9).

**Results:** Ninety – four patients, 51 females and 43 males (female: male ratio, 1.19:1) were included in the study. Mean age was 48.23 years. The commonest type of Meningioma affecting visual pathway was Meningioma of inner table of occipital bone causing mass effects on the occipital lobe (30.85%, n = 29). Other Meningiomas were Parasellar (21.3%, n = 20) and supra sellar Meningiomas (18.1%, n = 17) pressing upon optic chiasma. Tumor size ranged from 0.7 cm to 8.5 cm in smallest and largest dimensions respectively. Only one patient in our series had neurofibromatosis type 1 and one patient had neurofibromatosis type 2.

**Conclusion:** Neuro-imaging including conventional radiology plays a pivotal role in non-interventional diagnosis of intracranial Meningiomas. Owing to the benign nature of Meningioma, it should be differentiated from other aggressive tumors which need to be diagnosed and treated at the earliest.

**Key words:** Parasellar Meningiomas, Supra sellar Meningiomas, visual pathway, Dural tail sign, Neuro-imaging

The term, "Meningioma" was first coined by Harvey Cushing<sup>1</sup>. Generally, Meningiomas are tumors, which arise from arachnoidal cap cells, commonly occurring on the brain surface. Rarely, they are seen in the brain ventricles. They are either solitary or multiple. Many cases of Meningiomas are diagnosed incidentally. Tumors less than 2.5 cm are usually symptomless. Whereas, larger tumors show symptoms which worsen with time.<sup>2</sup>

These tumors produce symptoms by different mechanisms. Firstly, by irritating the brain substance (leading to epilepsy), by pressing the underlying brain tissue or cranial nerves (optic nerve Meningioma),

causing hyperostosis (Meningioma of greater wing of sphenoid), by invading the soft tissues (rarely) and finally by vascular compression or invasion (invasion of cavernous sinus by Meningioma).<sup>3,4</sup>

This article reappraises the neuro-imaging patterns of Meningiomas of visual pathway.

## MATERIAL AND METHODS

It was a descriptive retrospective study. We reviewed clinical and imaging charts of 506 patients of Meningioma. 94 patients who had Meningiomas affecting the visual pathway were selected for study.

Clinical data included history, visual acuity, color vision, pupillary reactions, extra ocular movements, intra ocular pressures, field of vision, slit lamp examination and fundoscopy.

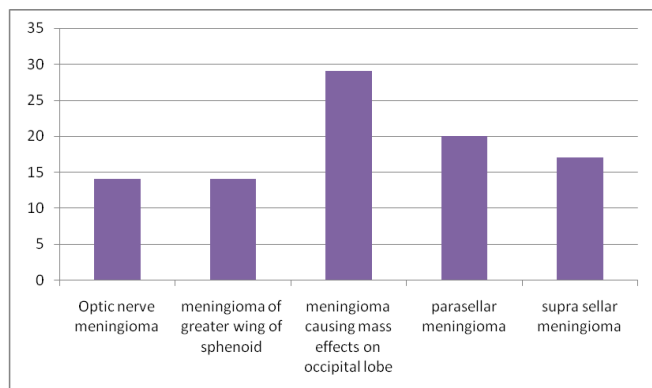
Neuro-imaging with both plain and post contrast images were studied. Gd - DTPA was utilized for post contrast component. Data was compiled, results deduced and descriptive statistical analysis was done.

**RESULTS**

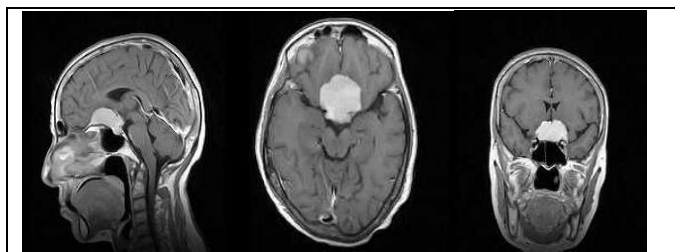
Ninety four patients, 51 females and 43 males (female: ratio, 1.19:1) were included in the study. Age ranged from 12 years to 96 years (mean 48.23 years). 33 patients were ≤ 40 years and 61 patients were more than 40 years of age.

The commonest type of Meningioma affecting visual pathway was Meningiomas of inner table of occipital bone causing mass effects on the occipital lobe (30.85%, n = 29). Refer to Table 1. Second common were Parasellar (21.3%, n = 20) and supra sellar Meningiomas (18.1%, n = 17) pressing upon optic chiasma (Fig. 1 and 2). Tumor size ranged from 0.7 cm to 8.5 cm in smallest and largest dimensions respectively. There were 9 patients with multiple Meningiomas (9.6%). Among these, there was an interesting patient with two well-defined Meningiomas. One in the middle cranial fossa and the other in left parietal region. Middle cranial fossa mass was encasing the cavernous sinus and Internal Carotid artery and causing pressure effects on right optic nerve, optic tract, Pons and midbrain. Patient had right lateral rectus palsy and visual field defects in both eyes (Fig. 3).

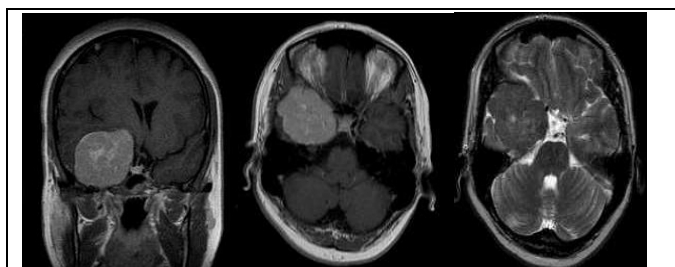
Only one patient in our series had neurofibromatosis type 1 and one patient had neurofibromatosis



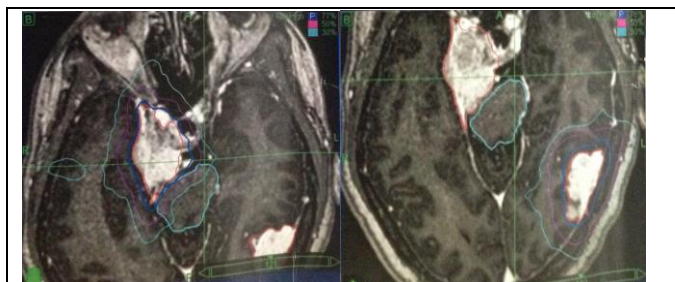
**Table 1:** Different types of Meningiomas affecting visual pathway.



**Fig. 1:** Solid enhancing planum sphenoidale meningioma. Mass effect on pituitary stalk and optic nerve / optic chiasm.



**Fig. 2:** Right para sellar meningioma T<sub>1</sub>, T<sub>2</sub> and coronal / axial post contrast images showing significant mass effect on right cavernous sinus, pituitary stalk and optic chiasm.



**Fig. 3:** Two well defined Meningiomas in the middle cranial fossa and left parietal region. Middle cranial fossa mass is encasing the cavernous sinus and Internal Carotid artery and causing pressure effects on right optic nerve, optic tract, pons and midbrain.

type 2. The diagnosis of Meningioma was purely based on radiological findings. Histological confirmation of Meningioma was available in 9.6% cases (n=9).

Cavernous sinus Meningiomas are associated with multiple cranial nerve palsies including Oculomotor, Trochlear, Trigeminal and Abducent. We did not have any patient with purely cavernous sinus Meningiomas but there were patients with large Parasellar

Meningiomas (21.27%, n = 20), which were causing mass effects on the cavernous sinus laterally and on optic chiasma medially. Meningiomas which cause pressure effects on the occipital lobe result in contra lateral hemianopia (30.1%, n = 29 in our series). There were 14.9% patients with Meningiomas of optic nerve causing ipsilateral vision loss, Proptosis, optic atrophy and opticociliary shunt vessels. Similarly 14.9% cases in our series had Meningiomas of the greater wing of sphenoid with multiple cranial nerve palsies.

Ocular associations of these Meningiomas were visual field defects, Proptosis, optic disc edema, optic atrophy, ocular motor nerve palsies and pupillary defects. Other neurological deficits were hearing defect, hemiplegia, trigeminal neuralgia and epilepsy.

## DISCUSSION

Meningiomas are slow growing tumors, which are sometimes, diagnosed incidentally (2 - 3%). It is the second most common intracranial tumor in adults (constituting 20% of all intracranial tumors).<sup>5</sup> World Health Organization (WHO) has defined Meningiomas as "meningothelial (arachnoid) cell neoplasms, typically attached to the inner surface of the Dura mater."<sup>6</sup> It is more common in females and reach a peak incidence in seventh decade of life<sup>7</sup>. In this particular study, female to male ratio was 1.19:1. Previous studies in Caucasians had shown a ratio of 3:1. In Africans, the gender ratio was same. Another study depicted this ratio to be 24:1, which is very high.<sup>8</sup>

Mean age in this study was 48.23. In a similar case series, mean age in adults was 50 years.<sup>9</sup> Tumors that arise from sphenoid bone and result in visual complaints usually present in 5<sup>th</sup> to 6<sup>th</sup> decade.<sup>7</sup>

Another characteristic feature of this tumor is that it causes symptoms by compressing the underlying structures without invading brain tissue. Symptoms depend on the site of tumor. Meningiomas in the region of olfactory groove cause anosmia, ipsilateral optic atrophy and contra lateral papilledema. The triad is called Foster Kennedy syndrome. In this particular study, we did not encounter any patient with Foster Kennedy syndrome. Cavernous sinus Meningiomas are associated with multiple cranial nerve palsies including Oculomotor, Trochlear, Trigeminal and Abducent. We did not have any patient with purely cavernous sinus Meningiomas but there were patients with large Parasellar Meningiomas (21.27%, n = 20), which were causing mass effects on

the cavernous sinus laterally and on optic chiasma medially. Meningiomas which cause pressure effects on the occipital lobe result in contra lateral hemianopia (30.1%, n = 29 in our series). Meningiomas of optic nerve cause ipsilateral vision loss, Proptosis, optic atrophy and opticociliary shunt vessels (14.9% in this study). Meningiomas of the greater wing of sphenoid cause multiple cranial nerve palsies if superior orbital fissure is involved (14.9% in this study).

Many causative agents for Meningiomas are being investigated. Viruses, trauma, up-regulation of COX2 and high dose cranial irradiation are some agents.<sup>10</sup> Some investigators have proposed a relation of female hormones with Meningiomas. Similarly, estrogen, progesterone and androgen receptors were found on some Meningiomas, which further strengthened the hypothesis but it is still not proved. Increase in the tumor size in pregnancy also throws light on the role of hormones.<sup>11</sup>

Meningiomas rarely occur in children 17 but when they do, they are more common in males<sup>12</sup>. In our study, there were only four patients of Meningiomas less than 15 years of age and all of them were males.

Radiation induced Meningiomas are multiple, aggressive and have a high proliferation rate.<sup>13</sup> They appear 20 to 35 years after irradiation to brain tumors regardless of the dose of radiation<sup>14</sup>. None of our patients had history of radiation. Excessive use of cellular phones is also blamed but available data do not confirm this.<sup>15</sup>

Small Meningiomas are usually incidental findings on neuro-imaging performed for some other disease. Hence, surgical excision and biopsy is not required in all cases. Diagnosis depends on the imaging studies. Even the role of plain radiographs should not be overlooked. We can analyze hyperostosis, calcifications and increased vascular markings of the skull. On plain CT scans, Meningiomas are iso-attenuating to hyper-attenuating. Injection of Iodinated contrast material leads to homogenous and intense enhancement of the tumor. MR scans with contrast are very helpful in radiological diagnosis of Meningiomas. After injecting Gadolinium gadopentate, these tumors enhance homogeneously and intensely. Another important radiologic diagnostic feature of Meningiomas is dural tail sign. Goldsher et al described Dural tails as a "highly specific feature of meningiomas".<sup>16</sup> The Dural tails are composed of hyper vascular, presumably reactive tissue, but not

Meningioma tumor cells. Peritumoral edema is also associated with Meningiomas which is well demonstrated on FLAIR images. Research is being going on regarding the role of VEGF-A in inducing this edema. Jack Hou et al have shown that VEGF-A is secreted by Meningioma cells.<sup>17</sup>

Meningiomas of the optic nerve have a typical “bull’s eye” picture in coronal images of MRI. There is surrounding mass of tumor tissue around an attenuated optic nerve. In axial images, the tumor takes an appearance of “tram track”.<sup>18</sup> This is in contrast to optic nerve Gliomas in which nerve itself is increased in diameter. Optic nerve sheath Meningiomas are either primary or secondary depending on whether they are primary arising from optic nerve sheath or invading the orbit from cranial cavity respectively.

## CONCLUSION

Neuro-imaging including conventional radiology plays a pivotal role in non-interventional diagnosis of intracranial Meningiomas. Owing to the benign nature of Meningiomas, it should be differentiated from other aggressive tumors which need to be diagnosed and treated at the earliest.

### Author’s Affiliation

Dr. Tayyaba Gul Malik  
Associate Professor of Ophthalmology  
Lahore Medical and Dental College  
Lahore

Dr. Khalid Farooq  
Professor, Department of Radiology  
Lahore Medical and Dental College  
Lahore

Dr. Muhammad Khalil  
Associate Professor of Ophthalmology  
Lahore Medical and Dental College  
Lahore

## REFERENCES

1. **Cushing H, Eisenhardt L, Thomas C, ed.** Meningiomas: Their Classification, Regional Behaviour, Life History, and Surgical End Results. Springfield, Ill: Charles C Thomas; 1938.
2. **Sughrue ME, Rutkowski MJ, Aranda D, Barani IJ, McDermott MW, Parsa AT.** Treatment decision making based on the published natural history and growth rate of small Meningiomas. *J Neurosurg.* 2010; 113: 1036-42.
3. **Pieper DR, Al-Mefty O, Hanada Y, Buechner D.** Hyperostosis associated with Meningiomas of the cranial base: secondary changes or tumor invasion. *Neurosurgery.* 1999; 44: 742-6.
4. **Pieper DR, Al-Mefty O, Hanada Y, Buechner D.** Hyperostosis associated with Meningiomas of the cranial base: secondary changes or tumor invasion. *Clin Radiol.* 2013; 68: 837-44.
5. **Claus EB, Bondy ML, Schildkraut JM, Wiemels JL, Wrensch M, Black PM:** Epidemiology of intracranial meningioma. *Neurosurgery,* 2005; 57: 1088-95.
6. **Perry A, Louis DN, Scheithauer BW, Budka H, von Deiming A.** Louis DN, Ohgaki Hiroko, Wiestler OD, and Cavenee WK. Meningiomas in WHO Classification of Tumours of the Central Nervous System. Lyon, France: International Agency for Research on Cancer, 2007: 164-72.
7. Roy and Fraunfelder’s Meningioma. In: current ocular therapy. Saunders Elsevier. 6<sup>th</sup> edition, 2008. Page 255.
8. **Yang J, Ma SC, Liu YH, Wei L, Zhang CY, Qi JF, et al.** Large and giant medial sphenoid wing Meningiomas involving vascular structures: clinical features and management experience in 53 patients. *Chin Med J (Engl).* 2013; 126: 4470-6.
9. **Sheikh BY, Siqueira E, Dayel F.** Meningioma in children: a report of nine cases and a review of the literature. *Surg Neurol.* 1996; 45: 328-35.
10. **Ragel BT, Jensen RL, Couldwell WT.** Inflammatory response and meningioma tumorigenesis and the effect of cyclooxygenase-2 inhibitors. *Neurosurg Focus,* 2007; 23: E7.
11. **Baxter DS, Smith P, Stewart K, Murphy M.** Clear cell Meningiomas presenting as rapidly deteriorating visual field and acuity during pregnancy. *J Clin Neurosci.* 2009; 16: 1502-4.
12. **Menon G, Nair S, Sudhir J, Rao BR, Mathew A, Bahuleyan B.** Childhood and adolescent meningiomas: a report of 38 cases and a review of literature. *Acta Neurochir (Wien),* 2009; 151: 239-44.
13. **Claus EB, Calvocoressi L, Bondy ML, et al.** Dental X-rays and risk of Meningiomas. *Cancer,* 2012; 118: 4530-7.
14. **Perry A, Louis D, Scheithauer B, et al.** Meningiomas. Louis B, Ohgaki H, Wiestler O, Cavenee W, editors., 4th ed. Lyon, France: IARC Press; 2007.
15. **Milham S.** Meningioma and mobile phone use. *Int J Epidemiol.* 2010; 39: 1117.
16. **Goldsher D, Litt AW, Pinto RS, Bannon KR, Kricheff II.** Dural “tail” associated with Meningiomas on Gd-DTPA - enhanced MR images: characteristics, differential diagnostic value, and possible implications for treatment. *Radiology,* 1990; 176: 447-50.
17. **Hou J, Kshetry VR, Selman WR, Nicholas C.** Bambakidis, M.D. *Neurosurg Focus,* 2013: 35.
18. **Zimmerman RD, Seidenwurm DJ, Davis PC, Brunberg JA, De La Paz RL, Dormont PD, et al.** Orbits, vision, and visual loss. [Online Publication]. Reston (VA): American College of Radiology (ACR); 2006.