

Familial Exudative Vitreoretinopathy: A Case Report



Mashal Tayyab¹, Kashif Iqbal², Awaid Abid³
¹⁻²Layton Rahmatulla Benevolent Trust (LRBT), Lahore, ³Mughal
Eye Hospital, Lahore

ABSTRACT

Familial Exudative Vitreoretinopathy (FEVR), also known as Chriswick Schepens Syndrome is an inherited condition characterized by failure of vascularization of retinal periphery. This results in variable clinical manifestations such as telangiectasia, hemorrhage, exudation, retinal traction and detachment. Presented herein is a case of a 14 year old female who exhibits decrease of vision in right eye since 6 months. Examination shows dragging of disc with tractional band at macula and telangiectatic vessels in temporal retinal periphery. Based on detailed history, clinical examination and investigations, a diagnosis of FEVR is made.

Key Words: Familial Exudative Vitreoretinopathy, Retinopathy of Prematurity, Retinal telangiectasia.

How to Cite this Article: Tayyab M, Iqbal K, Abid Awaid. Familial Exudative Vitreoretinopathy: A Case Report. 2024;40(2):216-219. Doi: [10.36351/pjo.v40i2.1527](https://doi.org/10.36351/pjo.v40i2.1527)

*Correspondence: Mashal Tayyab
Layton Rahmatulla Benevolent Trust (LRBT), Lahore
Email: mashal_tayyab@yahoo.com*

*Received: October 25, 2022
Accepted: February 20, 2024*

INTRODUCTION

FEVR is a rare genetic disease characterized by abrupt cessation of peripheral retinal vessels at the equator (more marked temporally) and vitreous bands in the periphery.¹ This condition was first described in 1969 by Criswick and Schepens and it is one of the several pediatric vitreo retinopathies that result from congenital abnormalities in retinal vascular development.²

The resulting retinal ischemia causes vascular endothelial growth factor production which may result in peripheral neovascularization, vitreous hemorrhage, retinal traction with temporal dragging, macular dragging, falciform retinal fold and retinal detachment. The disease shows strong genetic and hereditary etiology. Inheritance is AD and rarely XLR or AR, with high penetrance and variable expressivity.³ The incidence of FEVR is reported to be 0.11% (219 out of 199851) in a multicenter study.⁴ Owing to its rare prevalence, we present a case of FEVR diagnosed in a 14 years old girl from Lahore, Pakistan.

CASE PRESENTATION

A 14-year old girl from Arif Wala, presented to outpatient department, Layton Rahmatullah Benevolent Trust hospital, Township, Lahore with complaint of watering and blurred vision in the right eye for 6 months. The visual complaint was gradual in onset and accompanied by intermittent, mild pain (non-radiating in nature and not associated with nausea or any aura). There was watering on focusing at some object. The left eye had no perception to light since childhood. History of surgical or medical intervention, trauma or glasses was negative. Past medical and surgical history was unremarkable.

The patient was born at home in village via normal delivery. Her birth weight was normal and there was no known subsequent post-natal hospital admissions or oxygen therapy. Vaccination history was also negative. Systemic, drug and family history were also unremarkable.

On examination, best corrected visual acuity in the right eye was 6/36 with spherical correction of -2.00 DS. Intraocular pressure was 19mmHg. Extraocular movements were full. Pupil was round, regular and reactive with no Marcus Gunn. Lids, lashes and adnexa were unremarkable. Cornea was clear and aspheric. Anterior chamber was quiet and natural lens was clear with no other abnormalities in the anterior segment. Vitreous cavity showed cells of +1.

Fundoscopy revealed a fibrous band temporal to macula causing tractional pucker at fovea and dragging the temporal disc margin(Figure 1). There was straightening of vessels at the macula. Cup to disc ratio could not be ascertained because of abnormal disc configuration. Temporal periphery of retina showed abrupt cessation of temporal retinal vasculature and abnormal telangiectatic vessels (Fig 2). Superior, inferior and nasal retinal peripheries were unremarkable. Left eye was pthisical.

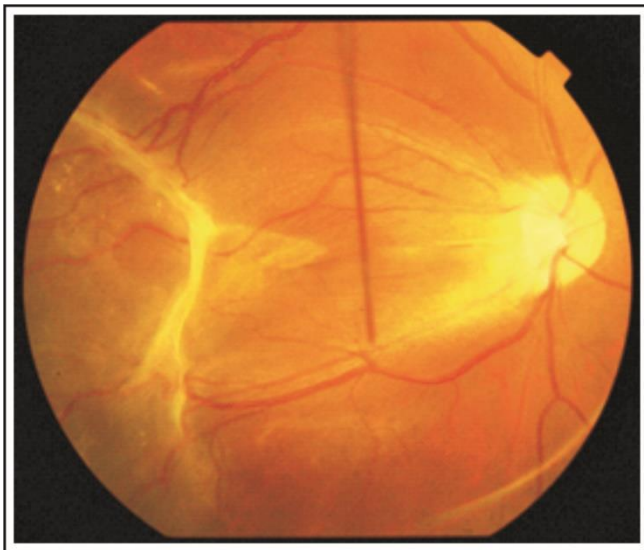


Figure 1: Right fundus photograph showing dragging of temporal disc margin, straightening of macular vessels and fibrous band.

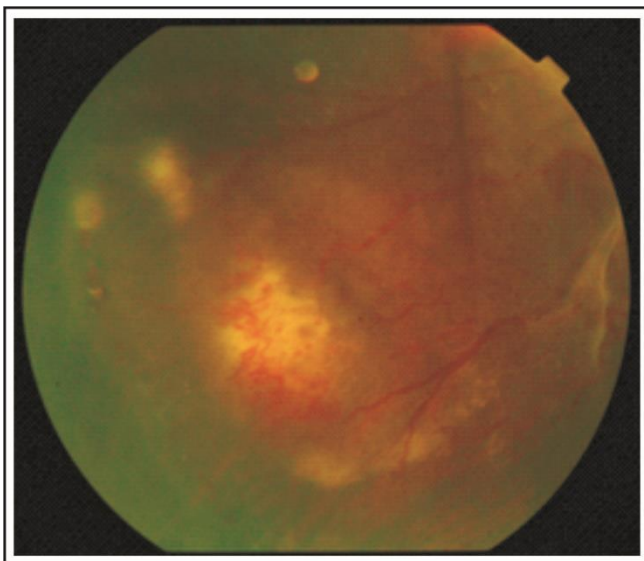


Figure 2: Fundus photograph of telangiectatic vessels.

B-scan ultrasound of the right eye showed tractional band in the vitreous with irregular retinal surface but no retinal elevation(Figure3).

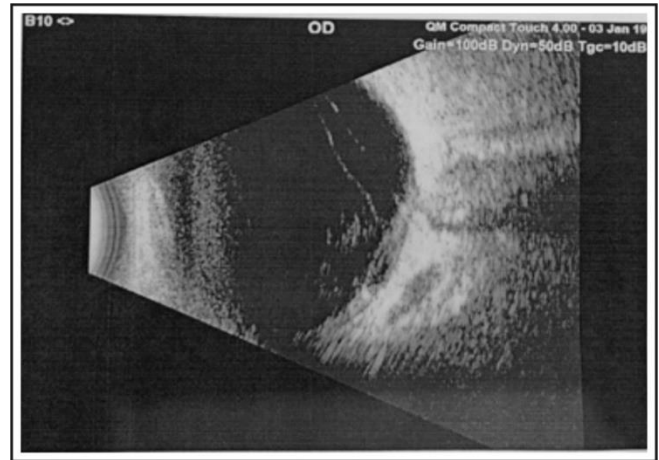


Fig 3: B-Scan Ultrasound of right eye showing tractional band in vitreous.

B-scan ultrasound of the left eye showed homogenous vitreous echogenicities with calcified foci in the posterior eye wall pointing to a pthisical eye.

Fundus fluorescein angiography showed dropout in the temporal periphery with leakage from the abnormal vessels (Figure4 and 5).

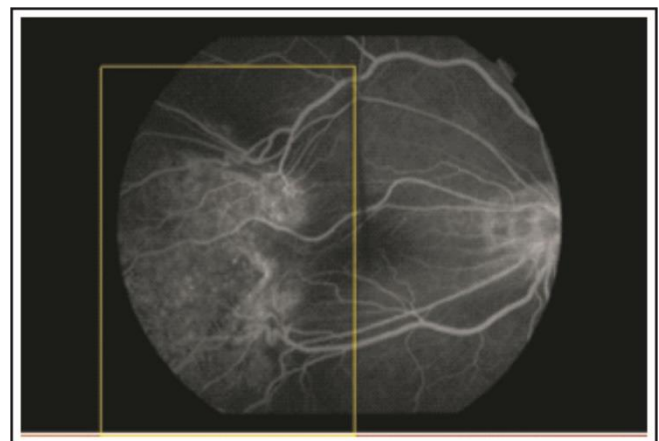


Figure 4: Telangiectatic vessels showing leakage on FFA with areas of dropout in temporal periphery.

Differential diagnoses were; FEVR, Retinopathy of prematurity (ROP), Persistent fetal vasculature, Coat's Disease and Pars planitis. Based on history and clinical findings and investigations, a working diagnosis of familial exudative vitreoretinopathy

(Stage 2 disease) was made. Patient was administered an injection of anti-vascular endothelial growth factor and prophylactic peripheral laser to the area of dropout. She is currently on regular 3-monthly follow-up and her vision remains stable.

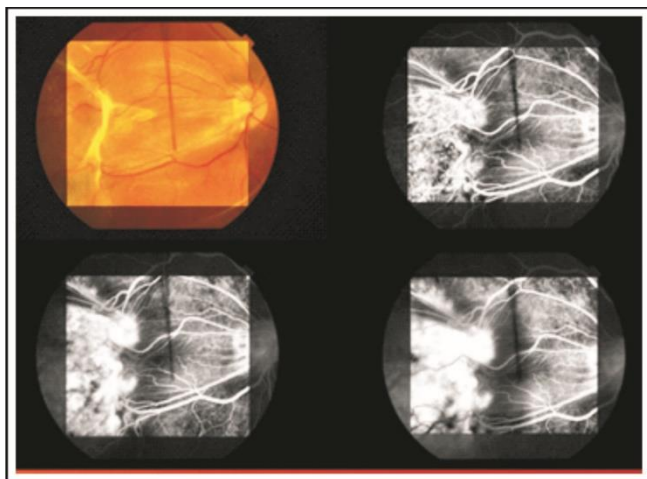


Figure 5: Four-up of Fundus Fluorescein Angiogram.

DISCUSSION

FEVR is an inherited vitreoretinal disorder characterized by incomplete or anomalous vascularization of the peripheral retina. It is phenotypically variable and at times it is an incidental diagnosis or may present with complete loss of vision.⁵

FEVR has different inheritance patterns depending on the gene involved. Inheritance is Autosomal Dominant and rarely XLR or AR, with high penetrance and variable expressivity.⁴ Most individuals have the autosomal dominant form of this condition, caused by genetic changes in the FZD4 or LRP5 gene.⁶ Wai et al, have described a South East Asian family with ten patients (20 eyes) of FEVR.⁷ Owing to its hereditary nature, genetic testing can be done to facilitate counselling against consanguineous marriage.

Age of presentation also varies and according to one study, mean age at presentation was 6 years (range of <1 month to 49 years).⁸ Major signs are similar to retinopathy of prematurity and include large angle kappa, retinal detachment, stretched posterior retinal vessels, dragged optic disc, and retinal folds. These ocular anomalies are followed by complications, such as retinal neovascularization and exudates, retinal and venous bleeding, vitreoretinal traction macular ectopia

and cataract. Staging of the disease based on fundus examination is as follows:⁴

Stage 1: Peripheral avascularity at temporal equator. Vitreous degeneration with areas of White without pressure and vascular straightening.

Stage 2: Peripheral vascular telangiectasia progresses to pre-retinal fibrovascular proliferation.

Stage 3: Macular Sparringtractional or rhegmatogenous retinal detachment.

Stages 4 and 5 are macula involving and total retinal detachment respectively.

Gold standard for diagnosis is widefield fluorescein angiography.⁶ This also helps in determining the exact area of ischemia (corresponding to the areas of dropout), so that laser therapy can be better targeted as was seen and done in our patient. Treatment is primarily laser therapy to the avascular retina to prevent complications of ischemic retina. Intravitreal bevacizumab has also shown regression of neovascularization with improvement in visual acuity.⁹ Surgical Treatment is usually done for patients with retinal detachment. A study shows a 62.5% attachment rate in selected cases of FEVR.¹⁰ Our patient had favorable outcome after anti-VEGF injection and is doing quite well until now.

CONCLUSION

FEVR is an uncommon condition that is often under diagnosed. Early Diagnosis, comprehensive history taking and fundus fluorescein angiography and treatment is crucial for optimal visual results.

Conflict of Interest: Authors declared no conflict of interest.

REFERENCES

1. **Gilmour DF.** Familial exudative vitreoretinopathy and related retinopathies. *Eye (Lond)*. 2015 Jan;**29(1)**:1-14. Doi: 10.1038/eye.2014.70.
2. **Tauqeer Z, Yonekawa Y.** Familial Exudative Vitreoretinopathy: Pathophysiology, Diagnosis, and Management. *Asia Pac J Ophthalmol (Phila)*. 2018;**7(3)**:176-182. Doi: 10.22608/APO.201855.
3. **Kondo H.** Complex genetics of familial exudative vitreoretinopathy and related pediatric retinal detachments. *Taiwan J Ophthalmol*. 2015;**5(2)**:56-62. Doi: 10.1016/j.tjo.2015.04.002.

4. **Liu D, Zheng J, Lu Y.** Fundus Examination of 23,861 Newborns by Digital Imaging in Ningbo. *J Ophthalmol.* 2021;**2021**:6620412. Doi: 10.1155/2021/6620412.
5. **Jiang Z, Wang P.** Novel Exon 7 Deletions in *TSPAN12* in a Three-Generation FEVR Family: A Case Report and Literature Review. *Genes (Basel).* 2023;**14**(3):587. Doi: 10.3390/genes14030587.
6. **Chen C, Sun L, Li S, Huang L, Zhang T, Wang Z, et al.** The spectrum of genetic mutations in patients with asymptomatic mild familial exudative vitreoretinopathy. *Exp Eye Res.* 2020;**192**:107941. Doi: 10.1016/j.exer.2020.107941
7. **Wai YZ, Chong YY, Lim LT.** Familial exudative vitreoretinopathy in a 4 generations family of South-East Asian Descendent with FZD4 mutation (c.1501_1502del). *Int J Retin Vitre.* 2022;**30**(8): Doi: 10.1186/s40942-022-00384-2
8. **Tushar M. Ranchod LYHKAD.** Clinical Presentation of Familial Exudative Vitreoretinopathy. *Ophthalmology.* 2011;**118**(10):2070-2075. Doi: 10.1016/j.ophtha.2011.06.020.
9. **Christopher R. Henry RASJHTea.** Long-term follow-up of intravitreal bevacizumab for the treatment of pediatric retinal and choroidal diseases. *J Am Assoc Pediatric Ophthalmol Strabismus.* 2015;**19**(6):541-548. Doi: 10.1016/j.jaapos.2015.09.006.
10. **Scott D, Pendergast MTT.** Familial Exudative Vitreoretinopathy, Results of Surgical Management. *Ophthalmology.* 1998;**105**(6):1015-1023. Doi:10.1016/S0161-6420(98)96002-X

Authors Designation and Contribution

Mashal Tayyab; Consultant Ophthalmologist:
Concepts, Design, Data acquisition, Data analysis, Manuscript preparation.

Kashif Iqbal; Consultant Ophthalmologist:
Manuscript review.

Awaid Abid; Consultant Ophthalmologist:
Literature search, Manuscript review.

