

Ocular Manifestations Associated with Head Injury

Kanwal Zareen Abbasi, Baseerat Qadeer, Ali Raza

Pak J Ophthalmol 2016, Vol. 32 No. 2

See end of article for authors affiliations

Correspondence to:
Kanwal Zareen Abbasi
Senior Registrar
Ophthalmology Department
Benazir Bhutto Hospital
Rawalpindi

Email: dr_maninoor_abbasi@yahoo.com

Received: January 26, 2016
Accepted: May 13, 2016

Purpose: To evaluate the pattern of ocular manifestations in patients of head injury.

Study Design: Prospective Cross sectional study.

Place and Duration of Study: Study was carried out at District Headquarter Hospital, Rawalpindi, from 1ST January 2013 to 30th June 2013.

Material and Methods: 152 patients, diagnosed with head injury along with ocular manifestations were included in this study. These head injured patients with ocular morbidity were analyzed for age, sex, cause of injury and types of ocular and head injuries. To evaluate these parameters, detailed history was taken followed by detailed anterior and posterior segment slit lamp examination, checking of extra ocular movements and optic nerve functions. Diagnostic investigations carried out included computed tomography scanning/ magnetic resonance imaging of brain and orbit, gonioscopy, diplopia charting, and measurement of intraocular pressure.

Results: Among 152 patients, 108 were males and 44 were females. Causes of head injury were traffic accidents 56.5%, fall from height 25.0%, assault 13.8%, and gunshot 4.6%. Maximum head and ocular injuries were in age group of 11-20 years. Most frequent soft tissue injury was periorbital echymosis (85 patients). Most frequent neuro-ophthalmic manifestation was abducent nerve palsy (12 patients). Orbital fracture with ruptured globe was encountered in 2 patients.

Conclusion: Injury to the globe, adenexae and ocular cranial nerve palsies constitute the most common oculo-visual complications following head injury.

Keywords: Ocular, visual, complications, head injury.

Head injuries are frequently associated with ophthalmic manifestations and consequent morbidity¹. Head injuries cause the hospitalization of 200 – 300 persons per 100,000 populations per year, and about 25% of these are associated with ocular and visual defects². The role of ocular injuries secondary to head trauma in the causation of blindness has become a subject of immense importance.³

The manifestations of head injury and its numerous other systemic complications are so compelling that damage to the visual system is most likely to be ignored. Mostly, when the eye is examined

as part of neurological assessment of a patient with head injury, the purpose is mainly to gauge the severity of the head injury itself³. With respect to soft – tissue injuries to the globe and adenexae in the anterior segment of the eye, one hypothesis suggested that energy is transferred to these structures from the sturdy frontal bones to the orbit and from the lateral orbital margin to contiguous facial structures during the impact following head injury⁴. Disorders of eye movement are thought to result from direct trauma to orbital contents, cranial nerves, and other brain areas⁵.

The aim of this study was to evaluate the pattern and clinical profile of ocular and visual complications

in patients hospitalized and managed for head injury at DHQ hospital, Rawalpindi.

MATERIAL AND METHODS

The study comprised a prospective analysis of 152 patients diagnosed as having head injury along with ocular manifestations by the Neurosurgery and Ophthalmology department on the basis of history, neurological and ophthalmological findings at the time of admission. They were hospitalized for varying periods between 1st January 2013 and 30th June 2013 at the DHQ hospital, Rawalpindi. We reviewed these patients and did follow ups for signs and symptoms of ocular morbidity which were present subsequently. Detailed anterior and posterior segment slit lamp examination was done. Extraocular movements, optic nerve function tests were checked. Diagnostic investigations carried out included computed tomography scanning and/or magnetic resonance imaging of brain and orbit, gonioscopy, diplopia charting, and measurement of intraocular pressure. According to requirement, we assessed the visual acuity (VA) using the Snellen's chart. Then we transferred the findings into a questionnaire format, which included patients' sociodemographic data, mode of head trauma, and findings on neurological and ophthalmic evaluations. Ocular and visual complications were grouped into three main classes of abnormalities of the visual system: soft-tissue injuries to the globe and adenexae, neuro-ophthalmic abnormalities, and injuries to the bony orbit and other skull bones. Ophthalmology and neurosurgery departments managed the patients according to their respective diagnoses and referred those who presented with multiple organ involvement to the appropriate specialties at the same hospital.

RESULTS

Ocular and visual complications occurred in 152 head-injured individuals managed during the period under consideration. They were 108 (71.0%) male and 44 (28.9%) female subjects. At presentation, the youngest and oldest patients were 6 years and 63 years old, respectively. Ophthalmic complications peaked at the second decade of life, and thereafter declined (Fig. 1). Patients encountered multiple ocular injuries involving both anterior and posterior segments of the eye.

The causes of head injury are itemized in table 1 and traffic accidents were the most common cause of

ocular disorder (56.6%), fall from height (25%) and assault (13.8%) accounted for head and ocular injuries, while gunshot injury to the head was responsible in 7 patients (4.6%). Of the traffic related accidents, passengers were most frequently affected (65.0%) than pedestrians (26.0%) and cyclists (9%), shown in Fig. 2.

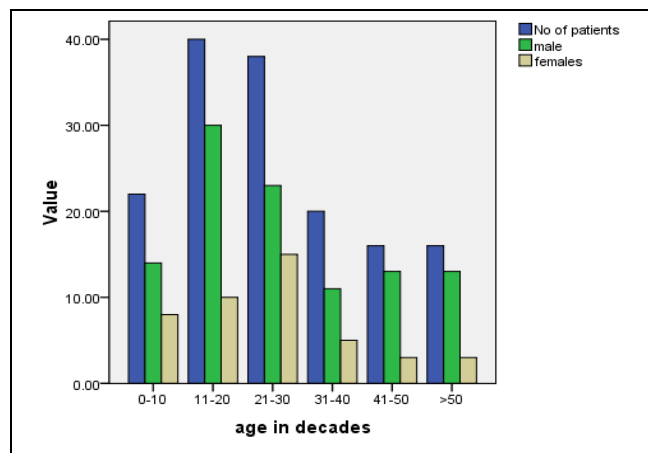


Fig. 1: Age and sex distribution in 152 patients manifesting ocular and visual complications of head injury.

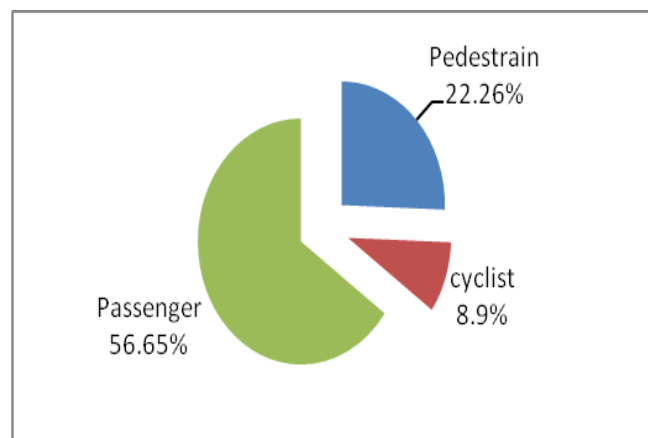


Fig. 2: People affected in traffic accidents.

Table 2 shows the ocular and visual complications of head injury observed in 152 cases. One very important case found was a patient who developed carotid cavernous fistula bilaterally shown in figures 3, 6 (features were more prominent on left side).

Other frequent complications included soft-tissue injuries to the globe and adenexae, neuro-ophthalmic abnormalities, and fracture of the orbit with rupture of

the globe. The most frequent soft - tissue injuries were periorbital ecchymosis (85 patients), sub-conjunctival haemorrhage (62 patients), lid oedema (52 patients), chemosis (16 patients), black eye (18), lid laceration (14 patients), corneoscleral laceration (06 patients) shown in figure 4, vitreous haemorrhage (05 patients).

The most frequently encountered neuro-ophthalmic manifestation was abducens nerve palsy. It occurred in 12 patients and was the most common ocular motor nerve palsy, followed by oculomotor 10 patients, trigeminal 4 patients, trochlear 4 patients and facial nerve palsy 2 patients. One patient developed aberrant regeneration of third nerve.

Another neuro-ophthalmic complication observed

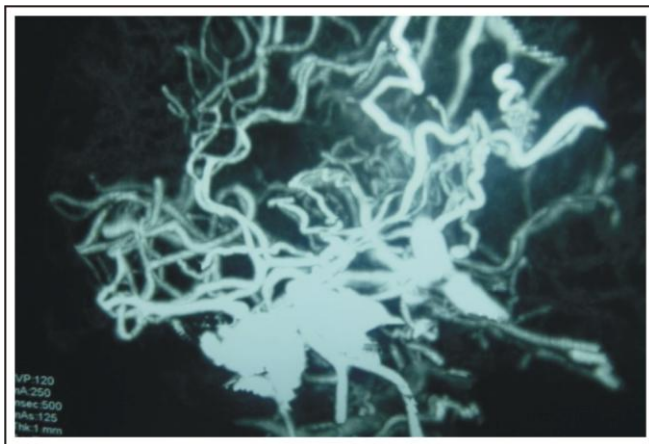


Fig. 3: CT angiography brain showing dilated cavernous sinuses due to carotid cavernous fistula.

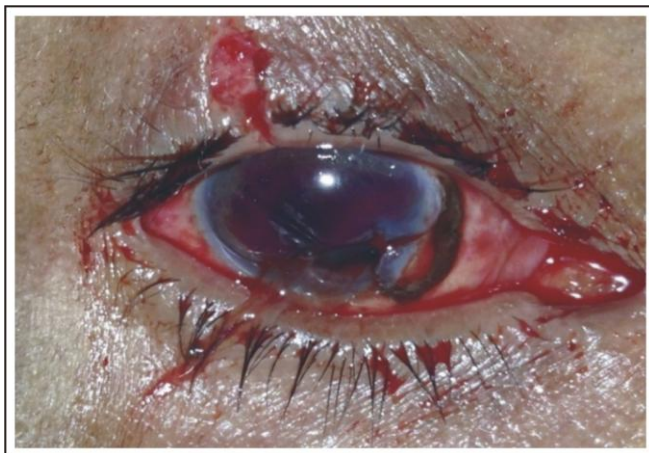

Fig. 4: Right eye corneo-scleral tear with uveal tissue prolapsed.

Table 1: Causes of head injury

Causes	Male	Female	No of Patients n (%)
Traffic accidents	58	28	86 (56.6)
Assault	16	5	21 (13.8)
Falls from height	30	8	38 (25.0)
Gunshot	4	3	7 (4.6)
Total	108	44	152 (100)

Table 2: Ocular complications of head injury

Injury Type	No. of Patients
A. Soft - tissue injury to the globe and adenexae	
Periorbital ecchymosis	85
Laceration of eyelids	14
Lid oedema	52
Corneoscleral laceration	06
Subconjunctival haemorrhage	62
• Unilateral	44
• Bilateral	18
Chemosis	16
Brow tear	02
Vitreous haemorrhage	05
Black eye	18
• Unilateral	08
• Bilateral	10
B. Orbital fracture with rupture globe	02
C. Neuro-ophthalmic complications	
Cranial nerve injury	
• Abducens	12
• Oculomotor	10
• Trochlear	04
• Trigeminal	04
• Facial	02
• Traumatic optic neuropathy	10
• Aberrant regeneration of third nerve	01
Papilloedema	10
Carotid cavernous fistula	01

was papilloedema in 10 patients which is not uncommon to be found in cases of head injury.

Table 3: CT Scan findings of head injured patients (bony and soft tissue injuries).

Fractures	Number
Frontal bone	20
Parietal bone	08
Occipital bone	04
Temporal bone	02
Basal skull	04
Haemorrhages	
Sub-dural haemorrhage	30
Sub-arachanoid haemorrhage	22
Extra-dural haemorrhage	16
Intra-cerebral bleed	10
Multiple brain contusions	16

According to CT-Scan findings (Table 3) the most commonly fractured bone was frontal bone (20) followed by parietal bone (08), occipital bone (04), basal skull fracture (04) and temporal bone fracture in (02) patients. Subdural haemorrhage occurred in (30) patients followed by sub-arachanoid (22), extra-dural (16) and intra-cerebral bleed in (10) patients. Multiple brain contusions occurred in (16) patients.

DISCUSSION

In our study we have assessed different ocular manifestations which we found in patients of head injury.

It is not surprising that traffic accidents were responsible for the greater proportion of head injuries associated with ocular manifestations. In many series worldwide, traffic accident constitutes the leading cause of head injury which is shown in study of Odebode et al,³ Kulkarni et al⁵, Masila et al⁶, Sabates et al⁷ and in our study again, it is the leading cause 56.6%. In our setting, motorized transportation has been on the rise in recent years and this is not without the attendant risk of increased auto accidents. This is worst in those parts of the World like ours, where traffic regulations and speed limits are not strictly observed and unlicensed careless driving is treated with levity.

The lids and conjunctiva in the anterior segment of the eye were more commonly involved in head injuries than the posterior segment, ocular cranial nerves, or the bony orbit. Injuries to this segment result from direct impact on the rigid frontal bones and orbital margins, producing periorbital echymosis, lid laceration, and subconjunctival haemorrhage, and chemosis³. Same is true for our study.

The eyes are often involved in head injury (directly and indirectly) with neuro-ophthalmic deficits^{7,8,9,10,11,12}. In our study, of the neuro-ophthalmic complications, traumatic ocular motor abnormality was the most frequent and among cranial nerve palsies the Abducens being the most commonly affected cranial nerve (41%) followed by oculomotor, trigeminal, trochlear and facial being least affected nerve. The incidence of Abducens nerve palsy in Odebode et al study, in severe head injuries has been reported as 27%³. The mechanism of its palsy, secondary to severe head injuries, has been attributed to avulsion or contusion of the nerve at the base of the posterior clinoid process, where it lies beneath the rigid petrosphenoid (Gruber's) ligament, medial to the sensory root of the fifth nerve at the apex of the temporal bone³.

Eye injuries remain the most common cause of monocular blindness, a life-long disability, and when the outcome is less serious than blindness extensive medical care, including surgery, hospitalization, and repeated treatments over long periods may be required. In spite of this, majority of the past reviews on this subject have focused on specific aspects of the visual anatomy, such as the ocular cranial nerves, optic nerves, or the posterior visual pathways^{13,14,15,16}, rather than a complete overview of the manner in which head injury affects the visual system. Our study has added to the latter list and has given credibility to a few previous findings.

As we have discussed previously that abducent nerve is the most commonly damaged cranial nerve, it is usually damaged when a basilar fracture crosses the petrous ridge and a clear relationship can usually be established with facial paralysis and deafness¹⁶. This makes the seventh and eighth cranial nerve damage a common association with head injuries associated with ocular manifestations as observed in this series. Abducens palsy could also derive from sufficient middle cranial fossa haemorrhage causing compression and pressure paralysis on one or both sides¹⁶.

Visual loss resulting from globe rupture and traumatic optic nerve damage associated with head injury in this series should be regarded as the most significant disability. In our study there were 10 cases of traumatic optic neuropathy. Trauma-induced injury to the optic nerve can occur anywhere along the nerve's intraorbital to intracranial length. Radiological investigations (CT scan/MRI) has confirmed the presence of dural haemorrhage, interstitial nerve haemorrhage, shearing lesions, as well as localized ischaemia and oedema, which are considered as secondary events to initiate neuropathy. According to Rush et al¹⁶, such injuries are ordinarily self-limiting with improvements occurring in 3 - 4 days. However, when they do persist, corticosteroid therapy or optic nerve decompression has been advocated¹⁷. Currently endoscopic optic nerve decompression by an intranasal or trans-ethmoidal or trans-sphenoid approach is gaining a popular support.

In our study, aberrant regeneration of third nerve was detected in a young male, 25 years of age, who had road traffic accident with resultant left frontal bone fracture with underlying extra-dural and sub-arachnoid haemorrhages, along with that he had 3rd, 5th (ophthalmic branch), 6th nerve palsies and papilloedema at time of admission, during regular follow up, at 3 month he was found to have signs similar to Adie's pupil i.e. light near - dissociation and vermiform movements (seen on slit lamp examination). Traumatic third nerve palsy may result in aberrant regeneration of the third cranial nerve. The full blown features of this syndrome may or may not be present¹⁸ and the same problem can occur after orbital trauma¹⁹.

Another important case in our study was traumatic carotid cavernous fistula, who was a 65 year old female patient and had history of fall from roof with resultant occipital epidural hematoma and basal skull fracture. She was managed conservatively after admission and was discharged after 3 days of admission. 5 months after injury she presented via eye OPD with pain left eye. On examination she had bilateral episcleral congestion (L > R) left corneal oedema, fixed dilated pupil, intraocular pressure at eye 18 mm Hg, Lt eye 70 mm Hg, left fundal view was hazy showing disc hyperemia. Features of pupil involving left 3rd nerve palsy were also there. Initially raised IOP was managed with topical, oral and intravenous anti-glaucoma therapies and with full conservative management, intraocular pressure was reduced to 32 mm Hg in left eye. Our provisional

diagnosis was carotid cavernous fistula which was confirmed on CT angiography and so patient was referred to neurosurgery department DHQ Rawalpindi for further management. A relatively high incidence of Traumatic carotid cavernous fistula was been reported in patients with basal skull fracture (mainly middle cranial fossa)²⁰. Prompt diagnosis and early intervention may significantly improve the patient outcome²⁰.

As far as skull fractures are concerned, frontal bone fracture was most common in our study (51%) which is comparable with Rupani et al²¹ study (56.7%) where again it was most common. Among intracranial bleeds, subdural haemorrhage was most of all (30.1%) noted in Perel et al²² study and same is true for our study where it is 38.1%.

CONCLUSION

Injury to the globe, adenexae and ocular cranial nerve palsies constitute the most common oculo-visual complications associated with head injury, so every patient with head injury should also be examined for eye signs along with routine management for head injury and this should be practiced not only on first presentation but also on follow up visits.

Author's Affiliation

Dr. Kanwal Zareen Abbasi
Senior Registrar
Ophthalmology Department
Benazir Bhutto Hospital
Rawalpindi

Dr. Baseerat Qadeer
Postgraduate Trainee
Ophthalmology Department
Benazir Bhutto Hospital
Rawalpindi

Professor Dr. Ali Raza
Head of Ophthalmology department,
Rawalpindi Medical College and Allied Hospitals
Rawalpindi

Role of Authors:

Dr. Kanwal Zareen Abbasi
Data collection, Review of literature, Paper writing

Dr. Baseerat Qadeer
Data collection

Professor Dr. Ali Raza
Manuscript review

REFERENCES

1. **Van Stavern GP, Biousse V, Lynn MJ, Simon DJ, Newman NJ.** Neuro-Ophthalmic manifestations of head trauma. *J Neuro-Ophthalmol.* 2001; 21: 112-7.
2. **Baker RS, Epstein AD.** Ocular motor abnormalities from head trauma. *Survey Ophthalmol.* 1991; 35: 245-67.
3. **Odebode TO, Ademola-Popoola DS, Ojo TS, Ayanniyi AA.** Ocular and visual complications of head injury. *Eye* 2005; 19: 561-6.
4. **Duke Elder S, Wybar KC.** The Anatomy of the Visual System. *Eye and Sport Medicine.* 1961; 2: 559-67.
5. **Kulkarni AR, Aggarwal Sp, Kulkarni RR, Deshpande D, Walimbe PB, Labhsewar AS.** Ocular manifestation of head injury: a clinical study. *Eye* 2005; 19: 1257-63.
6. **Masila F, Kiboi J, Marco S, Njuguna M.** Ocular findings in patients with head Injury. *Journal of Ophthalmology of Eastern, Central and Southern Africa.* 2014; 18.
7. **Sabates N, Gonc M, Farris B.** Neuroophthalmological findings in closed head trauma. *J Clin Neuro-ophthalmol.* 1991; 11: 273-7.
8. **Kowal L.** Ophthalmic manifestations of head injury. *Austra New Zealand J Ophthalmol.* 1992; 20: 35-40.
9. **Lepore F.** Disorders of ocular motility following head trauma. *Arch Neurol.* 1995; 52: 924-6.
10. **Mariak Z, Mariak Z, Stankiewie A.** Cranial Nerve II – VII injuries in fatal closed head trauma. *Eur J Ophthalmol.* 1997; 7: 68-72.
11. **Moster ML, Volpe NJ, Kresloff MS.** Neuroophthalmic findings in head injury. *Neurol.* 1999; 52: 2-23.
12. **Baker RS, Epstein AD.** Ocular motor abnormalities from head trauma. *Surv Ophthalmol.* 1994; 35: 245-67.
13. **Cohen M, Groswasser Z, Barchadski R, Appel A.** Convergence insufficiency in brain – injured patients. *Brain Injury.* 1989; 3: 187-91.
14. **Ramsay JH.** Optic nerve injury in the fracture of the canal. *Br J Ophthalmol.* 1979; 63: 607-10.
15. **Shifrin, Louise Z MD.** Bilateral Abducens Nerve Palsy after cervical spine extension injury: A case report. *Spine, March* 1991; 16: 374-5.
16. **Rush JA, Younge BR.** Paralysis of cranial nerves III, IV and VI. Cause and prognosis in 1,000 cases. *Arch Ophthalmol.* 1981; 99: 76-9.
17. **Waga S, Kubo Y, Sakakura M.** Transfrontal intradural microsurgical decompression for traumatic optic nerve injury. *Acta Neurochir.* 1998; 91: 42-46.
18. **Sayed SA, Rabea M.** Aberrant regeneration of the third cranial nerve. *Journal of The Egyptian Ophthalmology Society.* 2013; 106: 150-2.
19. **Sebag J, Sadun AA.** Aberrant regeneration of third cranial nerve following orbital trauma, *Arch Neurol.* 1983; 40: 762-4.
20. **Liang W, Xiaofeng Y, Weiguo L.** Traumatic carotid cavernous fistula accompanying basal skull fracture. *J Trauma.* 2007; 63: 1014-20.
21. **Rupani R, Verma A, Rathore S.** Patterns of skull fractures in cases of head Injury by blunt force. *Acad Forensic Med.* 2013; 35.
22. **Perel P, Roberts I, Bouamra O, Woodford M, Mooney J, Lecky F.** Intracranial bleeding in patients with traumatic brain injury: A prognostic study. *BMC Emergency Medicine.* 2009; 9.