

Comparison of Safety and Efficacy of Intravitreal Ziv-Aflibercept Vs Bevacizumab for the Treatment of Macular Edema

Hussain Ahmad Khaqan¹, Usman Imtiaz², Hasnain Muhammad Buksh³
Hafiz Ateeq-ur-Rehman⁴, Raheela Naz⁵

¹⁻⁵Ameer-ud-Din Medical College PGMI, Lahore General Hospital, Lahore – Pakistan

ABSTRACT

Purpose: To study the safety and efficacy of intravitreal Ziv-Aflibercept vs. Bevacizumab for the management of edema caused by different retinal pathologies.

Study Design: Comparative interventional study.

Place and Duration of Study: Department of Ophthalmology, Unit II, Lahore General Hospital, Lahore, from July 2018 to June 2019.

Material and Methods: All patients with resistant, center involving macular edema due to diabetes, retinal vein occlusion and age related macular degeneration were recruited in this study. Complete baseline ocular examination was performed at presentation. All the patients were randomly grouped into two i.e. IVZ (intravitreal Ziv-Aflibercept) and IVB (intravitreal bevacizumab). Each eye underwent intravitreal injection of 0.05 ml of fresh filtered ziv-aflibercept (1.25 mg) or 0.05 ml of fresh filtered Bevacizumab. Outcome was measured in terms of variation in central macular thickness (CMT) and also best corrected visual acuity (BCVA) at 3 months.

Results: Total of 156 eyes of 136 patients completed whole duration of study and were included in the results. The mean baseline CMT was 510 μm ($\pm 94 \mu\text{m}$) in the IVB group and 493 μm ($\pm 102 \mu\text{m}$) in the IVZ group ($P = 0.94$). The mean baseline BCVA (log MAR) was 0.78 (Snellen's equivalent 6/36) in the IVZ and 0.70 (Snellen's equivalent 6/30) in the IVB group ($P = 0.78$). Central macular thickness was significantly reduced at 1st, 2nd and 3rd month in the IVZ group and IVB group ($P < 0.001$).

Conclusion: Intravitreal Ziv-Aflibercept is safe and more effective than Bevacizumab for the treatment of edema caused by diabetes mellitus, retinal vein occlusion and wet age related macular degeneration.

Key Words: Aflibercept, Ziv-Aflibercept, Bevacizumab, Diabetic Retinopathy, Wet Age related Macular degeneration, Retinal vein occlusion.

How to Cite this Article: Khaqan HA, Imtiaz U, Buksh HM, R HAU, Naz R. Intravitreal Ziv-Aflibercept Vs Bevacizumab for the Treatment of Macular Edema. Pak J Ophthalmol. 2020;**36** (3): 205-210.

Doi: 10.36351/pjo.v36i3.1014

INTRODUCTION

Anti-vascular endothelial growth factor (VEGF) drugs

Correspondence to: Hussain Ahmad Khaqan
Ameer-ud-Din Medical College, Lahore – Pakistan
Email: drkhaqan@hotmail.com

Received: March 10, 2020

Revised: May 4, 2020

Accepted: June 16, 2020

related macular degeneration (AMD), macular edema secondary to diabetes and retinal vein occlusions¹. have become the standard of care for several chorioretinal vascular conditions including wet age Second most common retinal vascular condition i.e. macular edema secondary to retinal vein occlusion results in considerable decrease in best corrected visual acuity (BCVA)². VEGF mediates the development of neovascularization in retinal vein

occlusion which results in severe irreversible vision loss.

The WESDR (Wisconsin Epidemiologic Study of Diabetic Retinopathy) found that there are 26% chances of developing DME after 14 years in type I diabetes, whereas Diabetes Control and Complication Trial (DCCT) reported that 27% of type I diabetics develop DME after 9 years⁴. Type II diabetes in older patients is associated with higher incidence of macular edema⁵. Retinal Ischemia promotes VEGF production, which in turns mediates the development of neovascularization in diabetic retinopathy and may lead to severe irreversible vision loss.

The basic problem in wet age related macular degeneration (AMD) leading to 1.6% of blindness of American population is abnormal neovascularization and vascular permeability. Positive regulators like vascular endothelial growth factor A (VEGF-A), transforming growth factor α and β (TGF α and β), fibroblast growth factor, hepatocyte growth factor, connective tissue growth factor and interleukins; and negative regulators: pigment epithelium-derived factor (PEDF), thrombostatin, angiostatin and endostatins play an important role in angiogenesis⁶. Intraocular VEGF is reduced by the anti-VEGF agents administered in the eyes of patients, which reduces the vascular permeability and stops vascular leakage⁷.

Ranibizumab was the first approved anti-VEGF agent that revolutionized DME treatment⁸. Recently, newer anti-VEGF (vascular endothelial growth factor) drug, aflibercept (Eyelea®, Bayer Healthcare, Germany), approved by Food and Drug Administration (FDA), has shown good treatment outcomes in patients with macular edema secondary to CRVO⁷. Eylea (Aflibercept) is approved therapy for macular edema caused by Age related macular degeneration, diabetes and retinal vein occlusion⁸.

Ziv-aflibercept (Zaltrap; Regeneron, New York, USA) is pharmacologically similar to aflibercept, and the mechanism of action is also similar to Aflibercept i.e. it acts on all VEGF subtypes as well as placental growth factor. It is approved by FDA for the treatment of colon cancer, and is available at pharmacies much cheaper than aflibercept particularly for ocular use⁹. Toxicity to RPE (retinal pigment epithelial cells) has never been studied in previous studies by using approved cancer protein, ziv-aflibercept¹⁰.

The aim of our study was to compare the efficacy and safety of intravitreal ziv-aflibercept with that of

Bevacizumab for the treatment of edema caused by diabetes mellitus, RVO and wet AMD.

MATERIAL AND METHODS

A prospective, comparative interventional study was conducted in the Ophthalmology department, Unit II of Lahore General Hospital, Lahore from July 2018 to June 2019. Institutional Review Board approval was obtained and study followed tennets of declaration of Helsinki. Informed consent was obtained from the patients. All patients with resistant, center involving macular edema due to diabetes; retinal vein occlusion and wet age related macular degeneration were recruited in this study. Patients with only eye, uncontrolled diabetes, uncontrolled hypertension, advanced cataract, uncontrolled glaucoma, epiretinal membrane (ERM) or vitreo macular traction and prior intervention with laser and intravitreal injection were excluded from the study.

Complete baseline ocular examination was performed at presentation including best corrected visual acuity (BCVA), anterior segment examination, posterior segment examination and indirect ophthalmoscopy, intra-ocular pressure assessment, OCT and FFA (optical coherence tomogram and fundus fluorescein angiography respectively). BCVA was performed using Snellen's visual acuity chart and also using Log MAR scale. The OCT was performed using Cirrus 5000 (Zeiss, Dublin, CA). Thickness of central retina was measured in a 3 mm circle centered on point of fixation. Central 1 mm zone was taken as central macular thickness (CMT).

All the patients that fulfilled the inclusion and exclusion criteria were assigned to one of the two different treatment groups randomly: 1.25 mg (0.05 ml) of Ziv-aflibercept (ZALTRAP; Regeneron Pharmaceuticals Inc) (IVZ group) and 1.25 mg (0.05 ml) of Bevacizumab (Avastin; Genentech Inc, South San Francisco, CA) (IVB group). Randomization was performed using random number table. Participants and the investigators were masked of the study groups. Surgeons other than the study investigators performed all the interventions.

After taking aseptic measures, each eye received intravitreal injection of 0.05 ml of filtered ziv-aflibercept (1.25 mg) or 0.05 ml of fresh filtered Bevacizumab in the operation theater. 30-gauge tuberculin syringes were used to deliver the injection under topical anesthesia. All eyes underwent slit-lamp

examination at 1st and 7th post-operative day to look for any intra-ocular inflammation and raised intra-ocular pressure. Minimum of three doses were given to all the participants at 4 weekly intervals. BCVA, slit lamp assessment and Optical Coherence Tomography were performed again at 1st, 2nd, 3rd and 6th months.

Measurement of change in CMT (central macular thickness) and BCVA (best corrected visual acuity) at 3rd month was the primary outcome. Secondary outcome measures were change in BCVA and CMT at 1st, 2nd and 6th month. Any potential eye related and systemic complications related to the intervention were assessed at each follow-up visit.

RESULTS

Primarily 162 eyes of 141 patients satisfied our inclusion and exclusion criteria. Of this 5 patients (7 eyes) were lost to follow-up. So total of 156 eyes of 136 patients completed whole duration of study and were included in the results. IVZ group included 70 patients (81 eyes) and IVB group had 66 patients (75 eyes). Twenty patients had bilateral injections.

Table 1 shows demographic data. Two groups carry no difference regarding demographic and baseline features. The mean baseline central macular thickness was 510 μm (± 94 μm) in the intravitreal bevacizumab group and 493 μm (±102 μm) in the intravitreal ziv-aflibercept group (P = 0.94). The mean baseline BCVA (logMAR) was 0.78 (Snellen's equivalent 6/36) in the IVZ and 0.70 (Snellen's

equivalent 6/30) in the IVB group (P = 0.78).

There was significant improvement in the best corrected visual acuity (BCVA) after every 1 month interval in both groups (P < 0.001). At 3rd month best corrected visual acuity difference was significant among the groups. Intravitreal ziv-aflibercept group showed significant changes in the best corrected visual acuity (BCVA) as compared to intravitreal bevacizumab group (Table 2 and Fig 1).

Table 2: Comparison of Visual acuity at 1st, 2nd and 3rd month.

	Total	Groups	
		IVZ	IVB
Baseline	0.74 ± 0.21	0.78 ± 0.22	0.70 ± 0.21
4 Weeks	0.61 ± 0.20	0.60 ± 0.21	0.62 ± 0.19
Change	0.13 ± 0.21	0.18 ± 0.20	0.08 ± 0.20
8 Weeks	0.52 ± 0.16	0.48 ± 0.17	0.56 ± 0.15
Change	0.22 ± 0.19	0.30 ± 0.19	0.14 ± 0.18
12 Weeks	0.45 ± 0.12	0.42 ± 0.13	0.48 ± 0.11
Change	0.29 ± 0.16	0.36 ± 0.16	0.22 ± 0.16

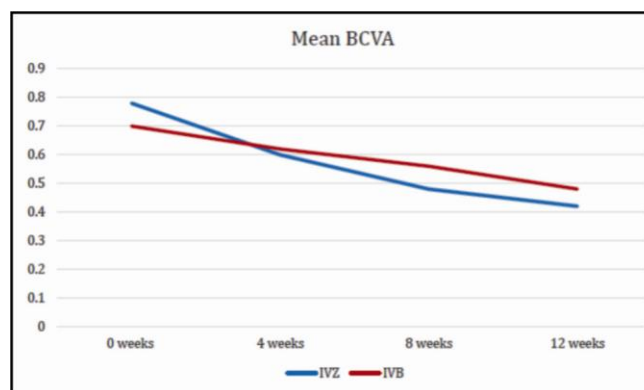


Fig. 1: Graph showing BCVA during the course of study.

Table 1: Demographic data of the two groups.

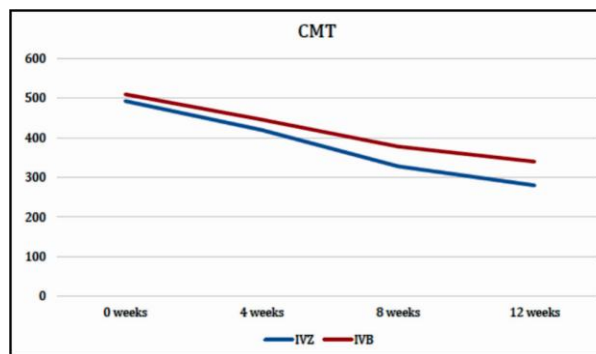
	Total	Groups	
		IVZ	IVB
No. of Eyes	156	81	75
No. of Subjects	136	70	66
Age (Years)	59.5 ± 3	60 ± 2	59 ± 4
Mean SD			
Sex			
Male	75	41	34
Female	61	29	32
Eye			
Right	90	51	39
Left	66	30	36
Lens Status			
Phakic	107	66	41
Pseudophakic	49	23	26
Baseline BCVA (Log MAR)	0.7 ± 0.21	0.78 ± 0.22	0.70 ± 0.21
Mean ± SD			
Baseline CMT	501.5μm ±	493μm ±	510μm ±
Mean ± SD	98μm	102μm	94μm

In comparison to the baseline values, central macular thickness decreased significantly at 1st, 2nd, and 3rd month in the IVZ group and IVB group (P < 0.001). Overall, in all visits, CMT was much reduced in the IVZ group in comparison to the IVB group (Table 3 and Fig. 2). At 24 weeks follow-up, BCVA and CMT were significantly improved in both treatment arms (P < 0.001). BCVA changes were significantly better in the IVZ group as compared to the IVB group.

In our study, in IVZ group, 3 eyes experienced sterile intraocular inflammation while 2 eyes showed significant progression of cataract.

Table 3: Comparison of CMT between two groups at 1st, 2nd and 3rd month.

	Total	Groups	
		IVZ	IVB
Baseline	501.5 $\mu\text{m} \pm 98 \mu\text{m}$	493 $\mu\text{m} \pm 102 \mu\text{m}$	501.5 $\mu\text{m} \pm 94 \mu\text{m}$
4 Weeks	433 $\mu\text{m} \pm 90 \mu\text{m}$	420 $\mu\text{m} \pm 94 \mu\text{m}$	446 $\mu\text{m} \pm 86 \mu\text{m}$
Change	68.5 ± 94	73 ± 87	64 ± 90
8 Weeks	387 $\mu\text{m} \pm 77 \mu\text{m}$	328 $\mu\text{m} \pm 66 \mu\text{m}$	378 $\mu\text{m} \pm 76 \mu\text{m}$
Change	114.5 ± 86	213 ± 78	132 ± 86
12 Weeks	310 $\mu\text{m} \pm 68 \mu\text{m}$	280 $\mu\text{m} \pm 66 \mu\text{m}$	340 $\mu\text{m} \pm 70 \mu\text{m}$
Change	191.5 ± 78	213 ± 78	170 ± 82

**Fig. 2:** Graphs showing central macular thickness (CMT) changes during the study.

DISCUSSION

Limited data is available which compares the safety profiles and efficacy of ziv- aflibercept anti-vascular endothelial growth factor (VEGF) drug with other commonly used agents. Oliveira Dias et al stated that there were no changes in ERG in patients with AMD who received intravitreal ziv-aflibercept showing no toxicity to retinal tissue and there was visual and OCT improvements seen in the patients. Intra ocular inflammation was observed in one of the eyes and the inflammation resolved after taking appropriate therapy¹¹. De Andrade G et al conducted a study in which they injected intravitreal ziv-aflibercept in seven patients with macular edema due to diabetes. They studied the safety and efficacy of ziv-aflibercept over 48 weeks period and concluded that the drug was safe and effective¹².

Another study conducted by Singh et al constituted the largest pooled safety report on IVZ use and included patients from 14 centres distributed across the globe. It showed that IVZ had an acceptable ocular and systemic safety profile with incidence of adverse events similar to those of other vascular endothelial growth factor inhibitory drugs. The analysis supported the continued use of IVZ in various retinal disorders¹³.

Papadopoulos et al compared two different doses of Ziv-aflibercept with other anti VEGF in treating wet Age related macular degeneration. They followed the patients for 16-weeks and concluded that both doses of Ziv-aflibercept were superior to Bevacizumab in terms of final BCVA and CMT¹⁴.

Baghi et al compared two different doses of Zaltrap with Avastin for the management of macular edema due to diabetes. They followed the patients for

12-weeks and concluded that both doses of ziv-aflibercept were superior to Bevacizumab in terms of final BCVA and CMT¹⁵.

In one study of intravitreal injections of ziv aflibercept for DME, a prospective single-treatment clinical trial, demonstrated that ziv-aflibercept monotherapy was linked with substantial improvement in mean BCVA and CMT in a 24-week follow-up. There was also no ERG evidence of retinal toxic reactions after intravitreal ziv-aflibercept injections in eyes with DME¹⁶.

Cost is a major factor when it comes to selecting anti-VEGF for the treatment of macular edema. Most of these patients require monthly injections and this can add up to a huge amount of money. Compounded intravitreal Bevacizumab and Ziv-aflibercept costs around USD 50 per dose, which is 15-20 times less than the cost of Ranibizumab or Aflibercept¹⁷.

One study showed that use of Aflibercept instead of Bevacizumab has lead to overspending of about €335 million in one year in europe¹⁸. So Ziv-aflibercept can prove to be a very valuable agent for the treatment of macular edema especially in under-developed and developing countries where insurance covering is scarce. One of the major concerns for compounded intravitreal injections is the risk of endophthalmitis¹⁹.

Both aflibercept and ziv-aflibercept are structurally similar containing the same fusion protein, but there are few differences like in the osmolarity. 300 mOsm/kg is the osmolarity of aflibercept which is iso-osmotic solution and 1000 mOsm/kg is the osmolarity of ziv-aflibercept which is more concentrated. In addition, the 0.05ml of ziv-aflibercept contains 1.25 mg whereas aflibercept contains 2.0 mg.

In our study we demonstrated intermediate term outcomes, which were in favour of ziv-aflibercept. At all follow-ups, BCVA was significantly better in patients who received ziv-aflibercept as compared to those who received Bevacizumab. Similarly, better CMT reduction was achieved in ziv-aflibercept group than in Bevacizumab group.

Ziv-aflibercept shares the same molecular structure as aflibercept. However, the manufacturing process of aflibercept involves more robust purification and use of buffers to reduce the ocular irritation and toxicity²⁰. In our study 3 eyes (3.7%) demonstrated sterile intraocular inflammation in ziv-aflibercept group. This is significant and difference in manufacturing process of ziv-aflibercept may explain this incidence. All of the three patients were managed medically and none of them had reduction in final BCVA as compared to than baseline. Ziv-aflibercept is prepared in laboratory with slightly hypertonic sucrose, which damages the lens and retina, it causes mild mitochondrial toxicity in human RPE cells⁸. In our study however, we did not experience any case of retinal toxicity but in 2 eyes (2.5%) there was significant cataract progression.

Limitations of our study include small sample size and relatively shorter follow-up period. Long term outcomes and complications need to be addressed by having a larger patient pool and longer duration of follow-ups.

CONCLUSION

Intravitreal ziv-aflibercept is more effective than Bevacizumab for the treatment of diabetic macular edema. However, complications like sterile intraocular inflammation and cataract progression caused by intravitreal ziv-aflibercept needs to be investigated in detail.

Acknowledgement

This study was funded by the OSP research fund.

Ethical Approval

The study was approved by the Institutional review board/Ethical review board.

Conflict of Interest

Authors declared no conflict of interest

Authors' Designation and Contribution

Hussain Ahmad Khaqan; Associate Professor: *Study conception, Study Design, Manuscript Revision.*

Usman Imtiaz; Vitreoretinal Fellow: *Manuscript writing, Data Analysis, Critical Revision.*

Hasnain Muhammad Buksh; Vitreoretinal Fellow: *Manuscript writing, Literature Review, Study Design.*

Hafiz Ateeq-ur-Rehman; Post Graduate Resident: *Data collection, Data Analysis, Proofreading.*

Raheela Naz; Post Graduate Resident: *Data collection, Literature Review, Proofreading.*

REFERENCES

1. **Chhablani J.** Intravitreal ziv-aflibercept for recurrent macular edema secondary to central retinal venous occlusion. *Indian J Ophthalmol.* 2015; **1**; **63** (5): 469.
2. **Paulose R, Chhablani J, Dedhia CJ, Stewart MW, Mansour AM.** Intravitreal ziv-aflibercept for macular edema following retinal vein occlusion. *Clin Ophthalmol.* (Auckland, NZ). 2016; **10**: 1853.
3. **Klein R, Klein BE, Moss SE, Cruickshanks KJ.** The Wisconsin Epidemiologic Study of Diabetic Retinopathy: XVII: The 14-year incidence and progression of diabetic retinopathy and associated risk factors in type 1 diabetes. *Ophthalmology*, 1998; **105**: 1801–15.
4. Diabetes Control and Complications Trial Research Group. Progression of retinopathy with intensive versus conventional treatment in the Diabetes Control and Complications Trial. *Ophthalmology*, 1995; **102**: 647–61.
5. **Bhagat N, Grigorian RA, Tutela A, Zarbin MA.** Diabetic macular edema: Pathogenesis and treatment. *Surv Ophthalmol.* 2009; **54**: 1–32.
6. **Derveniz N, Mikropoulou AM, Tranos P, Derveniz P.** Ranibizumab in the Treatment of Diabetic Macular Edema: A Review of the Current Status, Unmet Needs, and Emerging Challenges. *AdvTher.* 2017; **34** (6): 1270-1282. Doi: 10.1007/s12325-017-0548-1.
7. **De Oliveira Dias JR, de Andrade GC, Novais EA, Farah ME, Rodrigues EB.** Fusion proteins for treatment of retinal diseases: aflibercept, ziv-aflibercept, and conbercept. *Int J Retin Vitreol.* 2016; **2** (1): 3.
8. **Malik D, Tarek M, del Carpio JC, Ramirez C, Boyer D, Kenney MC, et al.** Safety profiles of anti-VEGF drugs: bevacizumab, ranibizumab, aflibercept and ziv-aflibercept on human retinal pigment epithelium cells in culture. *Br J Ophthalmol.* 2014; **98** (Suppl 1): i11-6..

9. **Chhablani J, Narayanan R, Mathai A, Yogi R, Stewart M.** Short-term safety profile of intravitreal ziv-aflibercept. *Retina*. 2016 Jun 1; **36 (6)**: 1126-31.
10. **Mansour AM, Al-Ghadban SI, Yunis MH, et al.** Ziv-aflibercept in macular disease *Br J Ophthalmol*. 2015; **99**: 1055-1059.
11. **de Oliveira Dias JR, de Andrade GC, Kniggenndorf VF, Novais EA, Takahashi VK, Maia A, et al.** Intravitreal ziv-aflibercept for neovascular age-related macular degeneration: 52-week results. *Retina*. 2019 Apr 1; **39 (4)**: 648-55.
12. **Andrade G, de Oliveira Dias J, Maia A, Farah M, Meyer C, Rodrigues E.** Intravitreal Ziv-Aflibercept for Diabetic Macular Edema: 48-Week Outcomes. *Ophthalmic Surg Lasers Imaging Retina*, 2018; **49**: 245-250. Doi: 10.3928/23258160-20180329-06.
13. **Singh SR, Stewart MW, Chattannavar G, Ashraf M, Souka A, EIDardeery M, et al.** Safety of 5914 intravitreal ziv-aflibercept injections. *Br J Ophthalmol*. 2019; **103 (6)**: 805-10.
14. **Papadopoulos Z.** Aflibercept: A review of its effect on the treatment of exudative age-related macular degeneration. *Eur J Ophthalmol*. 2019 Jul; **29 (4)**: 368-78.
15. **Baghi A, Bonyadi MHJ, Ramezani A, Azarmina M, Moradian S, Dehghan MH, et al.** Two Doses of Intravitreal Ziv-Aflibercept versus Bevacizumab in Treatment of Diabetic Macular Edema: A Three-Armed, Double-Blind Randomized Trial. *Ophthalmol Retin*. 2017; **1 (2)**: 103–10.
16. **Andrade GC, Dias JR, Maia A, Farah ME, Meyer CH, Rodrigues EB.** Intravitreal injections of ziv-aflibercept for diabetic macular edema. *Retina*, 2016; **36 (9)**: 1640-5.
17. **Ross EL, Hutton DW, Stein JD, Bressler NM, Jampol LM, Glassman AR, et al.** Cost-effectiveness of Aflibercept, Bevacizumab, and Ranibizumab for Diabetic Macular Edema Treatment: Analysis From the Diabetic Retinopathy Clinical Research Network Comparative Effectiveness Trial. *JAMA Ophthalmol*. 2016; **134 (8)**: 888–896. Doi: 10.1001/jamaophthalmol.2016.1669.
18. **Asten VF, Michels CTJ, Hoyng CB, van der Wilt GJ, Klevering BJ, Rovers MM, et al.** The cost-effectiveness of bevacizumab, ranibizumab and aflibercept for the treatment of age-related macular degeneration-A cost-effectiveness analysis from a societal perspective. *PLoS One*. 2018; **13 (5)**: e0197670.
19. **Schwartz SG, Flynn HW Jr.** Endophthalmitis Associated with Intravitreal Anti-Vascular Endothelial Growth Factor Injections. *Curr Ophthalmol Rep*. 2014; **2 (1)**: 1–5. Doi: 10.1007/s40135-013-0033-1.
20. **Trichonas G, Kaiser PK.** Aflibercept for the treatment of age-related macular degeneration. *Ophthalmol Ther*. 2013; **2 (2)**: 89–98. Doi: 10.1007/s40123-013-0015-2.

